

CASE REPORT

Nasopalatine duct cyst developed in association with dental implant treatment: A case report and histopathological observation

Kenji Takeshita^{1,2}, Katsuyuki Funaki¹, Ryo Jimbo³, Tetsu Takahashi⁴

¹Private Practice, Tokyo, ²Division of Oral and Maxillofacial Reconstructive Surgery, Kyushu Dental College, Kitakyushu, ³Departments of Prosthodontics, Faculty of Odontology, Malmö University, Malmö, Sweden, ⁴Oral Medicine and Surgery, Division of Oral and Maxillofacial Surgery, Tohoku University Graduate School of Dentistry, Japan

Address for correspondence:

Dr. Ryo Jimbo,
Department of Prosthodontics, Faculty of
Odontology, Malmö University,
205 06 Malmö, Sweden.
E-mail: ryo.jimbo@mah.se

ABSTRACT

Placement of an anterior maxillary implant has a risk of interfering with the nasopalatine canal in the maxilla. This case report presents one of our experiences of a nasopalatine duct cyst that developed in association with a dental implant treatment. A 45-year-old man received an implant in the maxillary left central incisor due to root fracture. Preoperative radiograph indicated no anatomical abnormalities. A postextraction immediate implant was placed, and radiographic examination after 28 months revealed an asymptomatic, oval-shaped radiolucency around the apex of the implant, seemingly in contact to the nasopalatine canal. The entire lesion was removed along with a part of the implant. Histopathologically it was diagnosed as nasopalatine duct cyst. Accidental contact with the nasopalatine canal during surgery may have induced development of the nasopalatine duct cyst. Careful planning based on preoperative computed tomography scan may prevent such complications.

Key words: Cone beam CT, dental implant, histopathological analysis, nasopalatine duct cyst

INTRODUCTION

Dental implant placement in the anterior maxilla is subjected to various restrictions in its depth and angulation due to the potential resorption of the labial bone after extraction; the anatomy such as the nasopalatine canal and nasal cavity and the patient's esthetic expectations. In clinical practice, it is not unusual that a maxillary implant interferes with or penetrates into a nasopalatine canal. Although this is not crucial as compared to the mandibular nerve because sensation in the anterior third of the palatine mucosa is recovered within 2-3 months,^[1] it has been known that this may jeopardize the surgical osteotomy preparation.^[2,3] However, there exist only a few reports on postoperative complications caused by the interference of a maxillary implant with the nasopalatine canal.^[4-7] One of the major complications believed to be the result of the nasopalatine canal disturbance is the nasopalatine

duct cyst.^[8] In this case report, nasopalatine duct cyst, which was considered to have developed in association with the implant placed in the maxillary central incisor position is presented along with surgical recovery and histopathological evaluation.

CASE REPORT

A 45-year-old male patient visited our clinic in May 2005 due to detachment of a porcelain-fused-to-metal crown on the left maxillary central incisor, which had been connected at another clinic in 2000.

There were no special findings in his physical and extraoral conditions. On intraoral examination, mesiodistal fracture lines were found on the remaining tooth structure. A swelling and slight redness were observed on the peripheral soft tissue, but there were no acute symptoms such as purulence or pain [Figure 1a and b].

Radiographic examination showed no inflammatory symptoms, such as an increased periapical space, bone resorption, or periapical radiolucency, thus, the inflammation was judged confined almost exclusively in the gingival tissue. A nasopalatine foramen was found adjacent to the apex of the maxillary left central incisor [Figure 1c].

Access this article online**Quick Response Code:****Website:**

www.jomfp.in

DOI:

10.4103/0973-029X.119761

The maxillary left central incisor had a root fracture and required extraction. After a careful consultation about various treatment options, the patient desired implant treatment. Because there existed no obvious signs of acute inflammation or any other symptoms of the soft and hard tissue, postextraction immediate implant placement was planned. Prior to the implant treatment, the patient was subjected to meticulous scaling of all the remaining teeth and oral hygiene instruction session.

In May 2005, the maxillary left central incisor was extracted. After careful curettage of the extraction site, the mucoperiosteal flap was reflected. There was no resorption of the labial bone and an implant (TiOblast, Astra Tech, Mölndal, Sweden, ϕ 4.5 mm, length 13 mm) was placed into the fresh extraction socket with good primary stability. The osteotomy was made so that the implants would be located centrally in relation to the socket; however, careful drilling was conducted in order to preserve the buccal wall. The gap between the fixture and the socket wall was filled with autogenous bone particles collected during the surgery. The wound was closed after a releasing incision. On the periapical radiograph taken immediately after implant surgery, the implant appeared to interfere with the nasopalatine canal [Figure 2].

Cyst development and its treatment

The implant was restored with the definitive crown in November 2005. No abnormality was found during quarterly maintenance visits after the implant surgery, however, at the maintenance visit in November 2007, the patient complained about swelling on the palate. Clinical examination detected pulsation on the palate and an oval-shaped radiolucency having unclear boundary around the apex of the dental implant detected on the periapical radiograph. A computed tomography (CT) scan confirmed the radiolucency of a size of

10 mm \times 10 mm \times 9 mm, which surrounded the apical portion of the implant, reaching to the nasopalatine canal [Figure 3a-c]. Although the patient had no spontaneous pain, the lesion seemed to be enlarging and it was judged that early removal of the cyst was necessary. Because the implant was immobile, with no signs of peri-implant bone resorption, it was decided not to remove the entire implant but to resect the apical portion of the implant lodged inside the cyst, and remove the entire lesion. The surgery was performed in November 2007. Flap incision was designed to be away from the expected lesion area so that the incision will not overlap with the bone defect after the cyst removal. Mucogingival flap was elevated and resorption of the labial bone was observed. After removing the thinned cortical bone and detaching the cyst wall on the palatal side, the apical portion of the implant (approximately 3 mm) lodged inside the cyst was resected using a carbide bur. Thereafter, the entire cyst, including the resected implant, was removed *en bloc*. It was evident that the nasopalatine neurovascular bundle was incorporated into the cyst [Figure 3d]. The wound was closed by repositioning the mucoperiosteal flap, and no bone grafting materials were used to fill the defect.

The histopathological findings showed that the wall of the cystic lesion comprised of cuboidal, ciliated columnar and stratified squamous epithelium with underlying connective tissue. The cysts that form adjacent to oral mucosa of the incisal foramen was lined mainly by stratified squamous epithelium, whereas the lining close to the incisal foramen was lined by cuboidal and ciliated columnar epithelium, and there were no signs of inflammatory cell localization within the observed biopsy [Figure 3e]. Thus, based on the clinical and histological findings, the lesion was diagnosed as nasopalatine duct cyst developed in association with the dental implant placement.

After the cyst removal, the patient has been carefully followed by clinical, radiographic examinations (both periapical and CT) during maintenance visits scheduled every 4 months. The current status after 28 months after the cyst removal shows no signs of implant mobility, marginal gingival recession, or peri-implant inflammation. Compared with the radiographic findings before the cyst removal, the radio-opacity of the original lesional area seemed to have increased. The bone defect measured on the CT after the cyst removal is 4 mm \times 3 mm \times 4 mm, comparably smaller to the preoperative radiograph, suggesting a favorable healing [Figure 4].

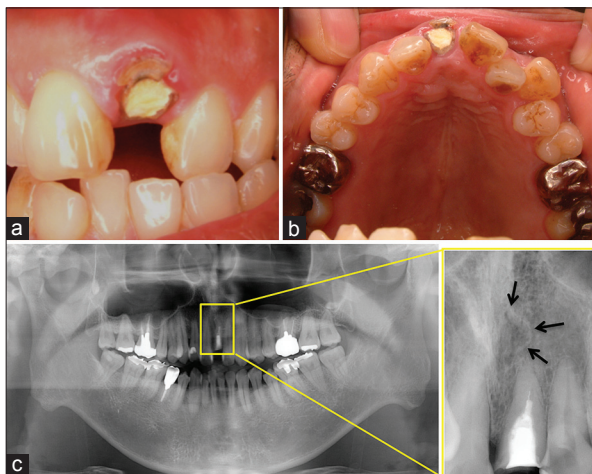


Figure 1: (a) Intraoral photograph at the initial visit (May 2005), (b) A mirror image of the maxillary dentition, (c) Panoramic radiograph at the initial visit (May 2005). There are no pathological findings such as enlarged periapical space or radiolucency. The arrows indicate the incisor canal

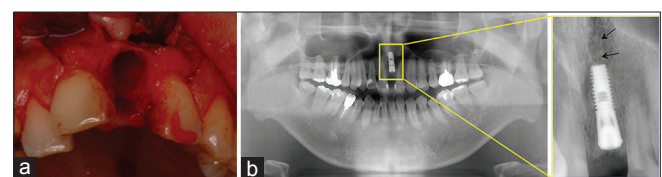


Figure 2: Immediate implant placement procedure (May 2005). (a) Intraoral photograph of the fresh extraction site. (b) Panoramic radiograph after the placement of the implant. The arrows indicate the incisor canal

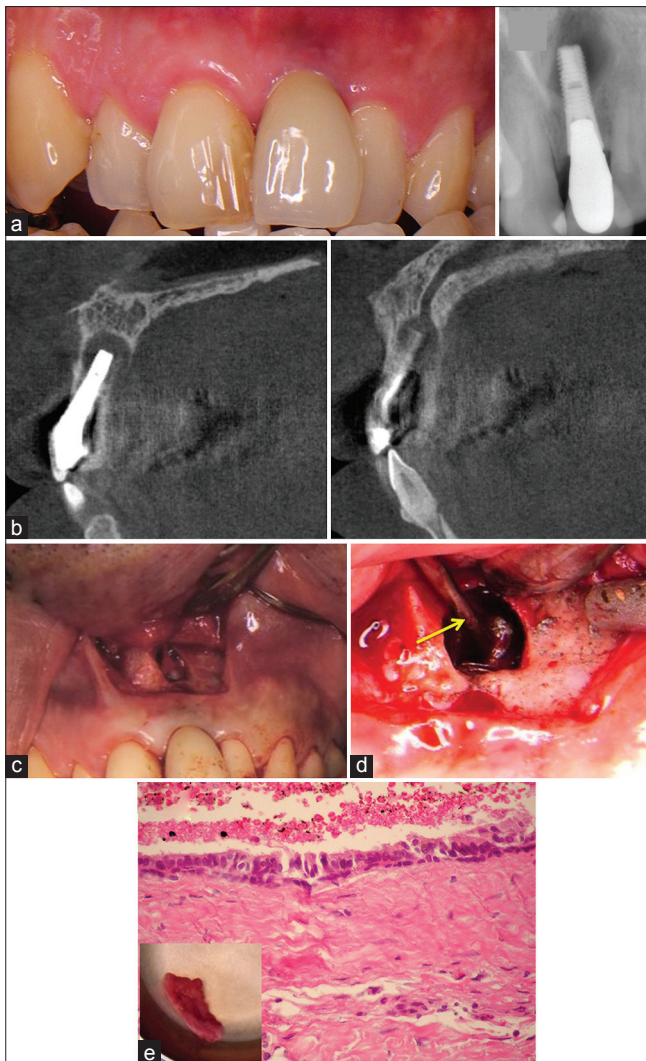


Figure 3: (a) Clinical and (b) radiographic situations 30 months after the implant placement (November 2007). Pulsation was detected on the palate, but there was no mobility of the implant. Oval radiolucency is found around the apical portion of the implant, (c) Computed tomography image 30 months after the implant placement (November 2007). A cyst-like radiolucency of the size of a crown (10 mm × 10 mm × 9 mm) was found surrounding the apical portion of the implant and continuous with the incisor canal, (d) Cyst removal and resection of the apical portion of the implant (November 2007). The arrow indicates the neurovascular bundle, (e) Histopathological analysis on the biopsy samples (November 2006). The cyst wall consisted of fibrous connective tissue lined by pseudostratified ciliated cuboidal epithelium. No large diameter blood vessels or nerve-fiber bundles were found in the specimen. (H&E stain, ×100)

DISCUSSION

Nasopalatine duct cyst is the most common non-odontogenic cyst developing from the proliferation of embryological epithelial remnants of nasopalatine duct.^[9,10] As indicated by Brode and Araiche, cyst formation may be stimulated by trauma and infection.^[11] In the current case report, the implants were placed centrally in the socket, which was from a prosthetic perspective, placed in an ideal situation. The fact that the nasopalatine canal was disturbed during the osteotomy

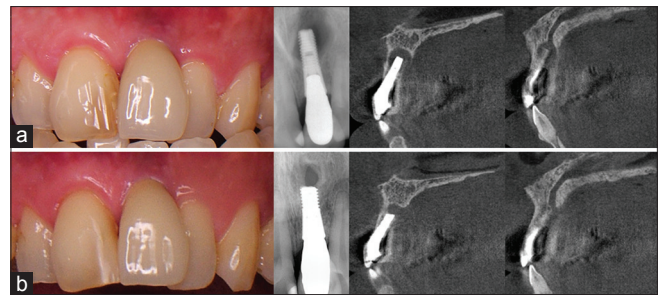


Figure 4: Intraoral photographs, periapical radiographs, and computed tomography of (a) before, and (b) 40 months after cyst removal (March 2011). The size of the radiolucent lesion was 10 mm × 10 mm × 9 mm; however, 40 months after cyst removal, the size of the radiolucent lesion decreased to 4 mm × 3 mm × 4 mm

possibly due to surgical trauma suggests that the canal, or at least part of the canal was relatively anteriorly positioned. This is an indication that the three-dimensional position of the nasopalatine canal differs greatly between patients and is in accordance with the study from Mraiwa *et al.* (2004).^[12] Casado *et al.*, reported in their case report that the immediately placed implants had to be removed due to the change in implant position seemingly affected by the cystic lesion.^[8] Whether or not partial or in full length, it is generally suggested that the implant should be removed along with the cystic lesion to avoid remnants of the contaminated tissue to be left in the cavity, which could eventually be the reason for osteomyelitis.^[13-15] Although it has been suggested by Casado *et al.*, that there is a possibility to keep the implant if it is immobile and the periapical lesion is not disturbing the surrounding teeth/implant.^[8] Ideally this is definitely a better treatment option considering the biomechanical aspect of the vertically loaded implant. However, one must also take into consideration the degree of the implant surface debridement. As reported by Persson *et al.*, the pristineness of the implant surface is the definite factor for reosseointegration,^[16] suggesting that if the implant is totally clean of pathogens, it will naturally be biocompatible again as it was before. However, the fact that most implant surfaces available today are roughened; it may be difficult to fully remove the pathogens from them. Although several mechanical and nonmechanical techniques have been proposed to decontaminate these roughened surfaces,^[17-22] it seems in the literature, there exists no evidence that these methods can completely decontaminate the surface.^[23] Thus, in our case, we decided to resect the implant because the implant itself showed no signs of peri-implant bone resorption/inflammation or mobility, and the implant was thought to be long enough (approximately 10 mm) to withstand the dynamic strain from the occlusal force, which was a treatment option also selected by Balshi *et al.*, showing long-term stability of the resected implants after the surgery.^[24] However, as seen in the follow-up tomography image, the radiolucency remains although the size of it has significantly decreased. Thus, considering the fact that the nasopalatine canal existed in vicinity of the implant, the radiolucency may be permanent and no further surgical compensation is thought to be necessary.

Overall, it is suggested that a careful consideration should be made regarding the preservation of implants incorporated in the cystic lesion.

CONCLUSION

When placing implants in the anterior maxilla, difficulties due to nasopalatine canal may be encountered. However, reports on postsurgical troubles arising from the interference of dental implant with the nasopalatine canal, or a nasopalatine duct cyst caused by an implant, are very few. In the case of this patient, the interference of the maxillary implant with the nasopalatine canal is considered to have induced the development of nasopalatine duct cyst. This experience reaffirmed the importance of preoperative evaluation of the nasopalatine canal by means of a CT scan. Ideally, maxillary implant placements in the anterior region should be done without damaging the nasopalatine canal, and if there is a risk of interference, preventive measures such as removal of neurovascular bundle inside the canal or bone grafting to protect the canal should be taken into consideration.

REFERENCES

- Annibaldi S, Ripari M, La Monaca G, Tonoli F, Cristalli MP. Local accidents in dental implant surgery: Prevention and treatment. *Int J Periodontics Restorative Dent* 2009;29:325-31.
- Artzi Z, Nemcovsky CE, Bitlimum I, Segal P. Displacement of the incisive foramen in conjunction with implant placement in the anterior maxilla without jeopardizing vitality of nasopalatine nerve and vessels: A novel surgical approach. *Clin Oral Implants Res* 2000;11:505-10.
- Liddelow G, Klineberg I. Patient-related risk factors for implant therapy. A critique of pertinent literature. *Aust Dent J* 2011;56:417-26.
- Spin-Neto R, Bedran TB, de Paula WN, de Freitas RM, Ramalho LT, Marcantonio E. Incisive canal deflation for correct implant placement: Case report. *Implant Dent* 2009;18:473-9.
- Henry PJ, Liddelow GJ. Immediate loading of dental implants. *Aust Dent J* 2008;53 Suppl 1:S69-81.
- Palmer R, Palmer P, Floyd P. Basic implant surgery. *Br Dent J* 1999;187:415-21.
- McCrea SJ. Nasopalatine Duct Cyst, a delayed complication to successful dental implant placement: Diagnosis and surgical management. *J Oral Implantol* 2012. [Epub ahead of print]
- Casado PL, Donner M, Pascarelli B, Derocy C, Duarte ME, Barboza EP. Immediate dental implant failure associated with nasopalatine duct cyst. *Implant Dent* 2008;17:169-75.
- Swanson KS, Kaugars GE, Gunsolley JC. Nasopalatine duct cyst: An analysis of 334 cases. *J Oral Maxillofac Surg* 1991;49:268-71.
- Nortje CJ, Wood RE. The radiologic features of the nasopalatine duct cyst. An analysis of 46 cases. *Dentomaxillofac Radiol* 1988;17:129-32.
- Brode H, Araiche M. Nasopalatine cyst: Report of a case. *J Oral Surg Anesth Hosp Dent Serv* 1959;17:64-5.
- Mraiwa N. The nasopalatine canal revisited using 2D and 3D CT imaging. *Dentomaxillofac Radiol* 2004;33:396-402.
- Piattelli A, Scarano A, Piattelli M, Podda G. Implant periapical lesions: Clinical, histologic, and histochemical aspects. A case report. *Int J Periodontics Restorative Dent* 1998;18:181-7.
- Reiser GM, Nevins M. The implant periapical lesion: Etiology, prevention, and treatment. *Compend Contin Educ Dent* 1995;16:768, 70, 72.
- Oh TJ, Yoon J, Wang HL. Management of the implant periapical lesion: A case report. *Implant Dent* 2003;12:41-6.
- Persson LG, Berglundh T, Lindhe J, Sennerby L. Re-osseointegration after treatment of peri-implantitis at different implant surfaces. An experimental study in the dog. *Clin Oral Implants Res* 2001;12:595-603.
- Jimbo R, Ono D, Hirakawa Y, Odatsu T, Tanaka T, Sawase T. Accelerated photo-induced hydrophilicity promotes osseointegration: An animal study. *Clin Implant Dent Relat Res* 2011;13:79-85.
- Waasdrop J, Reynolds M. Nonsurgical treatment of retrograde peri-implantitis: A case report. *Int J Oral Maxillofac Implants* 2010;25:831-3.
- Parlar A, Bosshardt DD, Cetiner D, Schafroth D, Unsal B, Haytac C, *et al.* Effects of decontamination and implant surface characteristics on re-osseointegration following treatment of peri-implantitis. *Clin Oral Implants Res* 2009;20:391-9.
- Persson LG, Mouhyi J, Berglundh T, Sennerby L, Lindhe J. Carbon dioxide laser and hydrogen peroxide conditioning in the treatment of periimplantitis: An experimental study in the dog. *Clin Implant Dent Relat Res* 2004;6:230-8.
- El Char ES, Jalbout ZN. Regeneration of an osseous peri-implantitis lesion. *Periodontal Clin Investig* 2002;24:5-10.
- Jalbout ZN, Tarnow DP. The implant periapical lesion: Four case reports and review of the literature. *Pract Proced Aesthet Dent* 2001;13:107-12.
- Renvert S, Polyzois I, Maguire R. Re-osseointegration on previously contaminated surfaces: A systematic review. *Clin Oral Implants Res* 2009;20 Suppl 4:216-27.
- Balshi SF, Wolfinger GJ, Balshi TJ. A retrospective evaluation of a treatment protocol for dental implant periapical lesions: Long-term results of 39 implant apicoectomies. *Int J Oral Maxillofac Implants* 2007;22:267-72.

How to cite this article: Takeshita K, Funaki K, Jimbo R, Takahashi T. Nasopalatine duct cyst developed in association with dental implant treatment: A case report and histopathological observation. *J Oral Maxillofac Pathol* 2013;17:319.

Source of Support: Nil. **Conflict of Interest:** None declared.