

## Effect of Mitomycin-C Augmented Trabeculectomy on Corneal Endothelial Cells

Reza Zarei, MD; Mohammad Zarei, MD; Ghasem Fakhraie, MD; Yadollah Eslami, MD; Sasan Moghimi, MD  
Masoud Mohammadi, MD; Ali Abdollahi, MD

Eye Research Center, Farabi Eye Hospital, Tehran University of Medical Sciences, Tehran, Iran

### Abstract

**Purpose:** To evaluate the effect of mitomycin-C (MMC) on corneal endothelial cell density (ECD) and morphology after trabeculectomy.

**Methods:** In this prospective comparative case series, 31 eyes with glaucoma underwent trabeculectomy with (group I), or without (group II) MMC. Specular microscopy was performed pre-, and postoperatively at months 1 and 3. Outcome measures included central corneal endothelial cell count and coefficient of variation (CV) of cell size.

**Results:** Overall, mean preoperative ECD was  $2,135.8 \pm 397.6$  cells/mm<sup>2</sup>; corresponding values at postoperative months 1 and 3 were  $2,019.6 \pm 447.2$  cells/mm<sup>2</sup>, and  $1,991.4 \pm 425.5$  cells/mm<sup>2</sup>, respectively ( $P > 0.05$ ). Cell loss from month 1 to 3 was 1.3% ( $P > 0.05$ ). Subgroup analysis showed significant differences in endothelial cell loss at month 1 ( $P = 0.048$ ) and month 3 ( $P = 0.014$ ) between the MMC and control groups with no significant difference between the two groups in terms of cell loss from months 1 to 3, postoperatively ( $P = 0.968$ ). Overall, mean pre-and postoperative CVs at months 1 and 3 were  $27.38 \pm 4.55$ ,  $27.96 \pm 4.26$ , and  $28.35 \pm 4.47$ , respectively, with no significant difference between the two groups ( $P > 0.05$ ). There was no correlation between preoperative central endothelial cell density (CECD) and MMC related cell loss.

**Conclusion:** MMC application in trabeculectomy seems to cause a small but significant corneal endothelial loss. Most of the damage occurs intraoperatively, or in the early postoperative period, however progressive endothelial cell loss is not a major concern.

**Keywords:** Coefficient of Variation; Corneal Endothelial Cell Density; Mitomycin C; Trabeculectomy

*J Ophthalmic Vis Res* 2015; 10 (3): 257-262.

### INTRODUCTION

Adjunctive antifibrotic agents, such as 5-fluorouracil (5-FU) or mitomycin-C (MMC), are commonly used to increase the success rate of glaucoma filtering

surgery.<sup>[1,2]</sup> Due to the greater potency and fewer complications, MMC is currently in widespread use in trabeculectomy.<sup>[3,4]</sup> MMC is an antibiotic derived from *Streptomyces caespitosus* with alkylating properties that exerts its most profound cellular toxicity in the late G1 and early S cellular phases.<sup>[5]</sup> It is suggested that in high doses, MMC has a cytotoxic effect that is independent of cell cycle.<sup>[6]</sup> Moreover, it is described as a radiomimetic agent with possible long-term consequences on tissues.<sup>[7]</sup> In trabeculectomy, MMC may penetrate into adjacent

#### Correspondence to:

Ghasem Fakhraie, MD. Farabi Eye Hospital, Qazvin Square, South Kargar Avenue, Tehran 13366, Iran.  
E-mail: gfakhraie@gmail.com

Received: 13-04-2014

Accepted: 28-10-2014

#### Access this article online

Quick Response Code:



Website:  
www.jovr.org

DOI:  
10.4103/2008-322X.170345

This is an open access article distributed under the terms of the Creative Commons Attribution-NonCommercial-ShareAlike 3.0 License, which allows others to remix, tweak, and build upon the work non-commercially, as long as the author is credited and the new creations are licensed under the identical terms.

For reprints contact: reprints@medknow.com

**How to cite this article:** Zarei R, Zarei M, Fakhraie G, Eslami Y, Moghimi S, Mohammadi M, *et al.* Effect of Mitomycin-C augmented trabeculectomy on corneal endothelial cells. *J Ophthalmic Vis Res* 2015;10:257-62.

ocular tissues, beyond its application site.<sup>[8]</sup> Since corneal endothelial cells lack division capacity, possible insults are irreparable and cell density diminishes gradually.<sup>[9,10]</sup>

Experiments have confirmed direct toxicity of MMC to endothelial cells,<sup>[8,11]</sup> but some authors believe that with the concentrations and methods used in trabeculectomy, MMC is unlikely to cause endothelial damage.<sup>[12,13]</sup> Pastor and associates described a 11% endothelial cell loss in humans, three months after MMC-supplemented trabeculectomy.<sup>[14]</sup> A prospective controlled clinical study has demonstrated endothelial cell loss 3 and 12 months after MMC-augmented trabeculectomy.<sup>[15]</sup> Others have found that 5-FU, and MMC cause similar changes in the corneal endothelium.<sup>[16]</sup> However, some clinical studies found that there was no significant MMC related endothelial toxicity, following combined glaucoma and cataract surgery, or trabeculectomy alone.<sup>[17,18]</sup>

The aim of this study was to evaluate the effect of MMC on corneal endothelial density and morphology by comparing two groups of patients, who underwent trabeculectomy with and without MMC.

## METHODS

This prospective comparative case series included patients scheduled for trabeculectomy at the Glaucoma Service, Farabi Eye Hospital, Tehran, Iran. Thirty-three eyes of 32 consecutive adult patients were enrolled in the study. The patients were assigned to two groups; Group I (controls,  $n = 16$ ) underwent standard trabeculectomy, while Group II ( $n = 17$ ) underwent trabeculectomy with intraoperative application of 0.2 mg/ml of MMC for 2 min. Assignment into each group was based on individual patient's risks for filtering surgery failure.

The study was approved by the Ethics Committee of Tehran University of Medical Sciences, and adhered to the tenets of the Declaration of Helsinki. Informed consent was obtained from all participants after providing detailed information. Central corneal endothelial cell count was measured using a non-contact specular microscope (TOPCON SP-2000P, Topcon, Tokyo, Japan) preoperatively, and also 1 and 3 months postoperatively. At each examination, 3 specular photographs were taken and mean measurements were used for analysis.

### Eligibility Criteria and Diagnostic Procedures

Inclusion criteria for the study were patients with primary open angle glaucoma (POAG), or pseudoexfoliative glaucoma (PXFG) who either, despite receiving maximal tolerable medical treatment, had higher than target IOP, or who were intolerant to medications.

Exclusion criteria included angle closure glaucoma, secondary glaucomas other than PXFG, previous intraocular surgery or laser procedures, performing cataract surgery simultaneously or during the follow-up period, intraocular disorders other than mild cataracts,

postoperative flat anterior chamber, endophthalmitis, marked postoperative inflammation, and intraoperative choroidal hemorrhage.

### Preoperative Evaluation

Baseline information, such as, age, gender, number of anti-glaucoma medications and medical history were recorded. All patients received a complete preoperative examination, including best corrected visual acuity measurement (Snellen chart), slit lamp examination, tonometry (Goldmann applanation tonometry), gonioscopy, dilated fundus examination, a Humphrey visual field (24-2, or 30-2) examination, and specular microscopy.

### Surgical Technique

The procedures were performed under peribulbar, retrobulbar, or general anesthesia. All surgeries were done by the same surgeon (RZ). After placing a superior clear corneal traction suture, or superior rectus traction suture, a fornix-based conjunctival flap was fashioned and a half thickness, 3 × 3 mm, lamellar scleral flap was dissected.

In Group II, two 2 × 3 mm pieces of surgical sponge saturated with 0.02% MMC solution were placed beneath the scleral flap and conjunctival flap. After 2 min, the sponges were removed, and the surgical area was irrigated with a minimum amount of 50 ml of balanced salt solution. Subsequently, a 1 × 2 mm trabecular block was removed. Peripheral iridectomy was done, and the scleral flap was closed with two 10-0 nylon sutures. The conjunctival flap was anchored on the limbus with 2 separate 10-0 nylon sutures. No viscoelastic or subconjunctival injection was used in any case.

Group I patients underwent the same procedure without intraoperative application of MMC.

The postoperative regimen consisted of antibiotic and cycloplegic drops every six hours for 1 week, steroid drops every six hours for the first week which was tapered over the first postoperative month. Removal of releasable sutures, or laser suture lysis was done per clinician discretion.

### Postoperative Evaluation

Slit lamp examination was performed on postoperative days 1 and 3, weeks 1 and 2, and months 1 to 3. If needed, more frequent visits were scheduled. Specular microscopy was repeated at months 1 and 3 postoperatively. Three specular photographs were taken at every examination, and the mean data were considered for statistical analysis.

### Statistical Analysis

Statistical analysis was performed using Statistical Package for Social Sciences software version 17 (SPSS

Inc., Chicago, Illinois, USA). Analysis of variance (ANOVA) was used to analyze intragroup changes in continuous variables pre-and postoperatively. The Mann-Whitney U test was used to compare mean values of intergroup continuous variables. Categorical data was evaluated using the Chi-square test. Wilcoxon one-sample nonparametric test was used to compare the means of intragroup continuous variables. The Spearman Rho (correlation coefficient) test was used to evaluate the correlation between the two continuous variables. For all measurements, a two-tailed test was used, and  $P < 0.05$  was considered as significant for measured variables.

## RESULTS

A total of thirty-three eyes of 32 patients were enrolled; these included 16 cases in Group I and 17 cases in Group II. In Group I, one patient failed to return for regular follow-up and was hence excluded from the study; in Group II one patient was excluded because of post-operative flat anterior chamber.

Patients' demographic and baseline characteristics are detailed in Table 1. Overall, mean age was  $57.96 \pm 17.4$  (range, 24 to 82) years, and 24 cases (78%) were males. Mean age was  $57.53 \pm 16.45$  years in Group I and  $58.37 \pm 18.8$  years in Group II ( $P > 0.05$ ).

There were no significant differences in terms of type of glaucoma, mean age, mean IOP, gender and preoperative specular microscopic findings between the two groups ( $P > 0.05$ ). Mean CECD was  $2,108.5 \pm 388$  cells/mm<sup>2</sup> in Group I and  $2,161.5 \pm 417$  cells/mm<sup>2</sup> in Group II ( $P > 0.055$ , Table 1).

Overall, CEDC was reduced insignificantly; mean pre- and postoperative months 1 and 3 CECDs were

$2,135.8 \pm 397.56$  cells/mm<sup>2</sup>,  $2,019.6 \pm 447.24$  cells/mm<sup>2</sup>, and  $1,991.4 \pm 425.49$  cells/mm<sup>2</sup>, respectively; representing a statistically non-significant cell loss of 5.4%, and 6.7% at postoperative months 1 and 3, respectively (both  $P > 0.05$ ) [Table 2]. A similar trend of statistically non-significant decrease from baseline CECD was observed in study groups I and II at postoperative months 1 and 3 ( $P > 0.05$ ) [Table 2 and Figure 1].

The percentage of cell loss from baseline to postoperative month 1 in group I versus II was 3.4% and 7.2%, respectively ( $P = 0.048$ ). CECD loss from baseline to postoperative month 3 in group I versus II was 4.6% and 8.7%, respectively ( $P = 0.014$ ). Although, CECD loss from months 1 to 3, in group I versus II was 1.2% and 1.5%, respectively, this difference was not statistically significant ( $P = 0.967$ , Table 3 and Figure 1).

Overall, mean coefficient of variation (CV) was 27.38% (SD, 4.55) before surgery, increasing to 27.96% (SD, 4.26) after 1 month, and 28.35% (SD, 4.4) after 3 months. This change was not significant statistically ( $P > 0.05$ ), [Table 4]. The CV in both study groups was increased from baseline at postoperative month 1 and 3, but was not statistically significant in either group ( $P > 0.05$ ). CV was not significantly different at any time point throughout the study period between the two groups [Table 4 and Figure 2].

There was no significant difference in mean postoperative IOP between the two groups.

No correlation was observed between preoperative CECD and CECD loss at postoperative months 1 and 3 ( $P = 0.20$  and  $0.37$ , respectively). Such a correlation was neither found in group I ( $P = 0.93$  and  $0.41$  at months 1 and 3, respectively), nor group II ( $P = 0.08$  and  $0.31$ , at months 1 and 3, respectively).

**Table 1. Patients' demographics and baseline characteristics**

	Group 1 (n=15)	Group 2 (n=16)	P	Overall (n=31)
Mean age (year)	57.53±16.45	58.37±18.8	0.677	57.96±17.4
Mean glaucoma medications (number)	3.20±0.67	3.18±0.65	0.744	3.19±0.65
IOP (mm Hg)	29.40±8.44	29.62±9.40	0.812	29.51±8.80
Female (%)	5:15 (33.3)	2:16 (12.5)	0.195	7 (22.5)
Preoperative CECD (cells/mm <sup>2</sup> )	2108.5±388.24	2161.5±417.11	0.813	2135.8±397.57
Preoperative CV	27.66±5.52	27.12±3.57	0.827	27.38±4.55
POAG: PXFG	13:2	13:3	0.682	26:31

IOP, intraocular pressure; CECD, central endothelial cell density; CV, coefficient of variation of cell size; POAG, primary open angle glaucoma; PXFG, pseudoexfoliative glaucoma

**Table 2. Overall CECD and CECD in each study group**

	Group 1		Group 2		Overall	
	Mean±SD (cells/mm <sup>2</sup> )	Range (cells/mm <sup>2</sup> )	Mean±SD (cells/mm <sup>2</sup> )	Range (cells/mm <sup>2</sup> )	Mean±SD (cells/mm <sup>2</sup> )	Range (cells/mm <sup>2</sup> )
Preoperative CECD	2108.5±388.24	1551.00-2842.00	2161.5±417.11	1571.00-2898.00	2135.8±397.56	1551.00-2898.00
CECD at month 1	2036.5±429.92	1325.00-2959.00	2003.8±476.433	1356.00-2694.00	2019.6±447.24	1325.00-2959.00
CECD at month 3	2011.5±415.03	1364.00-2791.00	1972.6±447.82	1309.00-2664.00	1991.4±425.49	1309.00-2791.00

SD, standard deviation; CECD, central endothelial cell density

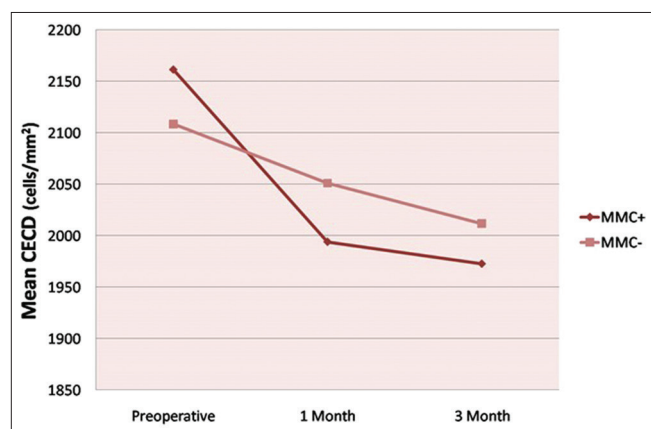
## DISCUSSION

The human corneal endothelium, which guarantees corneal transparency, is primarily a non-replicative tissue.<sup>[9,10,19]</sup> Endothelial damage reduces CECD, increases mean endothelial cell size and alters normal morphologic endothelial characteristics.<sup>[20]</sup> Although ECD is widely used as a parameter of corneal endothelial health, it does not reflect the dynamics of endothelial healing that occur following trauma. Functional healing may be more closely reflected in morphology, rather than cell density.<sup>[21]</sup> The early response to endothelial cell loss consists of enlarging and sliding of the remaining cells leading to increased CV and a decrease in hexagonality. Shifting of CV and hexagonality towards the pretrauma status indicate stabilization of the endothelium.<sup>[21]</sup>

Using specular microscopy, we analyzed endothelial cell loss and compared variations in cell size after trabeculectomy with and without MMC. The results of

the current study showed that non-significant endothelial cell loss occurs following trabeculectomy either with, or without MMC concomitant with a non-significant increase in CV of cell size. This occurred primarily due to small population size. In this study, differential CECD changes were compared between MMC-augmented trabeculectomy and trabeculectomy without MMC, rather than comparing CECD before and after the procedure. There is little doubt, if any, that trabeculectomy (with or without adjunctive anti-metabolites) causes endothelial cell loss.<sup>[2,4,21-23]</sup> In this study, CECD loss at postoperative month 3 in group I was 4.6%. The reported CECD loss in trabeculectomy has been reported to range from 0.2 to 14.9% at 3 months.<sup>[4,22,23]</sup> In the MMC group, we observed a postoperative CECD loss of 7.2% and 8.7% at months 1 and 3, respectively. This can be compared with the results published by Paulsen et al reporting CECD loss of 9.6%, and 10.0% at postoperative months 3 and 12, respectively, following MMC augmented trabeculectomy with 0.2 mg/ml MMC.<sup>[21]</sup> Others have reported CECD loss ranging from 4.98 to 14.52%, with MMC concentrations from 0.2 to 0.4 mg/ml, application times of 2 to 5 minutes, and follow-up periods ranging from 2 weeks to 12 months [Table 5].<sup>[14-16,18,24,25]</sup>

In this study, CECD loss was significantly higher in MMC group as compared to the control group, at postoperative months 1 and 3. This suggests that intraoperative use of MMC during trabeculectomy may cause a small, but significant corneal endothelial cell loss. This is in contradiction to some experimental studies, which have predicted that MMC-related endothelial cell loss in clinical settings are unlikely to happen.<sup>[12,13]</sup> Interestingly, this study has confirmed the potential clinical endothelial toxicity of MMC, which was noted previously in a prospective controlled clinical trial.<sup>[15]</sup> This suggests that laboratory studies may not



**Figure 1.** Preoperative and postoperative mean central endothelial cell density (CECD) in the study groups. MMC, mitomycin C.

**Table 3. Overall CECD loss and CECD loss in the two study groups**

	Group 1		Group 2		P	Overall	
	Mean±SD (cells/mm <sup>2</sup> )	Range (cells/mm <sup>2</sup> )	Mean±SD (cells/mm <sup>2</sup> )	Range (cells/mm <sup>2</sup> )		Mean±SD (cells/mm <sup>2</sup> )	Range (cells/mm <sup>2</sup> )
CECD loss pre-1	71.93±140.22	-117.00-402.00	157.69±109.29	-48.00-325.00	0.048	116.19±130.56	-117.00-+402.00
CECD loss pre-3	97.00±86.45	-36.00-291.00	188.94±104.66	4.00-335.00	0.014	144.45±105.57	-36.00-+335.00
CECD loss 1-3	25.06±73.15	-36.00-291.00	31.25±70.09	4.00-335.00	0.968	28.25±70.45	-111.00-206.00

SD, standard deviation; CECD loss pre-1, CECD loss at postoperative month 1 from baseline; CECD loss pre-3, CECD loss at postoperative month 3 from baseline; CECD loss 1-3, CECD loss from postoperative month 1 to postoperative month 3

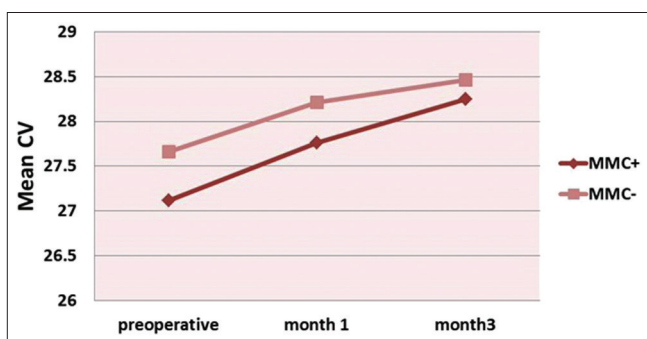
**Table 4. Overall CV and CV in each study group**

	Group 1		Group 2		P	Overall	
	Mean±SD	Range	Mean±SD	Range		Mean±SD	Range
Preoperative CV	27.12±3.57	21.00-33.00	27.66±5.52	20.00-36.00	0.827	27.38±4.55	20.00-36.00
CV at month 1	27.93±3.60	20.00-34.00	28.00±5.00	20.00-36.00	0.937	27.96±4.26	20.00-36.00
CV at month 3	28.25±3.75	20.00-34.00	28.46±5.27	19.00-37.00	0.781	28.35±4.47	19.00-37.00

SD, standard deviation; CV, coefficient of variation of cell size

reflect actual clinical situations. Sano et al failed to show significant MMC-related endothelial cell loss. However, their study was not controlled and had short follow-up.<sup>[18]</sup> Another prospective controlled study did not find a significantly higher cell loss in MMC group, as compared to the control group.<sup>[25]</sup> In the mentioned study, follow-up period varied widely, and mean follow-up period and types of glaucoma were different between the control and MMC groups. Furthermore, patients with postoperative iridocorneal touch were not excluded in either of the study groups. However, in this special subset of patients, the authors reported no significant difference in CECD loss between MMC treated eyes and controls.

These discrepancies observed in clinical studies may be attributable to variations in study design, sample size, surgical technique and follow-up period. Such discrepancies may also reflect that the effect of MMC on CECD is small. While this small cell loss would probably cause no significant clinical problem, a low or borderline preoperative endothelial cell count could significantly be affected by the intraoperative use of MMC, leading to a clinically decompensated cornea, as reported by some authors.<sup>[26,27]</sup>



**Figure 2.** Pre- and Post-operative mean endothelial cell coefficient of variation (CV) in the study groups. MMC, mitomycin C.

We observed no correlation between preoperative CECD and postoperative CECD loss. Furthermore, there has been no report on the possible correlation between preoperative CECD and CECD loss in MMC-augmented trabeculectomy. So, it seems that corneas with lower preoperative CECDs are not necessarily more susceptible to MMC-related endothelial cell loss. However, patient selection is still an important issue, because as mentioned before, modest endothelial loss in these patients may result in corneal decompensation. In this subset of patients, use of ocular viscoelastic devices may be helpful in reducing MMC-related CECD loss, as recommended by some authors.<sup>[24]</sup>

Although CECD loss at postoperative months 1 and 3 was significantly higher in the MMC group than in control group, CECD loss from months 1 to 3 was comparable in both study groups. This suggests that MMC-related endothelial toxicity takes place intraoperatively, or during the early postoperative period up to one month, and that progressive endothelial cell loss should not be a major concern. This is in accordance with Paulsen et al who found that significant cell loss occurs during, or immediately after MMC-augmented trabeculectomy with no progressive cell loss from 3 to 12 months.<sup>[21]</sup>

In this study, there was an increase in CV after surgery in both study groups as compared to baseline values, but these were not statistically significant at any time point. This is compatible with the report by Paulsen et al<sup>[21]</sup> They also reported that CV continued to increase slightly after the first year, but this increase was not statistically significant. Sano et al, reported a 1.9% increase in CV 2 to 3 weeks after MMC-augmented trabeculectomy, which was not statistically significant.<sup>[18]</sup>

No study has dealt with the association between pseudoexfoliation and corneal endothelial cell loss in trabeculectomy. In view of the small number of patients with pseudo-exfoliative glaucoma in this study, such analysis was not feasible.

**Table 5. Reported endothelial cell loss following MMC augmented trabeculectomy in clinical studies**

Study	n	MMC concentration (mg/ml)	Application time (min)	Follow-up	Mean cell loss (%)
Pastor et al 1993 <sup>[14]</sup>	10	0.4	4	3 months	11.7
Kweon et al 1995 <sup>*[25]</sup>	23	0.2	2-5 (mean=4)	5-18 m (mean=10.3 months)	10.1
Dreyer et al 1995 <sup>[16]</sup>	15	0.4	5	12 months	7
Sano et al 1998 <sup>*[18]</sup>	119	U	U	2-3 weeks	4.98
Sihota et al 1998 <sup>[15]</sup>	10	0.2	2	3 months	13.90
	10	0.4	4	3 months	14.52
Shin et al 2003 <sup>[24]</sup>	18	0.2	2.4±1.2	3 months	7.7
Paulsen et al 2008 <sup>[21]</sup>	14	0.2	2	3 months	9.5
Current study	16	0.2	2	1 month	7.2
				3 months	8.7

\*Only abstract available in English; n, number of eyes; MMC, mitomycin C; min, minutes; m, month; U, undetermined

In the current study, chronological changes were analyzed on the corneal endothelium following trabeculectomy; we also compared these changes between the two groups of patients. Other studies have evaluated only one of these aspects. This study could be considered among the few studies, which tried to elucidate the effect of MMC on corneal endothelial cell loss in trabeculectomy in a prospective fashion. Prior to this study, correlations between preoperative CECD and post-trabeculectomy CECD loss have not been addressed.

We assessed the endothelium of the central cornea and did not evaluate the peripheral cornea; thus significant regional differences in cell density could have been missed. Endothelial cell toxicity may be local, or more prominent adjacent to the site of application and central corneal parameters may not actually reflect the whole effect.<sup>[14,28]</sup> Although CECD was used to assess corneal endothelial damage, endothelial cellular shape indices, such as hexagonality, may be more sensitive for assessing endothelial injury.<sup>[29]</sup>

We suggest that the use of confocal microscopy in future studies, may be a better method to study the effect of this agent on different corneal layers, other than the endothelium.

Further prospective studies involving larger numbers of patients with longer follow up, and at the same time measuring other indices, including hexagonality in the entire endothelium are recommended.

### Financial Support and Sponsorship

This study was supported by a grant from the Tehran University of Medical Science (TUMS).

### Conflicts of Interest

There are no conflicts of interest.

### REFERENCES

- Chen CW, Huang HT, Bair JS, Lee CC. Trabeculectomy with simultaneous topical application of mitomycin-C in refractory glaucoma. *J Ocul Pharmacol* 1990;6:175-182.
- Palmer SS. Mitomycin as adjunct chemotherapy with trabeculectomy. *Ophthalmology* 1991;98:317-321.
- Kitazawa Y, Kawase K, Matsushita H, Minobe M. Trabeculectomy with mitomycin. A comparative study with fluorouracil. *Arch Ophthalmol* 1991;109:1693-1698.
- Smith DL, Skuta GL, Lindenmuth KA, Musch DC, Bergstrom TJ. The effect of glaucoma filtering surgery on corneal endothelial cell density. *Ophthalmic Surg* 1991;22:251-255.
- Dorr RT. New findings in the pharmacokinetic, metabolic, and drug-resistance aspects of mitomycin C. *Semin Oncol* 1988;15 3 Suppl 4:32-41.
- Khaw PT, Sherwood MB, MacKay SL, Rossi MJ, Schultz G. Five-minute treatments with fluorouracil, floxuridine, and mitomycin have long-term effects on human Tenon's capsule fibroblasts. *Arch Ophthalmol* 1992;110:1150-1154.
- Sugar A. Who should receive mitomycin-C after pterygium surgery? *Ophthalmology* 1992;99:1645-1646.
- Wu KY, Hong SJ, Huang HT, Lin CP, Chen CW. Toxic effects of mitomycin-C on cultured corneal keratocytes and endothelial cells. *J Ocul Pharmacol Ther* 1999;15:401-411.
- Joyce NC. Proliferative capacity of the corneal endothelium. *Prog Retin Eye Res* 2003;22:359-389.
- Joyce NC. Cell cycle status in human corneal endothelium. *Exp Eye Res* 2005;81:629-638.
- Derick RJ, Pasquale L, Quigley HA, Jampel H. Potential toxicity of mitomycin C. *Arch Ophthalmol* 1991;109:1635.
- McDermott ML, Wang J, Shin DH. Mitomycin and the human corneal endothelium. *Arch Ophthalmol* 1994;112:533-537.
- Nuyts RM, Pels E, Greve EL. The effects of 5-fluorouracil and mitomycin C on the corneal endothelium. *Curr Eye Res* 1992;11:565-570.
- Pastor SA, Williams R, Hetherington J, Hoskins HD, Goodman D. Corneal endothelial cell loss following trabeculectomy with mitomycin C. *J Glaucoma* 1993;2:112-113.
- Sihota R, Sharma T, Agarwal HC. Intraoperative mitomycin C and the corneal endothelium. *Acta Ophthalmol Scand* 1998;76:80-82.
- Dreyer EB, Chaturvedi N, Zurakowski D. Effect of mitomycin C and fluorouracil-supplemented trabeculectomies on the anterior segment. *Arch Ophthalmol* 1995;113:578-580.
- Cohen JS, Greff LJ, Novack GD, Wind BE. A placebo-controlled, double-masked evaluation of mitomycin C in combined glaucoma and cataract procedures. *Ophthalmology* 1996;103:1934-1942.
- Sano T, Fukuchi T, Sawaguchi S, Hara H, Watanabe J, Oota A, et al. Influences of trabeculectomy combined with the use of mitomycin C on corneal endothelial cells. *Nihon Ganka Gakkai Zasshi* 1998;102:365-370.
- Tuft SJ, Coster DJ. The corneal endothelium. *Eye (Lond)* 1990;4:389-424.
- Mishima S. Clinical investigations on the corneal endothelium-XXXVIII Edward Jackson Memorial Lecture. *Am J Ophthalmol* 1982;93:1-29.
- Storr-Paulsen T, Norregaard JC, Ahmed S, Storr-Paulsen A. Corneal endothelial cell loss after mitomycin C-augmented trabeculectomy. *J Glaucoma* 2008;17:654-657.
- Fiore PM, Richter CU, Arzeno G, Arrigg CA, Shingleton BJ, Bellows AR, et al. The effect of anterior chamber depth on endothelial cell count after filtration surgery. *Arch Ophthalmol* 1989;107:1609-1611.
- Korey M, Gieser D, Kass MA, Waltman SR, Gordon M, Becker B. Central corneal endothelial cell density and central corneal thickness in ocular hypertension and primary open-angle glaucoma. *Am J Ophthalmol* 1982;94:610-616.
- Shin DB, Lee SB, Kim CS. Effects of viscoelastic material on the corneal endothelial cells in trabeculectomy with adjunctive mitomycin-C. *Korean J Ophthalmol* 2003;17:83-90.
- Kweon JG, Park JM, Yoo JM, Bae JH. Corneal central endothelial cell loss after trabeculectomy with mitomycin C. *J Korean Ophthalmol Soc* 1995;36:829-833.
- Fukuchi T, Hayakawa Y, Hara H, Abe H. Corneal endothelial damage after trabeculectomy with mitomycin C in two patients with glaucoma with cornea guttata. *Cornea* 2002;21:300-304.
- Mietz H, Roters S, Kriegelstein GK. Bullous keratopathy as a complication of trabeculectomy with mitomycin C. *Graefes Arch Clin Exp Ophthalmol* 2005;243:1284-1287.
- Nassiri N, Nassiri N, Rahnavardi M, Rahmani L. A comparison of corneal endothelial cell changes after 1-site and 2-site phacotrabeculectomy. *Cornea* 2008;27:889-894.
- Matsuda M, Suda T, Manabe R. Serial alterations in endothelial cell shape and pattern after intraocular surgery. *Am J Ophthalmol* 1984;98:313-319.