

Norbert Cionca
Nada Müller
Andrea Mombelli

Two-piece zirconia implants supporting all-ceramic crowns: A prospective clinical study

Authors' affiliations:

Norbert Cionca, Nada Müller, Andrea Mombelli,
Division of Periodontology and Oral
Pathophysiology, School of Dental Medicine,
University of Geneva, Geneva, Switzerland

Corresponding author:

Andrea Mombelli, Prof. Dr. med. dent.
Division of Periodontology and Oral
Pathophysiology
School of Dental Medicine
University of Geneva
Rue Barthélemy-Menn 19
CH-1205 Geneva, Switzerland
Tel.: +41 22 379 40 30
Fax: +41 22 379 40 32
e-mail: andrea.mombelli@unige.ch

Key words: case series, dental implants, zirconium

Abstract

Objectives: The aim of this prospective clinical study is to evaluate the safety and efficacy of a new all-ceramic implant system to replace missing teeth in partially edentulous patients.

Material and methods: Thirty-two partially edentulous, systemically healthy patients were treated with 49 two-piece zirconia implants (ZERAMEX® T Implant System). Zirconia abutments were connected with adhesive resin cement. Single-unit full-ceramic crowns were cemented. The cases have been followed for 588±174 days after loading (range 369–889 days). All patients have been re-evaluated 1 year after loading.

Results: The cumulative survival rate 1 year after loading was 87% implants. All failures were the result of aseptic loosening, and no implants were lost after the first year. The results of the other cases were good, and the patients were very satisfied. The cumulative soft tissue complication rate was 0%, the cumulative technical complication rate was 4% implants, the cumulative complication rate for bone loss >2 mm was 0%, and the cumulative esthetic complication rate was 0%. Including the data from 20 patients treated with an earlier version of the system, an over-all 2-year cumulative survival rate of 86% was calculated for a total of 76 two-piece zirconia implants supporting all-ceramic crowns in 52 patients.

Conclusions: Replacement of single teeth in the posterior area was possible with this new full-ceramic implant system. Failures were due to aseptic loosening.

In the last four decades, dental implants have become an established treatment for the replacement of missing teeth. The predominant material used today is commercially pure titanium. Two systematic reviews have concluded that the 5-year survival rates of titanium implants carrying single crowns (Jung et al. 2012) or bridges (Pjetursson et al. 2012) are high (97% and 95% implants, respectively); nonetheless, biological and technical complications occur. For single crowns on titanium implants, a 5-year cumulative soft tissue complication rate of 7%, a cumulative complication rate for bone loss >2 mm of 5%, and a cumulative esthetic complication rate of 7% were calculated (Jung et al. 2012). The prevalence of peri-implantitis during 5–10 years after implant placement is estimated in the order of 10% implants and 20% patients (Mombelli et al. 2012). Some authors have suggested adverse immune reactions to titanium oxide as a possible contributing factor to biological complications (Jacobi-Gresser et al. 2013). To what extent peri-implant infections could be lowered

by choosing another implant material is unknown. Alternative materials would not only have to be biocompatible but also durable and usable from a prosthodontic point of view.

Zirconia ceramics have been proposed as an alternative implant material. Cell culture studies have shown favorable biological reactions to zirconia, with no adverse response of osteoblasts and osteoblast-like cells (for review, see Kohal et al. 2008). Animal experiments have proven that osseointegration can be achieved with implants made from this material (Akagawa et al. 1993, 1998; Kohal et al. 2004). Good osseointegration was achieved with zirconia implants with roughened surfaces (Depprich et al. 2008a,b; Saulacic et al. 2013).

Zirconia ceramics are used for joint replacement prostheses in orthopedic surgery (Piconi et al. 2003, 2007). Dental zirconia implants have been brought to the market in recent years as well. Due to concerns regarding the physical properties of macroscopically complex ceramic structures, the first systems were one-piece implants. From a surgical and

Date:

Accepted 22 February 2014

To cite this article:

Cionca N, Müller N, Mombelli A. Two-piece-zirconia implants supporting all-ceramic crowns. A prospective clinical study.
Clin. Oral Impl. Res. 26, 2015, 413–418
doi: 10.1111/clr.12370

prosthodontic perspective, however, a device consisting of an implant body and an abutment would be preferred. So far, the available evidence for long-term success of dental zirconia implants is incomplete (Andreietelli et al. 2009). A recent review (Depprich et al. 2014) identified 17 publications; however, most studies only provided evidence on a low level due to design limitations, and only one paper (Nevins et al. 2011) presented a single case treated with a two-piece zirconia implant. Clearly, more primary research is necessary to assess the value of ceramic implants and to determine the factors influencing their success.

From November 2009–August 2010, we treated a first series of 20 partially edentulous patients with a newly available two-part all-ceramic implant system (first-generation Zeremex implants, Dentalpoint AG, Zürich Switzerland). The performance of the 27 implants placed in these 20 patients is subject to continuous routine monitoring as recommended for a newly introduced system (Hujuel et al. 2013). Based on input from early users, including us, multiple aspects of the system (implant geometry, surface characteristics, surgical kit) were subsequently modified. We currently evaluate the efficacy and safety of this modified implant system (ZERAMEX® T implant system) in a prospective study. Here, we present 1-year outcomes for the first time for this new system. As a secondary objective, we also present the 3-year outcomes of the first-generation Zeremex implants.

Material and methods

This was a single-center, open-labeled, longitudinal case series. The Ethical Committee of the University Hospitals of Geneva, Geneva, Switzerland, approved the protocol. Research was conducted according to the principles outlined in the Declaration of Helsinki on human medical experimentation. Written informed consent was obtained from all participants.

Patients

Between November 2010 and June 2012, 34 participants were recruited from individuals seeking treatment at the School of Dental Medicine, University of Geneva. They were partially edentulous and requested replacement of missing teeth. Eligible participants were adults aged 20 or over, systemically healthy, with tooth loss treatable by the insertion of implants and single-unit crowns.

A bone substrate sufficient in quality and volume to allow proper anchorage of the implants was a prerequisite. It was required that the participant could be treated as a regular patient under standard clinical conditions. Thus, persons with an increased risk for complications, that is, those with current major systemic or oral pathologies, or subjects needing extensive preparatory treatments of hard or soft tissues in order to make implant placement possible, were not included.

The following conditions were explicit exclusion criteria: Smoking more than 10 cigarettes per day, addicted to alcohol or other substances, heavily overweight, severely compromised general health, extensive bone loss in the area of prospective implantation, not willing to attend regular dental maintenance care and follow up evaluations, poor oral hygiene, that is, full-mouth plaque score (FMPS) >20%.

Test products

The participants were treated with the ZERAMEX® T Implants system (Dentalpoint AG, Zürich, Switzerland), an all-ceramic implant system intended to replace missing teeth in partially edentulous patients. The product consists of an implantable device and an abutment, both made from highly dense zirconium dioxide (ZrO₂-ATZ-Bio-HIP, Metoxit AG, Thayngen, Switzerland), and the instruments and accessory parts to insert the device in the jawbone and to install the prosthodontic suprastructure. The surgical drills are coated with a carbon layer. Implants of three diameters (3.5, 4.2, 5.5 mm) and three lengths (8, 10, 12 mm) were available. All parts originated from regular production. The abutments were bonded into the implants with an adhesive resin cement (Panavia™ F, Kuraray, Tokyo, Japan). Full-ceramic crowns were made from lithium disilicate glass ceramic (IPS e.max Press, Ivoclar Vivadent AG, Schaan, Lichtenstein).

Clinical protocol

If necessary, the teeth of the participants were cleaned to remove plaque, stain, and calculus prior to surgery. Treatment was not commenced unless the mucosa of recipient and neighboring sites was looking healthy and all extraction sites were healed. The implants were selected and inserted according to the manufacturer's recommendations and guidelines by a single experienced clinician, a certified periodontist with specific training in implant dentistry (N.C.). Under local anesthesia, a mid-crestal incision was made, and a full-thickness flap was elevated

to expose the alveolar ridge. If necessary, the flap was extended horizontally by intrasulcular incisions around neighboring teeth; vertical releasing incisions were avoided. The implant bed was prepared using a sequence of drills. After perforating the cortical bone with a 2-mm-diameter round bur, the initial osteotomy was realized with a 2.3-mm-diameter pilot drill and then enlarged using a sequence of twist drills. As an example, to place a 3.5-mm-diameter implant, the osteotomy was accomplished using a 2.3-mm and a 3.5-mm drill. The preparation was finalized with a tapering drill corresponding to the shape of the implant. All implants were inserted by hand. If considered necessary, the local bone was augmented with a xenogenic bone mineral and a collagen membrane (BioOss® and BioGuide®, Geistlich Pharma, Wolhusen, Switzerland) in the same session. Depending of the soft tissue thickness, either a healing cap or a gingiva former was fitted on the implant to achieve a non-submerged healing. After a healing period of 3 months, the zirconia abutments were connected. The second therapist (N.M.) restored all implants with single-unit full-ceramic crowns.

Data were collected before the placement of the implant (visit 1), immediately upon placement of the implant (visit 2), immediately after the insertion of the suprastructure (visit 3), and 1 year (±2 weeks) after loading (visit 4). The clinical evaluation included the inspection of dental and periodontal conditions of neighboring teeth, implant mobility, local modified Plaque Index (mPII), modified Sulcus Bleeding Index (mBI) (Mombelli et al. 1987), peri-implant probing depth (PPD), and the presence or the absence of suppuration upon probing at six sites (mesial-buccal, mid-buccal, distal-buccal, mesial-lingual, mid-lingual, distal-lingual) of the implant. Upon crown placement, and 1 year thereafter, the patients were asked to rate satisfaction on a visual analog scale (VAS) by placing a mark on a horizontal line, 100 mm long, labeled with "fully satisfied with the outcome" at one end and with "not at all satisfied" at the other. Periapical radiographs were taken before implant placement, after surgery, upon placement of the suprastructure, and 1 year after loading.

Data analysis

The rates of success, failure, and complications were expressed as frequency per first year after loading for all implants. Cumulative rates were calculated after 1 and 2 years using the method of Kaplan–Meier (Kaplan & Meier 1958).

Results

Study population

Thirty-four patients were initially included, however, two of them turned out to have an increased risk for complications, and consequently were excluded: One because of smoking more than 10 cigarettes per day, one because of extensive bone loss in the area of prospective implantation. The mean age of the 32 participants was 51.9 years, range 24–75, 56% were female, and 13% were smokers.

Observations on study treatments

A total of 49 implants were placed in 32 patients. Twenty-one participants received a single implant, eight participants received two implants, two participants received three implants, one patient received six implants. These implants replaced one missing incisor, 23 premolars, and 25 molars. Twenty-five implants were placed in the lower, and 24 in the upper jaw.

The intraosseous implant lengths were 8 mm (eight implants), 10 mm (29 implants), or 12 mm (12 implants). Thirteen implants had a diameter of 5.5 mm, 35 implants had a diameter of 4.2 mm, and one implant had a diameter of 3.5 mm. In one case, the local bone was augmented laterally in the region of the upper left first premolar. Figs 1–3 show a case of the study.

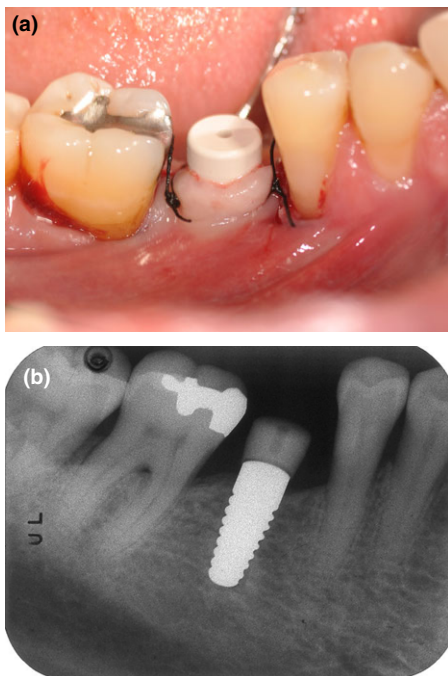


Fig. 1. (a, b) Photograph and radiograph of one case on day of surgery.

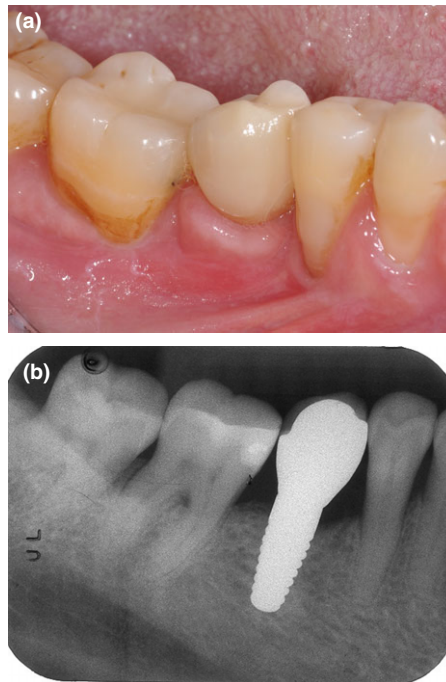


Fig. 2. (a, b) Photograph and radiograph at loading.

Surgical outcomes

All implants were placed as intended, in sites with a sufficient width of keratinized mucosa, and primary stability was reached in all cases. Soft tissue healing was good. Three months after surgery, all implants were stable, with one exception: One implant showed mobility upon inspection, indicating absence of osseointegration. The implant had a diameter of 4.2 mm, a length 10 mm, and replaced a right lower first molar. The patient had not noted anything wrong and was free of pain or discomfort. The peri-implant tissues looked healthy. There were no clinical signs of inflammation or infection. The implant could be unscrewed without anesthesia. There was no granulation tissue. The site was curetted to induce bleeding and was subject to open healing, which was uneventful. A check of the medical and dental history revealed no specific risk factors for implant loss, except that this patient had already lost another implant at the same site previously.

Prosthetic treatment

Zirconia abutments were connected, and single-unit full-ceramic crowns were fitted on 48 implants in 31 patients. On average, the implants were loaded 193 ± 79 days after surgery. All participants were very satisfied with the outcome at the time of crown cementation (4 mm mean VAS score on a scale from 0 to 100 mm, 13 mm maximum score).

Follow-up

Two patients were lost to follow-up: One patient with one implant could not be contacted any longer due to moving out of the country. One patient with one implant was lost due to death for reasons unrelated to the study (cardiac arrest). No other serious adverse events were noted.

Two abutments, in two different patients, fractured. In both cases, the residue of the fractured abutment was removed, a new abutment was inserted, and a new crown was fitted successfully. The first incident occurred in the region of the first upper left molar, 10 days after crown placement. An investigation revealed a technical error due to a communication problem between the clinic and the laboratory. The second incident occurred in the region of the lower left first molar, 8 months after crown placement. The reason for the second fracture is unknown.

Five implants were lost, one 3 months after loading (diameter 4.2 mm, length 8 mm, region of right upper first premolar), one after 5 months (diameter 5.5 mm, length 10 mm, region of right lower first molar), two after 6 months (left upper second premolar: diameter 4.2 mm, length 10 mm; right lower first molar: diameter 5.5 mm, length 10 mm), and one after 10 months (diameter 4.2, length 10 mm, region of left upper second premolar). The first four failures occurred in patients, where only one implant had been placed, the fifth happened in a patient with six implants. In all cases, the clinical circumstances were alike: Mobility, not accompanied by pain or discomfort, was suddenly noted. The clinical exam showed healthy-looking peri-implant tissues with no signs of inflammation or infection (Fig. 4). No specific causes or risks for implant failure could be identified on the level of the site or the subject. The implants were unscrewed, and the sites were curetted to induce bleeding. Healing was uneventful in all cases.

The remaining 41 implants have been followed for 588 ± 174 days after loading (range 369–889 days, 10/10/2013). Thirteen implants in nine patients have been followed up for more than 2 years. All 25 patients were examined after 1 year. No technical or biological complications other than the ones described above were revealed at the 1-year control visit or at a later time. After 1 year, all patients continued to be very satisfied with the results of therapy (4 mm mean VAS score on a scale from 0 to 100 mm, 12 mm maximum score). An inspection of the peri-implant tissues revealed no visible signs of inflammation such as redness or swelling in any case. Mean PPD

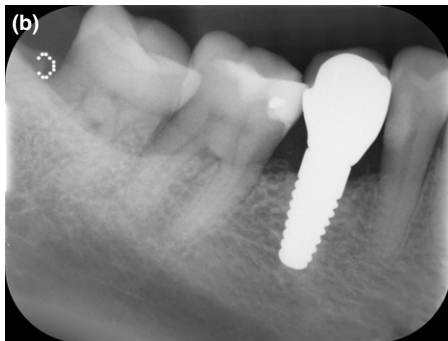
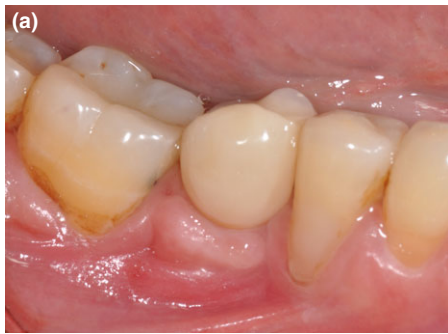

Fig. 3. (a, b) Photograph and radiograph 1 year after loading.

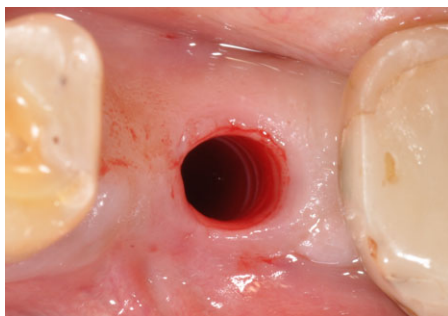


Fig. 4. Aseptic loosening.

was 3.2 ± 0.7 mm (Table 1). No sites showed suppuration or marked bleeding upon probing (mBI score >1). Isolated bleedings spots were visible at 27% sites (mBI score 1). No plaque could be seen by the naked eye (mPLI score >1). The comparison of radiographs taken upon placement of the suprastructure and 1 year after loading revealed no bone loss >1 mm.

The cumulative survival rates (SR) 1 and 2 years after loading were 87% implants (Table 2). All implant failures were a result of aseptic loosening. The cumulative soft tissue complication rate was 0%, the cumulative technical complication rate was 4% implants, the cumulative complication rate for bone loss >2 mm was 0%, and the cumulative esthetic complication rate was 0%.

One- and 3-year outcomes of first-generation Zeramex implants

The 1- and 3-year outcomes of 27 first-generation Zeramex implants are presented here as

Table 1. Clinical status of peri-implant tissues monitored at six sites (mesial-buccal, mid-buccal, distal-buccal, mesial-lingual, mid-lingual, distal-lingual) at each implant. Data are means \pm standard deviation (PPD), or numbers and frequency (%) of positive sites

	Loading ($n = 276$ sites on 46 implants)	One-year ($n = 246$ sites on 41 implants)
PPD	3.1 ± 0.6 mm	3.2 ± 0.7 mm
PPD >4 mm, PPD >5 mm	5 (2%), 1 ($<1\%$)	10 (4%), 1 ($<1\%$)
mBI >0 , mBI >1	17 (6%), 0 (0%)	66 (27%), 0 (0%)
mPLI >0 mm, mPLI >1 mm	19 (7%), 0 (0%)	52 (21%), 0 (0%)
Suppuration	0 (0%)	0 (0%)

Table 2. Lifetable analysis for placed implants

Time period	Patients	Implants	Number lost	% Survival	% Cumulative SR
Placement to loading	32	49	1	98.0	98.0
Loading to 1 year	29	46	5	89.1	87.3
1–2 years	9	13	0	100.0	87.3

ancillary data. These implants were placed in 20 patients from November 2009–August 2010 and are routinely monitored since then. In two of these patients, a sinus floor elevation (“Trap door” technique) had been performed 4 months prior to implant placement. Implants were used to replace seven premolars and 20 molars, 18 in the lower, and nine in the upper jaw. The intraosseous implant lengths were 8 mm (five implants), 10 mm (12 implants), and 12 mm (10 implants). All implants were placed as intended, and primary stability was reached in all cases. Soft tissue healing was uneventful; no adverse events and no complaints were noted. After 3 months, all implants were stable, indicating the presence of an osseointegration. Zirconia abutments were bonded into the implants, and single-unit full-ceramic crowns were fitted. Four implants in four different patients showed mobility and had to be removed due to aseptic loosening: two after 2 weeks, one 4 months and one 6 months after loading. The other implants have been followed up 39 ± 3 months after loading (range 35–45 months). No further implants were lost, and no signs of peri-implant infections were noted. On one crown, chipping of porcelain was noted. The 1-year survival rate was 85% implants, the survival from 1 to 3 years was 100%, and thus, the cumulative 3-year survival rate was 85% implants.

Including the data from 20 patients treated with an earlier version of the system, an over-all 2-year cumulative survival rate of 86% was calculated for a total of 76 two-piece zirconia implants supporting all-ceramic crowns in 52 patients.

Discussion

The primary aim of the present prospective clinical study was to evaluate the 1-year

outcomes of a new two-piece ceramic implant system, restored with single-unit full-ceramic crowns. This is the first study reporting results from such implants. The cumulative survival rate, 1 year and 2 years after loading, was 87% implants. A common failure pattern, clearly emerged: The mobility of the implant suddenly increased, while there were no preceding or concurrent signs of infection (redness, swelling, bleeding, suppuration, or pain) or a technical problem. All implants could be unscrewed effortlessly and without inducing bleeding or suppuration. Consequently, we can clearly rule out peri-implantitis as the cause. The analysis of one retrieved implant by scanning electron microscopy evidenced complete absence of bony residues on the implant surface. Altogether, these findings suggest that there was sudden mechanical breakdown of the interface between the implant and the bone. The reason for this to occur remains to be elucidated. A non-infectious process resulting in bone resorption, for which the term “aseptic loosening” is used, has been described in the orthopedic literature (Allain et al. 1999). In this field, aseptic loosening appears to have a multifactorial etiology. Osteolysis seems to be induced by wear debris modulating the expression of RANK- κ B/RANL and osteoprotegerin (Gehrke et al. 2003).

Apart from this phenomenon, and except the fracture of two abutments that could be replaced, up to now no further problems occurred in our study. Survival rates ranging from 74% to 98% after 12–56 months have been reported for one-piece zirconia implants by other investigators (for review see Depprich et al. 2014). In one prospectively followed cohort, the cumulative survival rate was 95% implants after 1 year (Kohal et al. 2012). However, a mean bone loss of 1.3 mm from implant insertion to the 1-year evaluation was noted. A total of 34% implants lost more than

2 mm, and 14% lost more than 3 mm of bone. According to clinical judgment, this bone loss was not associated with inflammation. In our study, similar peri-implant bone loss was not observed. Another study (Pirker & Kocher 2009) evaluated non-submerged, root-analog zirconia implants with two different surfaces in 18 patients for immediate replacement of single-rooted teeth. In one group, implant surfaces were roughened by sandblasting only; in the other group, additional macro-retentions were provided. All implants were lost within 2 months in the first group, while a 92% survival rate was reported for 1–33 months in the second group, with minimal bone resorption and soft tissue recession. A recent animal study provided histo-morphometric data on the impact of surface properties of zirconium implants on osseointegration, indicating favorable effects of acid etching (Saulacic et al. 2013).

Another randomized clinical trial evaluated the survival and success of one-piece zirconia implants, placed either immediately in post-extraction sockets or healed sites (Cannizzaro et al. 2010). Five implants (12.5%) were lost within 10 days to 2 months after loading. Four of the failing implants were placed as post-extractive implants; three of them were subject to immediate occlusal loading. The

average bone loss was 0.9 mm for immediately loaded implants and 0.7 mm if the implants were not loaded immediately.

One-piece zirconia dental implants with three different roughened surfaces have been evaluated up to 5 years year in 378 patients (Oliva et al. 2010). The overall implant success rate of 831 implants was 95% after 3.4 ± 0.2 years. The success rate of the acid-etched surface group was significantly better than that of the other two. As in our study, failures were clustering in the first year after loading.

In the present study, the 1-year clinical exam evidenced healthy conditions of the peri-implant tissues throughout the entire cohort. No sites showed suppuration, redness, swelling, or marked bleeding upon probing (mBI score >1). Based on observations in periodontally healthy subjects (Lang et al. 1991; Karayiannis et al. 1992), isolated bleedings spots, as seen at 27% sites in our sample (mBI score 1), are to be expected even in the absence of inflammation due to mechanical tissue stimulation. The system reveals thus an excellent biocompatibility and stability of the soft tissues. It has already been speculated that inflammatory reactions are less expressed in peri-implant tissues in contact

with zirconia than titanium surfaces. A comparative immuno-histochemical evaluation of human peri-implant soft tissues associated with either titanium or zirconium oxide healing caps revealed more inflammatory infiltrate in the titanium specimens, with higher expression of VEGF and NOS, higher proliferative activity, and micro-vessel density (Degidi et al. 2006).

Conclusion

Replacement of single teeth in the posterior area was possible with this new full-ceramic implant system. Failures were due to aseptic loosening. Further long-term monitoring will be necessary to demonstrate durability.

Acknowledgement: This study was supported by a grant from Dentalpoint AG, Zürich, Switzerland. All exams related to the study, the implants, and the crowns were free of charge to the participants. Other specific benefits were not given to the patients. The authors report no conflicts of interest related to this study.

References

- Akagawa, Y., Hosokawa, R., Sato, Y. & Kamayama, K. (1998) Comparison between freestanding and tooth-connected partially stabilized zirconia implants after two years' function in monkeys: a clinical and histologic study. *Journal of Prosthetic Dentistry* **80**: 551–558.
- Akagawa, Y., Ichikawa, Y., Nikai, H. & Tsuru, H. (1993) Interface histology of unloaded and early loaded partially stabilized zirconia endosseous implant in initial bone healing. *Journal of Prosthetic Dentistry* **69**: 599–604.
- Allain, J., Le Mouel, S., Goutallier, D. & Voisin, M.C. (1999) Poor eight-year survival of cemented zirconia-polyethylene total hip replacements. *Journal of Bone and Joint Surgery. British Volume* **81**: 835–842.
- Andriotelli, M., Wenz, H.J. & Kohal, R.J. (2009) Are ceramic implants a viable alternative to titanium implants? A systematic literature review. *Clinical Oral Implants Research* **20**(Suppl. 4): 32–47.
- Cannizzaro, G., Torchio, C., Felice, P., Leone, M. & Esposito, M. (2010) Immediate occlusal versus non-occlusal loading of single zirconia implants. A multicentre pragmatic randomised clinical trial. *European Journal of Oral Implantology* **3**: 111–120.
- Degidi, M., Artese, L., Scarano, A., Perrotti, V., Gehrke, P. & Piattelli, A. (2006) Inflammatory infiltrate, microvessel density, nitric oxide synthase expression, vascular endothelial growth factor expression, and proliferative activity in peri-implant soft tissues around titanium and zirconium oxide healing caps. *Journal of Periodontology* **77**: 73–80.
- Depprich, R., Naujoks, C., Ommerborn, M., Schwarz, F., Kübler, N.R. & Handschel, J. (2014) Current findings regarding zirconia implants. *Clinical Implant Dentistry and Related Research* **16**: 124–137.
- Depprich, R., Zipprich, H., Ommerborn, M., Mahn, E., Lammers, L., Handschel, J., Naujoks, C., Wiesmann, H.P., Kubler, N.R. & Meyer, U. (2008a) Osseointegration of zirconia implants: an SEM observation of the bone-implant interface. *Head & Face Medicine* **4**: 25.
- Depprich, R., Zipprich, H., Ommerborn, M., Naujoks, C., Wiesmann, H.P., Kiattavorncharoen, S., Lauer, H.C., Meyer, U., Kubler, N.R. & Handschel, J. (2008b) Osseointegration of zirconia implants compared with titanium: an in vivo study. *Head & Face Medicine* **4**: 30.
- Gehrke, T., Sers, C., Morawietz, L., Fernahl, G., Neidel, J., Frommelt, L. & Krenn, V. (2003) Receptor activator of nuclear factor kappaB ligand is expressed in resident and inflammatory cells in aseptic and septic prosthesis loosening. *Scandinavian Journal of Rheumatology* **32**: 287–294.
- Hujoel, P., Becker, W. & Becker, B. (2013) Monitoring failure rates of commercial implant brands, substantial equivalence in question? *Clinical Oral Implants Research* **24**: 725–729.
- Jacobi-Gresser, E., Huesker, K. & Schutt, S. (2013) Genetic and immunological markers predict titanium implant failure: a retrospective study. *International Journal of Oral and Maxillofacial Surgery* **42**: 537–543.
- Jung, R.E., Zembic, A., Pjetursson, B.E., Zwahlen, M. & Thoma, D.S. (2012) Systematic review of the survival rate and the incidence of biological, technical, and aesthetic complications of single crowns on implants reported in longitudinal studies with a mean follow-up of 5 years. *Clinical Oral Implants Research* **23**(Suppl. 6): 2–21.
- Kaplan, E.L. & Meier, P. (1958) Nonparametric estimation from incomplete observations. *Journal of the American statistical association* **53**: 457–481.
- Karayannis, A., Lang, N.P., Joss, A. & Nyman, S. (1992) Bleeding on probing as it relates to probing pressure and gingival health in patients with a reduced but healthy periodontium. *Journal of Clinical Periodontology* **19**: 471–475.
- Kohal, R.J., Att, W., Bachle, M. & Butz, F. (2008) Ceramic abutments and ceramic oral implants. An update. *Periodontology* **2000**: 224–243.
- Kohal, R.J., Knauf, M., Larsson, B., Sahlin, H. & Butz, F. (2012) One-piece zirconia oral implants: one-year results from a prospective cohort study. 1. Single tooth replacement. *Journal of Clinical Periodontology* **39**: 590–597.
- Kohal, R.J., Weng, D., Bachle, M. & Strub, J.R. (2004) Loaded custom-made zirconia and titanium implants show similar osseointegration: an animal experiment. *Journal of Periodontology* **75**: 1262–1268.
- Lang, N.P., Nyman, S., Senn, C. & Joss, A. (1991) Bleeding on probing as it relates to probing

- pressure and gingival health. *Journal of Clinical Periodontology* **18**: 257–261.
- Mombelli, A., Müller, N. & Cionca, N. (2012) The epidemiology of peri-implantitis. *Clinical Oral Implants Research* **23**(Suppl. 6): 67–76.
- Mombelli, A., Van Oosten, M.A.C., Schürch, E. & Lang, N.P. (1987) The microbiota associated with successful or failing osseointegrated titanium implants. *Oral Microbiology and Immunology* **2**: 145–151.
- Nevins, M., Camelo, M., Nevins, M.L., Schupbach, P. & Kim, D.M. (2011) Pilot clinical and histologic evaluations of a two-piece zirconia implant. *International Journal of Periodontics and Restorative Dentistry* **31**: 157–163.
- Oliva, J., Oliva, X. & Oliva, J.D. (2010) Five-year success rate of 831 consecutively placed Zirconia dental implants in humans: a comparison of three different rough surfaces. *International Journal of Oral and Maxillofacial Implants* **25**: 336–344.
- Piconi, C., Maccauro, G., Angeloni, M., Rossi, B. & Learmonth, I.D. (2007) Zirconia heads in perspective: a survey of zirconia outcomes in total hip replacement. *Hip International: the Journal of Clinical and Experimental Research on Hip Pathology and Therapy* **17**: 119–130.
- Piconi, C., Maccauro, G., Muratori, F. & Brach Del Prever, E. (2003) Alumina and zirconia ceramics in joint replacements. *Journal of Applied Biomaterials & Biomechanics* **1**: 19–32.
- Pirker, W. & Kocher, A. (2009) Immediate, non-submerged, root-analogue zirconia implants placed into single-rooted extraction sockets: 2-year follow-up of a clinical study. *International Journal of Oral and Maxillofacial Surgery* **38**: 1127–1132.
- Pjetursson, B.E., Thoma, D., Jung, R., Zwahlen, M. & Zembic, A. (2012) A systematic review of the survival and complication rates of implant-supported fixed dental prostheses (FDPs) after a mean observation period of at least 5 years. *Clinical Oral Implants Research* **23**(Suppl. 6): 22–38.
- Saulacic, N., Erdosi, R., Bosshardt, D.D., Gruber, R. & Buser, D. (2013) Acid and alkaline etching of sandblasted zirconia implants: a histomorphometric study in miniature pigs. *Clinical Implant Dentistry and Related Research* [Epub ahead of print]. Doi: 10.1111/cid.12070.