

Retinitis Pigmentosa in Onitsha, Nigeria

Summary

Background: Retinitis pigmentosa describes a heterogenous group of progressive hereditary degeneration of the photoreceptor-retinal pigment epithelium complex with varying clinical manifestations. Although studies on the epidemiology of blindness and visual impairment in Nigeria have documented the contribution of retinitis pigmentosa, detailed study of the prevalence, incidence, and pattern of retinitis pigmentosa in Nigeria are few. **Objectives:** The aim of this study was to describe the relative frequency rate and pattern of retinitis pigmentosa among new patients at the Guinness Eye Center Onitsha Nigeria. **Materials and Methods:** Case files of new patients with clinical features of retinitis pigmentosa seen over a 6-year period were reviewed. Information on age, sex, and associated clinical features were extracted into a standard proforma and analyzed. **Results:** Thirty-seven (0.6%) of 5876 new patients had retinitis pigmentosa. There were 25 (67.6%) males and 12 (32.4%) females with an age range of 4–76 years; the median age was 33 years. Family history suggested autosomal dominant inheritance in 15 (40.6%) patients, autosomal recessive inheritance 4 (10.8%), X-linked inheritance 9 (24.3%), and 9 (24.3%) sporadic. Six (16.2%) patients were blind (acuity <3/60) and 22 (59.5%) patients had visual impairment (acuity <6/18). Eight (21.6%) patients had coexistent deafness (syndromic retinitis pigmentosa) including two (5.4%) cases of Usher syndrome. **Conclusions:** The relative frequency rate of retinitis pigmentosa among new patients in our hospital is low but the associated visual and otologic incapacitation are enormous. A prospective study incorporating molecular genetics would more exactly determine the inheritance pattern and the common genes of retinitis pigmentosa in Nigerians.

Keywords: *Blindness, deafness, pattern, retinitis pigmentosa*

Introduction

Retinitis pigmentosa describes progressive hereditary degeneration of the photoreceptor-retinal pigment epithelium complex.^[1] It is not an inflammatory condition. Rather it is a heterogenous group of rod-cone dystrophies with varying clinical manifestations. It includes a wide spectrum of disorders with diverse chromosomal, metabolic, and morphologic features.

The retinal photoreceptors consist of the rods and the cones. The rods are found mainly in the periphery and mid-periphery of the retina; they are not present in the macula. The cones are found mainly in the macula (central retina). Normally, although the rods are used for scotopic (night) vision, the cones are important for photopic (daylight) vision. The photoreceptor degeneration leads to poor night vision (night blindness), visual field defects, and eventually blindness.^[2,3]

The Mendelian mode of inheritance includes autosomal dominant, autosomal recessive, and

This is an open access journal, and articles are distributed under the terms of the Creative Commons Attribution-NonCommercial-ShareAlike 4.0 License, which allows others to remix, tweak, and build upon the work non-commercially, as long as appropriate credit is given and the new creations are licensed under the identical terms.

For reprints contact: reprints@medknow.com

X-linked; sporadic cases also occur. Sporadic cases have a more favorable prognosis with retention of central vision until the sixth decade of life. The autosomal dominant variant has the best prognosis among all inherited retinitis pigmentosa; it has a later onset and runs a milder course than autosomal recessive. The X-linked recessive disease is least common, has an earlier onset, and runs the most severe course resulting in complete blindness by the third or fourth decade of life.^[1,2] Thus, the age of onset, the rate of progression of the disease, eventual visual loss, and associated ocular features are often linked to the mode of inheritance.

Mutation in more than 250 genes has been linked to inherited retinal dystrophies.^[1] Retinitis pigmentosa may also be associated with other diseases. These are known as retinitis pigmentosa syndromes and include Usher, Refsum, Cockayne, Kearns-Sayre, Bassen-Kornzweig, Bardet-Biedl syndromes among others.^[1-3]

Several studies on the epidemiology of blindness and visual impairment in Nigeria have documented the contribution of retinitis pigmentosa.^[4-9] Retinitis pigmentosa

How to cite this article: Nwosu SN, Ndulue CU, Ndulue OI, Uba-Obiano CU. Retinitis pigmentosa in Onitsha, Nigeria. *J West Afr Coll Surg* 2020;10:30-5.

Sebastian N. N. Nwosu^{1,2,3},
Chikaodili U. Ndulue^{4,5},
Oluchi I. Ndulue⁴,
Chizoba U. Uba-Obiano^{1,3}

¹Department of Ophthalmology, Nnamdi Azikiwe University, Awka, ²Centre for Eye Health Research and Training, Nnamdi Azikiwe University, Awka, ³Guinness Eye Center, Onitsha, ⁴Ebony Eye Specialist Clinic, Onitsha, ⁵Department of Otorhinolaryngology, University of Benin Teaching Hospital, Benin City, Nigeria

Received: 28-Dec-2021

Accepted: 30-Jan-2022

Published: 26-Mar-2022

Address for correspondence:

Prof. Sebastian N. N. Nwosu,
Guinness Eye Center, PMB 1534,
Onitsha, Nigeria.
E-mail: sabenwosu@gmail.com

Access this article online

Website:

www.jwacs-jcoac.org

DOI: 10.4103/jwas.jwas_65_21

Quick Response Code:



constitutes 11.1% of retinal diseases at the Guinness Eye Center Onitsha where it is also an important cause of blindness and low vision.^[4] However, detailed study of the prevalence, incidence, and pattern of retinitis pigmentosa in Nigeria are few.^[10,11]

Ukponmwan and Atamah^[10] in a study in Benin City reported that 50% of retinitis pigmentosa patients were blind at presentation. Onakpoya *et al.*^[11] in a multicenter study in South West Nigeria reported that retinitis pigmentosa was present in 71.4% of the siblings of the index cases. Both studies independently reported that males predominantly were affected and loss of vision and nyctalopia were the most common symptoms.^[10,11]

Eballe *et al.*^[12] in a hospital-based study of retinitis pigmentosa in Cameroun reported a frequency rate of 0.16%; bilateral blindness was recorded in 30% of the patients and 27.5% had low vision.^[12] A study in South Africa reported that retinitis pigmentosa was the most common cause of inherited blindness.^[13] In Kuwait, retinitis pigmentosa was reported to be a leading cause of disability.^[14]

This article reports on the relative frequency rate and pattern of retinitis pigmentosa seen at the Guinness Eye Center Onitsha Nigeria over a 6-year period.

Materials and Methods

This was a retrospective study. The case files of new patients with clinical features of retinitis pigmentosa seen between January 1, 2014 and December 31, 2019 were reviewed. Information on age, sex, symptoms, presenting visual acuity, other clinical features, and the possible mode of inheritance were abstracted into a standard proforma and analyzed.

In this study, retinitis pigmentosa was defined as retinal dystrophy with the following features: perivascular bone spicule retinal pigmentation, attenuated retinal arterioles, and optic disk pallor with or without contracted visual fields in a patient complaining of visual obscuration especially at night and in dim illumination. This definition did not include electrophysiological tests findings as facilities for these tests were not available. In our hospital, patients with the above features who also complained of hearing impairment had otorhinolaryngological evaluation.

There are no facilities for molecular genetic studies and assessment of mode of inheritance was based on family history. A patient was deemed to have autosomal dominant retinitis pigmentosa if there was a history of the disease in the patient's parents, uncle, and or siblings; autosomal recessive inheritance was taken if the patient was the only one affected in the family and there was a history of the disease among cousins of both parents; X-linked inheritance was recorded if the patient's brother or grandfather had the disease but the patient's father and mother had no clinical disease. In the absence of a clear history suggestive of inheritance, the disease was regarded as sporadic.

In this study blindness was defined as visual acuity <3/60; low vision, acuity <6/18 – ≥3/60, and visual impairment, acuity <6/18.

Results

During the study period, 37 (0.6%) out of 5876 new patients had retinitis pigmentosa. There were 24 (67.6%) males and 13 (32.4%) females (male:female ratio = 2:1). The age range was 4–76 years; median age was 33 years; 21 (57.2%) patients were young adults aged 20–49 years. Table 1 shows the age and sex distribution of the patients.

All the patients complained of visual blurring which worsened in a poorly illuminated environment. The duration of symptoms at the time of presentation in our hospital was 1–20 years with a median of 7 years. All the adult patients acknowledged that the problem started in childhood or adolescence.

Family history suggested autosomal dominant inheritance in 15 (40.6%) patients, autosomal recessive inheritance 4 (10.8%) patients, and X-linked inheritance 9 (24.3%) patients. Two of the four patients considered to have autosomal recessive disease had ophthalmic, otorhinolaryngologic, and central nervous system features consistent with Usher syndrome; six (16.2%) other adult patients had hearing impairment and two (5.4%) of these had profound deafness. Thus, eight (21.6%) patients had syndromic retinitis pigmentosa. Clinical history was unrevealing of the mode of inheritance in 9 (24.3%) patients and in line with our definition these were regarded as sporadic. Figure 1 shows the presumed mode of inheritance of retinitis pigmentosa in the patients.

Ocular comorbidities included five (13.5%) patients with cataract (three recorded as immature cataract and two as posterior subcapsular); of the five cataract patients one had bilateral couching; primary open-angle glaucoma was diagnosed in two (5.4%) patients and “maculopathy” in one (2.7%) patient. The glaucoma patients had high intraocular pressures (28 and 32 mm Hg), disc excavation, and contracted visual fields (constricted in all meridian with a diameter <30° from fixation). Retinal pigment epithelial atrophy with unmasking of choroidal vessels, referred in older literature as tessellated fundus or choroidal sclerosis, was not specifically documented in the case files; similarly, epiretinal membrane and cystoid macula edema were not specifically documented although one patient was recorded as having “maculopathy”.

Table 2 shows the presenting and best-corrected visual acuity in the better eyes of the patients. Twenty-two (59.5%) patients had bilateral visual impairment; six (16.2%) patients were

Table 1: Age and sex distribution

Age (years)	Male	Female	Total	%
0–9	1	2	3	8.2
10–19	3	3	6	16.2
20–29	4	3	7	18.9
30–39	6	1	7	18.9
40–49	6	1	7	18.9
50–59	2	–	2	5.4
60–69	1	3	4	10.8
≥70	1	–	1	2.7
Total	24	13	37	100.0

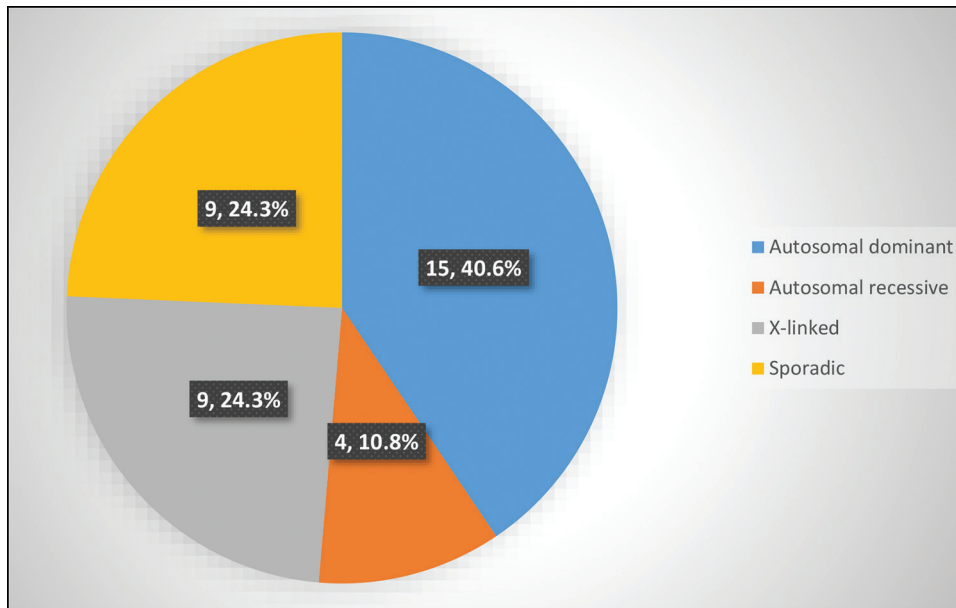


Figure 1: Mode of inheritance of retinitis pigmentosa

Table 2: Presenting and best-corrected visual acuity (better eye)

Visual acuity (Snellen)	Presenting acuity (%)	Best corrected acuity (%)
6/6	2 (5.4)	2 (5.4)
6/9	5 (13.5)	6 (16.2)
6/12	5 (13.5)	7 (18.9)
6/18	3 (8.2)	4 (10.8)
6/24	4 (10.8)	5 (13.5)
6/36	4 (10.8)	3 (8.2)
6/60	6 (16.2)	4 (10.8)
3/60	2 (5.4)	2 (5.4)
<3/60-LP	6 (16.2)	4 (10.8)
Total	37 (100.0)	37 (100.0)

bilaterally blind. Unilateral blindness was recorded in two (5.4%) patients; these patients also had visual impairment in their better eyes. Four (10.8%) patients with visual acuity >6/18 in the better eye also had low vision in the worse eye. Refraction improved visual acuity in eight (21.6%) patients, including one of the patients with Usher syndrome. These patients had hypermetropia two; simple myopia three, high myopia two, and myopic astigmatism one. Low vision optical aids enhanced vision in another six (16.2%) patients.

Automated perimetry became available in the last 2 years of this review. All the 13 patients that had visual field tests during this time had contracted fields with 4 (30.8%) having tunnel vision (severe constriction from ring scotomata or coalescence of double arcuate scotoma, <10° from fixation; even with good visual acuity, such patient is classified as blind) and three unable to fixate test target. One of the patients with tunnel vision had visual acuity 6/6. However, he complained of inability to see objects on his side as well as difficulty crossing the road.

Prior to the availability of automated perimetry, all our patients had visual fields tested by the confrontation method. The results were not traced on paper or electronic devices. The results were documented in the records of our earlier patients as “field loss” or “field defect”. Thus, although the results suggested abnormal visual fields, they did not clearly state the type of visual field defect.

Discussion

The results of this study show a low relative frequency rate (0.6%) of retinitis pigmentosa in our hospital with most of the patients presenting as young adults. These observations are similar to the experience of Ukponmwan and Atamah^[10] in Benin City, Nigeria, and Onakpoya *et al.*^[11] in a multicenter study in South West Nigeria. Studies on retinitis pigmentosa conducted outside Nigeria reported similar findings.^[12-14] In Cameroun, the mean age of retinitis pigmentosa patients as recorded in a hospital-based study was 43.3 years^[12]; in Japan, Tsujikawa *et al.*^[15] reported the mean age of retinitis pigmentosa patients to be 35.1 years. Al-Merjan *et al.*^[14] in a review of blindness and low vision in Kuwait reported that retinitis pigmentosa was the leading cause of disability in persons aged 60 years and above. In Denmark, Buch *et al.*^[16] analyzed the findings of the Copenhagen City Eye Study and reported that retinitis pigmentosa was the leading cause of blindness in persons aged 20–64 years. The visual and otologic incapacitation in these young patients are much and the negative economic impact on the community will expectedly be huge. Almost all the patients were in the economically productive age group and even the older patients had the disease from childhood. Retinitis pigmentosa is a common diagnosis among children in schools for the visually impaired in Nigeria.^[17,18]

Although visual loss in these patients may be ascribed mostly to retinitis pigmentosa, it bears to emphasize that ocular comorbidities including cataract, glaucoma and ametropia also contributed to the burden of visual incapacitation. Treatment of these coexistent ocular problems would enhance or stabilize vision. Modern cataract surgery with an intraocular lens implant greatly improves vision. When treatment is started early visual incapacitation from glaucoma can to a large extent be mitigated. Optical correction either with simple spectacles or low vision aids greatly enhances vision as evidenced from refraction findings in this study. Myopia is the most common type of ametropia in retinitis pigmentosa^[2,3] and this is corroborated in this study where 67% of cases of refractive errors were due to myopia. On the contrary, as reported recently by Lu and Su,^[19] patients with retinitis pigmentosa may be misdiagnosed and treated simply as myopia.

Posterior subcapsular cataract is a comorbidity of retinitis pigmentosa. Of the five patients who also were diagnosed with cataracts in this study, two were specifically recorded as posterior subcapsular cataracts. Cataract, irrespective of the morphologic type, increases the burden of visual incapacitation of the patients. That a patient underwent couching reflects the effort by the patient in seeking a solution to visual incapacitation. On the contrary, it could also suggest two things: (a) that patronage of traditional cataract couchers still persists in our environment (b) that orthodox eye care services have limited coverage or patronage within the catchment area of our hospital. Eye care facilities and eye health workers are few and their distribution is skewed in favor of urban areas. These result in huge unmet eye care needs in remote rural areas. All stakeholders in eye care should therefore intensify efforts to ensure a wider service coverage of the population, especially in the rural areas.

Some studies had documented an association between glaucoma and retinitis pigmentosa, putting the prevalence at 2%–12%.^[20,21] In a 5-year review of 1400 patients with retinitis pigmentosa, Peng *et al.*^[20] reported that 32 (2.3%) had glaucoma. Of the 32 only 2 (6.3%) had open-angle glaucoma; others had angle-closure had glaucoma. Similarly Badeeb *et al.*^[21] in a review of 538 retinitis pigmentosa patients reported that 1.03% had angle-closure glaucoma. These studies suggest that angle-closure glaucoma is more commonly associated with retinitis pigmentosa. This study did not document any case of angle-closure glaucoma. The 5.4% rate of primary open-angle glaucoma recorded in this study is within the 2%–12% range. Onakpoya *et al.*^[11] also noted that 11.5% of their patients had open-angle glaucoma. Glaucoma is the most common cause of irreversible blindness in Nigeria^[9]; it is prevalent among the Igbo ethnic group who predominantly inhabit South East geopolitical zone of the country^[9]—location of this study. An analysis of the intraocular pressure distribution and visual field defects among retinitis pigmentosa patients with and without a clinical diagnosis of glaucoma was limited by the very few glaucoma patients (2 out of 37). It was difficult ascertaining whether the generalized contracted fields in the glaucoma were

mainly due to glaucoma or retinitis pigmentosa. Nonetheless, in an environment where glaucoma is of public health concern, retinitis pigmentosa patients should also be routinely evaluated for glaucoma.

It has been suggested that visual fields plotted with the Goldmann perimeter better shows peripheral field changes than automated perimetry.^[2] But Goldmann perimeter was not available and the confrontation field testing method used before the availability of automated perimetry in our hospital was not reproducible. In any case, perhaps because of the advanced state of the disease in most of our patients, visual field defects were detectable in all the 13 patients tested with the automated perimeter.

The mode of inheritance in this study suggests that autosomal dominant disease was most common, autosomal recessive least and 21.6% of patients had syndromic retinitis pigmentosa. However, Oswald *et al.*^[13] in an analysis of 130 persons in South Africa, reported that although 14% were presumed to be autosomal dominant, 9.5% were autosomal recessive and 35% could not be classified into any specific genetic category and another 35% had syndromic retinitis pigmentosa.^[13] In another South African study that utilized molecular genetic technique, Greenberg *et al.*^[22] reported that among 125 families in Cape Town, 23% were autosomal dominant, 27% autosomal recessive and 50% were sporadic. However, the authors cautioned that 10 families had insufficient pedigree. A study in Spain reported that among nonsyndromic retinitis pigmentosa, autosomal dominant disease constituted 14%, autosomal recessive 39% and genetic type could not be established in 4%; Usher disease was the most common type of syndromic retinitis pigmentosa.^[23] These findings suggest that the distribution of the inheritance mode of retinitis pigmentosa reported (even when study is conducted in the same environment) depends on the technique used.

A male preponderance (67.6%) recorded in this study is comparable to the finding (66.7%) of Ukponmwan and Atama^[10] in Benin City, Nigeria, and the 57.3% documented by Onakpoya *et al.*^[11] in south-western Nigeria. Although X-linked genetic inheritance skews the incidence of disease to the male gender, this may not plausibly be the case in a retrospective hospital study in which a strict criterion was not set for obtaining genetic disease history from the patients at the time of hospital consultation. In any case, in this study, a history suggestive of X-linked inheritance was obtained in nearly a quarter of the patients while a similar proportion was considered sporadic. Although Ukponmwan and Atama^[10] did not give details of the inheritance pattern of their patients, Onakpoya *et al.*^[11] in their retrospective study documented that 21.9% of their patients had a positive family history of retinitis pigmentosa and 4.2% had syndromic retinitis pigmentosa. Our study documented two cases of Usher syndrome as well as six other patients with hearing loss. Thus, otorhinolaryngologic assessment should be part of the routine evaluation of retinitis pigmentosa patients.

Posterior segment findings in retinitis pigmentosa include bone spicule pigmentation, pigment epithelial atrophy in the mid-peripheral fundus, attenuated arterioles, cystoid macula edema, waxy disc pallor, vitreous cells, loss of foveal reflex, epiretinal membrane (previously known as cellophane or surface wrinkling maculopathy) with irregularity of vitreoretinal interface.^[2,3] Sun *et al.*^[24] in an analysis of 32 retinitis pigmentosa patients in northeast China reported that apart from bone spicule pigmentation, choroidal atrophy and high myopia were most common posterior segment findings. Retinal pigment epithelial atrophy with unmasking of choroidal vessels, referred in older literature as tessellated fundus or choroidal sclerosis, was not specifically documented in the case files; similarly, epiretinal membrane and cystoid macula edema were not specifically documented although one patient was recorded as having maculopathy. This case of maculopathy may be an epi-retinal membrane or cystoid macular edema. However, the diagnosis of cystoid macula edema would have been more confidently made with fluorescein angiography. Non-documentation does not imply that no patient had these features. This study was retrospective and relied on documentation in patients' case files that may not contain all the required information. Lack of full documentation is the bane of retrospective studies.

Retinal degeneration of the type seen in retinitis pigmentosa could also be caused by syphilis, old ophthalmic artery occlusion, uveitis, and drugs such as chloroquine and thioridazine.^[2] These acquired causes were not determined in this study. In particular, syphilis is known to give rise to "salt and pepper" fundus. None was recorded in this study and no patient had serologic tests for syphilis. Chloroquine, an anti-malarial drug, purchasable over-the-counter in Nigeria, is in common use in our environment. Chloroquine retinopathy had been reported among young adults in Nigeria.^[25,26] It should therefore be ruled out when evaluating patients for retinitis pigmentosa. A prospective study would expectedly address these and other limitations of this study.

Being a progressively degenerative condition, retinitis pigmentosa impacts negatively on both the quality of life and productivity of the afflicted. The degree of visual incapacitation is fivefold higher than in all ophthalmic patients^[5] and three times higher in elderly patients^[27] in the same hospital. In addition to visual acuity impairment, some patients had severe visual field defects. Visual impairment including blindness is a source of worry to both retinitis pigmentosa patients and their physicians. In this study, nearly 60% of the patients were visually impaired in their better eyes. This is lower than the 65.7%^[11] and 76.7%^[10] reported in previous studies in Nigeria. Nevertheless, it is gratifying that 37.8% of our patients had vision improvement with either simple refraction or with low vision aids. Provision of low vision aids will be an enabler for these patients to engage in economically productive ventures and for adolescents and young adults, it will be of immense importance in their educational pursuits. Furthermore, use of such aids will expectedly improve the vision-related quality of life of these patients.

Apart from low vision aids, it is important to also deliver targeted health education to the patients to enable them to actually understand the nature of the disease, its natural history, and relevant measures that will help minimize the untoward effects of the disease. Thus, the patients would be encouraged to maintain regular follow-up appointments of approximately one to two times a year; this will enable early detection and prompt treatment of other vision-threatening but treatable eye diseases such as cataract and glaucoma. Couching recorded in this study may be vicariously attributed to lack of access to orthodox eye care. Health education should also enable the patients adopt lifestyle changes such as not staying late in unfamiliar environment; avoiding dimly lit environment; requesting for a guide when crossing road; avoiding of smoking as well as refraining from ingesting retino-toxic and neurotoxic drugs such as chloroquine and thioridazine.

Most patients presented late with a median of 7 years from the symptom onset. However, this needs to be interpreted with caution. Retinitis pigmentosa has no definitive cure. Therefore it is conceivable that these patients had been to other health care facilities before eventually presenting in our hospital. Even in the absence of a definitive cure, low vision and hearing aids are of great benefits to such patients. Similarly, a previous study in our hospital showed that well-focused counseling help patients with chronic eye diseases cope with their condition.^[28] Therefore, repetitive health education and counseling will expectedly bring psychological stability and also help the patients cope with the chronic disorder. Low-vision service is imperative for these patients.

In conclusion, this study revealed that though the frequency rate of retinitis pigmentosa in our hospital is low, the associated visual and otologic incapacitation are enormous. There is a need for a prospective study to more exactly determine the inheritance pattern of retinitis pigmentosa in Nigeria; molecular genetic studies will unravel the common retinitis pigmentosa genes prevalent among Nigerians afflicted by the disease. Finally, it is recommended that eye clinics nationwide be equipped with the capability to test and provide low vision and hearing aids for these patients as a way of improving their quality of life and economic productivity.

Financial support and sponsorship

Nil.

Conflicts of interest

There are no conflicts of interest.

References

- Gregory-Evans K, Pennesi ME, Weleber RG. Retinitis pigmentosa and allied disorders. In: Ryan SJ (editor-in-chief), editor. Retina. Vol. 2. 5th ed. New York: Elsevier Saunders; 2013. p. 787-815.
- American Academy of Ophthalmology. Basic and Clinical Science Course: Section 12. Retina and Vitreous 2011–2012. San Francisco, CA: American Academy of Ophthalmology; 2011. p. 228-36.

3. Berson EL. Hereditary retinal diseases. In: Albert DM, Jakobiec FA, editors. Principles and Practice of Ophthalmology. Philadelphia, PA: Saunders; 1994. p. 1181-262.
4. Nwosu SNN. Prevalence and pattern of retinal diseases at the Guinness Eye Hospital Onitsha Nigeria. *Ophthalmic Epidemiol* 2000;7:41-8.
5. Nwosu SNN. Blindness and visual impairment in Anambra state, Nigeria. *Trop Geogr Med* 1994;46:346-9.
6. Ajibode HA. The prevalence of blindness and visual impairment in Ikenne Local Government Area of Ogun State, Nigeria. *Niger J Ophthalmol* 1999;7:23-7.
7. Ezegwui IR, Umeh RE, Ezepue UF. Causes of childhood blindness: Results from schools for the blind in South Eastern Nigeria. *Br J Ophthalmol* 2003;87:20-3.
8. Onakpoya OH, Adeoye AO, Akinsola FB, Adegbehingbe BO. Prevalence of blindness and visual impairment in Atakunmosa West local government area of southwestern Nigeria. *Tanzan Health Res Bull* 2007;9:126-31.
9. Abdull MM, Sivasubramaniam S, Murthy GV, Gilbert C, Abubakar T, Ezelum C, *et al.*; Nigeria National Blindness and Visual Impairment Study Group. Causes of blindness and visual impairment in Nigeria: The Nigeria National Blindness and Visual Impairment Survey. *Invest Ophthalmol Vis Sci* 2009;50:4114-20.
10. Ukponmwan CU, Atamah A. Retinitis pigmentosa in Benin, Nigeria. *East Afr Med J* 2004;81:254-7.
11. Onakpoya OH, Adeoti CO, Oluleye TS, Ajayi IA, Majengbasan T, Olorundare OK. Clinical presentation and visual status of retinitis pigmentosa patients: A multicenter study in southwestern Nigeria. *Clin Ophthalmol* 2016;10:1579-83.
12. Eballe AO, Koki G, Emche CB, Bella LA, Kouam JM, Melong J. Blindness and visual impairment in retinitis pigmentosa: A Cameroonian hospital-based study. *Clin Ophthalmol* 2010;4:661-5.
13. Oswald AH, Goldblatt J, Sampson G, Clokie R, Beighton P. Retinitis pigmentosa in South Africa. *S Afr Med J* 1985;68:863-6.
14. Al-Merjan JI, Pandova MG, Al-Ghanim M, Al-Wayel A, Al-Mutairi S. Registered blindness and low vision in Kuwait. *Ophthalmic Epidemiol* 2005;12:251-7.
15. Tsujikawa M, Wada Y, Sukegawa M, Sawa M, Gomi F, Nishida K, *et al.* Age at onset curves of retinitis pigmentosa. *Arch Ophthalmol* 2008;126:337-40.
16. Buch H, Vinding T, La Cour M, Appleyard M, Jensen GB, Nielsen NV. Prevalence and causes of visual impairment and blindness among 9980 Scandinavian adults: The Copenhagen city eye study. *Ophthalmology* 2004;111:53-61.
17. Abah ER, Oladigbolu KK, Samaila E, Merali H, Ahmed AO, Abubakar TH. Ophthalmologic abnormalities among deaf students in Kaduna, Northern Nigeria. *Ann Afr Med* 2011;10:29-33.
18. Chude EA, Nwosu SNN, Edema TO, Umezurike CN. Causes of visual loss in students attending schools for the blind in South-Eastern Nigeria. *Niger J Ophthalmol* 2018;28:46-50.
19. Lu Y, Sun X. Retinitis pigmentosa sine pigmento masqueraded as myopia: A case report. *Medicine* 2021;100:e24006.
20. Peng T, Wu L, Zhou W. Retinitis pigmentosa associated with glaucoma—clinical analysis. *Yan Ke Xue Bao* 1990;6:17-9.
21. Badeeb O, Trope G, Musarella M. Primary angle closure glaucoma and retinitis pigmentosa. *Acta Ophthalmol (Copenh)* 1993;71:727-32.
22. Greenberg J, Bartmann L, Ramesar R, Beighton P. Retinitis pigmentosa in southern Africa. *Clin Genet* 1993;44:232-5.
23. Ayuso C, Garcia-Sandoval B, Najera C, Valverde D, Carballo M, Antiñolo G. Retinitis pigmentosa in Spain. The Spanish multicentric and multidisciplinary group for research into retinitis pigmentosa. *Clin Genet* 1995;48:120-2.
24. Sun Y, Li W, Li JK, Wang ZS, Bei JY, Xu L, *et al.* Genetics and clinical findings of panel-based target exome sequencing in a northeast Chinese cohort with retinitis pigmentosa. *Mol Genet Genomic Med* 2020;8:e1184.
25. Magulike NO, Ihenacho HN, Ike VO. Chloroquine retinopathy in Nigerian patients with heart block. *Eye (Lond)* 1993;7:591-3.
26. Oluleye TS, Babalola Y, Ijaduola M. Chloroquine retinopathy: Pattern of presentation in Ibadan, Sub-Saharan Africa. *Eye* 2015;30:64-7.
27. Nwosu SNN, Onyekwe LO. Ocular problems of the elderly in Onitsha, Nigeria. *Niger J Clin Pract* 2002;5:123-6.
28. Ezenwa AC, Nwosu SNN. Self-reported quality of life among primary open angle glaucoma patients at Guinness Eye Centre Onitsha Nigeria. *Health Sci J* 2020;14:727.