

Original research

Open Access

## Risk of symptomatic heterotopic ossification following plate osteosynthesis in multiple trauma patients: an analysis in a level-I trauma centre

Christian Zeckey\*<sup>1</sup>, Frank Hildebrand<sup>1</sup>, Philipp Mommsen<sup>1</sup>,  
Julia Schumann<sup>1</sup>, Michael Frink<sup>1</sup>, Hans-Christoph Pape<sup>2</sup>, Christian Krettek<sup>1</sup>  
and Christian Probst<sup>1</sup>

Address: <sup>1</sup>Trauma Department, Hannover Medical School, Carl-Neuberg-Str.1, 30625 Hannover, Germany and <sup>2</sup>Trauma Department, University Hospital Aachen, Pauwelsstraße 30, 52074 Aachen, Germany

Email: Christian Zeckey\* - [Zeckey.christian@mh-hannover.de](mailto:Zeckey.christian@mh-hannover.de); Frank Hildebrand - [Mommsen.philipp@mh-hannover.de](mailto:Mommsen.philipp@mh-hannover.de);  
Philipp Mommsen - [Hildebrand.frank@mh-hannover.de](mailto:Hildebrand.frank@mh-hannover.de); Julia Schumann - [Schumann.julia@mh-hannover.de](mailto:Schumann.julia@mh-hannover.de);  
Michael Frink - [Frink.michael@mh-hannover.de](mailto:Frink.michael@mh-hannover.de); Hans-Christoph Pape - [unfallchirurgie@ukaachen.de](mailto:unfallchirurgie@ukaachen.de);  
Christian Krettek - [Krettek.christian@mh-hannover.de](mailto:Krettek.christian@mh-hannover.de); Christian Probst - [Probst.christian@mh-hannover.de](mailto:Probst.christian@mh-hannover.de)

\* Corresponding author

Published: 13 October 2009

Received: 6 May 2009

Scandinavian Journal of Trauma, Resuscitation and Emergency Medicine 2009, 17:55 doi:10.1186/1757-7241-17-55

Accepted: 13 October 2009

This article is available from: <http://www.sjtreem.com/content/17/1/55>

© 2009 Zeckey et al; licensee BioMed Central Ltd.

This is an Open Access article distributed under the terms of the Creative Commons Attribution License (<http://creativecommons.org/licenses/by/2.0>), which permits unrestricted use, distribution, and reproduction in any medium, provided the original work is properly cited.

### Abstract

**Background:** Symptomatic heterotopic ossification (HO) in multiple trauma patients may lead to follow up surgery, furthermore the long-term outcome can be restricted. Knowledge of the effect of surgical treatment on formation of symptomatic heterotopic ossification in polytrauma is sparse. Therefore, we test the effects of surgical treatment (plate osteosynthesis or intramedullary nailing) on the formation of heterotopic ossification in the multiple trauma patient.

**Methods:** We retrospectively analysed prospectively documented data of blunt multiple trauma patients with long bone fractures which were treated at our level-I trauma centre between 1997 and 2005. Patients were distributed to 2 groups: Patients treated by intramedullary nails (group IMN) or plate osteosynthesis (group PLATE) were compared. The expression and extension of symptomatic heterotopic ossifications on 3-6 months follow-up x-rays in antero-posterior (ap) and lateral views were classified radiologically and the maximum expansion was measured in millimeter (mm). Additionally, ventilation time, prophylactic medication like indomethacine and incidence and correlation of head injuries were analysed.

**Results:** 101 patients were included in our study, 79 men and 22 women. The fractures were treated by intramedullary nails (group IMN n = 50) or plate osteosynthesis (group PLATE n = 51). Significantly higher radiologic ossification classes were detected in group PLATE ( $2.9 \pm 1.3$ ) as compared to IMN ( $2.2 \pm 1.1$ ;  $p = 0.013$ ). HO size in mm ap and lateral showed a tendency towards larger HOs in the PLATE group. Additionally PLATE group showed a higher rate of articular fractures (63% vs. 28% in IMN) while IMN demonstrated a higher rate of diaphyseal fractures (72% vs. 37% in PLATE;  $p = 0.003$ ). Ventilation time, indomethacine and incidence of head injuries showed no significant difference between groups.

**Conclusion:** Fracture care with plate osteosynthesis in polytrauma patients is associated with larger formations of symptomatic heterotopic ossifications (HO) while intramedullary nailing was associated with a higher rate of remote HO. For future fracture care of multiply injured patients these facts may be considered by the responsible surgeon.

## Background

Heterotopic ossification (HO) after trauma still remains poorly understood. Hormonal as well as systemic and external factors are discussed to induce the HO [1-5]. Heterotopic ossification is described as a result of the inappropriate differentiation of pluripotential mesenchymal cells into osteoblastic cells influenced by local and systemic factors such as local presence of bone morphogenetic protein (BMP) or increased systemic expression of prostaglandine-E2 [6]. The newly formed bone has been found biologically highly active with high formation rates and high osteoclastic density [7].

Furthermore, this process is a systematic progression from osteoid to calcification within weeks and is mostly seen around the hip after internal fracture stabilisation or total hip arthroplasty [6]. Further studies showed the highest incidence of HO at the hip joints, followed by the knee [8], elbow [9] and shoulder [10]. Widely accepted complications due to HO are persistent pain and functional limitations [6]. Additionally, ankylosis is a well known problem and occurs in up to 25% of the patients [3,11,12].

Risk factors to sustain HO were classified by Ellerien in three main groups of individual injury, personal and therapeutic factors [13]. Subsequently several studies revealed the occurrence of HO in patients with severe head injury [14-16]. Furthermore, prolonged ventilation time is accepted as a contributing factor.

Since treatment of HO oftentimes is difficult and recurrence rates are high, prevention of HO became increasingly important [6]. As medical treatment, protective effects of indomethacine or selective cyclooxygenase (COX)-2 inhibitors could be shown [17-19].

However, besides the effects of head injury and mechanical ventilation, little is known about HO formation in acute trauma patients following operative fracture care treatment. Therefore we studied, if type of surgical fracture care affects HO formation in polytrauma patients.

## Methods

The study followed the guidelines of the revised UN declaration of Helsinki in 1975 and its latest amendment of 1996 (42nd general meeting). The population of our study includes 101 polytrauma patients with fractures of the long bones of either upper or lower extremity which were treated at our level-1 trauma centre between 1997 and 2005. Inclusion criteria were detected HO on x-rays (2 views) 3-6 months after trauma, 3-6 months follow-up, age between 16-65 years and ISS  $\geq$  16. Exclusion criteria were HO after arthroplasty, surgical treated spinal fractures as well as fractures of the ankle, foot, wrist and hand.

Patients were distributed to the following groups:

- 1.) Multiple trauma patient treated by intramedullary nails (group IMS)
- 2.) Multiple trauma patient treated by plate osteosynthesis (group PLATE)

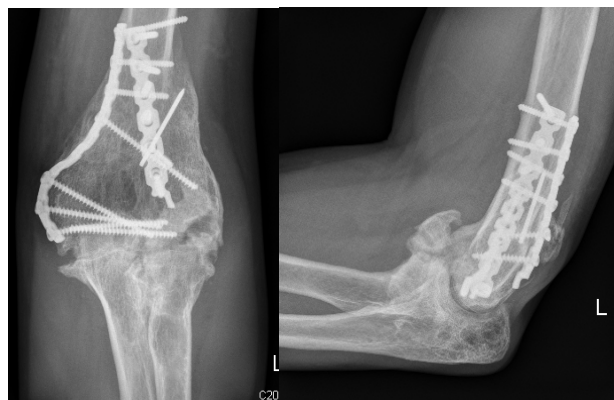## Scoring systems

To reveal trauma severity, the Injury Severity Score (ISS) [20,21] and the Abbreviated Injury Scale (AIS) [22] were used. The presence or absence of a head injury was classified by initial GCS and simultaneous CT-Scan abnormalities such as fractures of the skull or intra-cranial injuries. Patients with an almost normal to normal GCS and combined anatomical lesions on the CT-scan were classified as head injured patients.

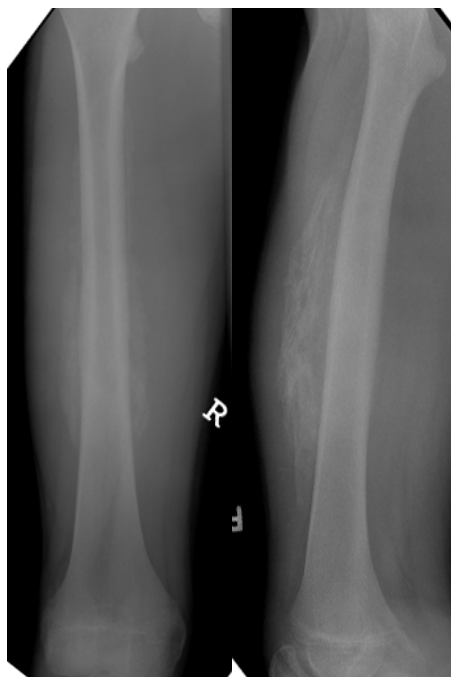## Analysis of the HO - clinical and diagnostic assessment

Patients with symptomatic HO at routine follow-up in our clinic were included in the present study. A great part of heterotopic ossifications cause swelling, pain or limited function to total ankylosis. Since these patients confront the clinician during every day work and utilize clinical resources, we focussed on these patients. We asked and examined the patients towards one or more of these symptoms and took x-rays of the affected body region in standardized antero-posterior and lateral views from the follow-up appointment three to six months after the initial injury for radiologic confirmation of suspected HO (figure 1, figure 2).

Today, Brooker's classification is widely accepted for classification of the HO around the hip joints, classifying HO into 4 grades ranging from just visible (grade 1) to total ankylosis (grade 4) in standardized x-rays in two planes



**Figure 1**  
**Heterotopic ossification following plate osteosynthesis of a distal humerus fracture.**



**Figure 2**  
**Heterotopic ossification remote to the fracture site at the contralateral femur.**

[23]. Unfortunately, a general and comparable classification system of all joints to date does not exist. We therefore adapted and modified Brooker's classification in a similar way to the other joints and defined the extent of the heterotopic ossification accordingly (grade 1-grade 4, in the following "radiologic ossification class"). Additionally, the maximum expansion on both films was measured in mm. Furthermore, the location at the fracture site (fractured long bone between the adjacent joints) or at a site remote to the fracture site (any non-adjacent part of an extremity) was noted. All the x-rays were analysed and classified by two independent trauma surgeons (J. S. and C. P.).

**Pharmacotherapy**

Patients were defined to receive prophylactic medications, if corticoids, non-steroidal anti-inflammatory drugs (NSAIDs), muscle relaxants, diphosphonates or hyaluronidases were administered in a prophylactic regimen.

**Operative treatment**

We defined surgical fracture if initially intramedullary nailing, plate osteosynthesis or external fixateurs with secondary conversion to intramedullary nailing (damage control orthopaedics, DCO) were used. No other methods of fracture care such as extension treatment or casting were used in our population.

**Intensive care treatment**

Ventilation time and duration of intensive care unit stay were analysed.

**Statistics**

Results are shown as mean ± standard error of the mean (SEM). For the analysis of nominal-scaled variables the Chi-squared test (Chi<sup>2</sup>) was used, for continuous data we used the student t-test. In addition, analysis of variances (ANOVA) was performed followed by post-hoc Tukey test to determine differences between groups. Level of significance was set at p < 0.05.

**Results**

**Demographic data**

The study population consisted of 79 men (78.7%) and 22 women (21.3%). Average age between groups showed no significant difference (IMN: 27.1 ± 3.1 vs. PLATE 29.1 ± 2.6 years, p = 0.25). The GCS mean value was also statistically comparable between groups (IMN: 10.7 ± 0.8; PLATE 11.0 ± 1.0; p = 0.93) as was the incidence of head injuries (IMN: 33% vs. PLATE: 24%; p = 0.36).

Additionally, PLATE group showed a higher rate of articular fractures (63% vs. 28% in IMN; p = 0.003) while IMN demonstrated a higher rate of diaphyseal fractures (72% vs. 37% in PLATE; p = 0.003).

Comparing the mean ISS, and AIS max there was no statistical difference between our groups (table 1).

**Table 1: AIS and ISS-values for the groups without significant differences.**

	IMN	PLATE
AIS head	3.3 ± 2.1	3.0 ± 1.4
AIS face/neck	1.6 ± 0.7	1.5 ± 0.6
AIS spine	3.7 ± 2.3	4.1 ± 2.0
AIS thorax	4.1 ± 2.8	3.6 ± 2.7
AIS abdomen	1.8 ± 0.7	2.1 ± 0.9
AIS upper extremity	2.2 ± 0.9	1.9 ± 0.7
AIS lower extremity	2.6 ± 0.8	2.3 ± 0.7
AIS max	4.6 ± 2.2	4.4 ± 1.9
ISS	44.3 ± 27.4	42.1 ± 25.0

**Incidence, size and localisation of HO**

A significantly higher incidence of radiologic classes 3 and 4 was found for the PLATE group in comparison to the IMN group ( $p = 0.04$ ; figure 3).

For the largest extension of the HO in mm in two views of plane x-rays the p-values show no significant difference but a tendency towards larger HO-formations in group PLATE (table 2).

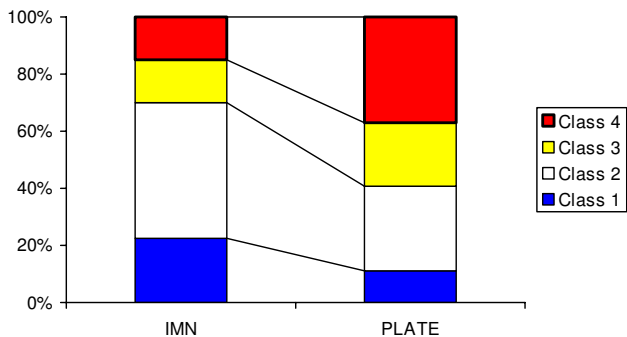
HO occurred significantly more frequently remote to the fracture site in the IMN group in comparison to the PLATE group ( $p = 0.03$ ; figure 4).

**Effect of ICU and medical treatment**

No differences of ventilation time (IMN:  $12.2 \pm 3.1$  days vs. PLATE:  $11.0 \pm 2.7$  days;  $p = 0.48$ ), duration of the ICU-stay (IMN:  $14.6 \pm 3.9$  days vs. PLATE:  $13.2 \pm 3.6$  days;  $p = 0.76$ ) and indomethacine prescribed (IMN: 22% vs. PLATE: 30%;  $p = 0.47$ ) was demonstrated.

**Discussion**

The formation of HO in trauma patients is critically discussed in the context of fracture healing. The role of severe head trauma was described in former studies [1,14,15,24]. Studies on the influence of multiple trauma in combination with severe head trauma were performed in our department [5,7] and confirmed the role of head injuries in polytrauma, too. In the present setting, we addressed the question of the impact of the applied surgical therapy of long bone fractures in polytrauma patients on the development of symptomatic HO. In the present setting, we specifically focussed on symptomatic HO. This is important due to the fact that only these patients are suffering from the HO. The patients included in our study are representative for patients suffering from the complaints following major trauma. The need for diagnostic and sometimes therapeutic interventions in these patients



**Figure 3**  
Percentage of patients with respective radiologic classes. PLATE patients showing significantly more Brooker values of 3 and 4.

**Table 2: Expression of the HO**

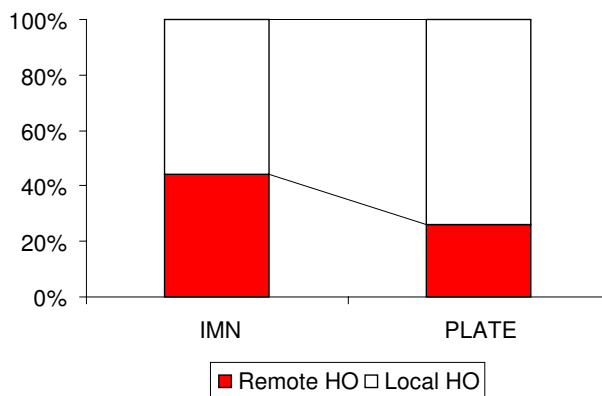
	IMN	PLATE	
a.p. (mm)	21 ± 2	26 ± 3	0.1337
lat. (mm)	16 ± 2	22 ± 5	0.1092

is crucial and towards symptomatic HO difficult. Therefore, we could not demonstrate an over-all incidence of heterotopic ossification. In our understanding, inapparent HO should not be treated and are to categorize as diagnostic findings by chance.

The present study is a retrospective single centre analysis of prospectively collected patient data. Demographic and injury related data of our patients are similar to those published before: Multiply injured patients commonly group around the age of 30 to 40 years with a predominance of males as do our patients. Overall injury severity and injury pattern are consistent with other cohorts [25]. Similarly, the GCS of our patients is comparable to data of other authors [26,27].

Furthermore, good comparison of patient groups seems possible because treatment strategy was very consistent in our centre over the inclusion period. Required data were documented completely for all of the individuals. Two independent examiners of the x-rays lead to similar results. Overall, we feel that our analysis safely leads to the following results:

- In polytrauma patients, plate osteosynthesis is followed by larger HO formations compared to intramedullary nailing.



**Figure 4**  
Percentages of remote and local HO. Significantly more remote HO in the IMN group compared to the PLATE group.

- Patients treated with intramedullary nails more commonly showed HO formations remote to the fracture site.

Nonetheless, there are some limitations to our study. Heterotopic ossifications were essentially described by Brooker et al. This classification system includes the HO around the hip joint and is now widely accepted for classification following acetabular fracture treatment and arthroplasty of the hip. To classify the functional status of the hip joint, the Harris score is widely known. Further classifications were developed for the elbow, this score is divided into radiologic and functional aspects [28]. Since there is no general classification system for all the joints, we transferred the Brooker criteria for the four different classes accordingly to the large joints of the extremities.

#### **Effects of injury pattern**

The role of head injuries in the formation of HO still is lively debated about in the literature. Some authors reported a stimulation of fracture healing in patients with head injuries [29-31]. Furthermore, a positive correlation of the severity of the head injury and the HO rate was observed [24]. Other studies could not confirm a relationship between severe head trauma and HO formation. Lehmann et al. demonstrated constant expressions of the HO in multiply injured patients without head trauma in comparison to multiply injured patients with severe head trauma [4]. We could confirm the findings of Lehmann et al., the present report could demonstrate comparable GCS and constant incidence of head trauma in both groups.

Interestingly, a recent study demonstrated differences in the location of the HO between polytrauma patients with and without severe head trauma. In polytrauma patients with associated head trauma, the HO was located adjacent to the fracture region. In polytrauma patients without head injury, the HO formation more frequently occurred at sites remote to the actual fracture sites [7]. In our study, the incidence and severity of head injuries was distributed equally between both groups.

Nonetheless, we found a higher incidence of remote HO in the IMN group, leading to the idea of systemic factors liberated during nailing that affect HO formation such as prostaglandin E2 [1,3,32].

#### **Effects of treatment strategy**

Surgical treatment such as osteosynthesis, manipulation at joints or traumatic haematoma is known to be a risk factor for the development of the HO [6,33,34]. In the present study, we could demonstrate a positive association of plate osteosynthesis and the development of the HO in the PLATE group.

A more invasive approach required for plate osteosynthesis is well described as one of the risk factors [6]. Local

fracture and soft tissue manipulation is believed to hold a substantial role in the development of the HO, possibly by the liberation of bone morphogenetic protein (BMP) or other tissue factors [35,36]. Home et al reported on extended HO after intramedullary nailing in combination with severe head trauma [37]. However, these results could not be shown in our study potentially due to a relatively low patient number.

#### **Effects of additional therapy**

In the present study, there were no significant differences in ventilation time (IMN:  $12.2 \pm 3.1$  days vs. PLATE:  $11.0 \pm 2.7$  days;  $p = 0.48$ ). Long term ventilation is widely accepted as a factor associated with HO formation [2]: One study showed HO in patients after pulmonary transplantation with prolonged ventilation times at healthy joints [38]. Mechanical ventilation may lead to changes in the acid-base metabolism which results in mineral accumulation in the soft tissues and therefore may lead to HO formation [5] which was also demonstrated in an experimental study [34]. Other authors speculate that HO formation in shock trauma patients and mechanically ventilated patients occurs due to critical hypoxia in consequence to local tissue compression. It could be revealed that osteogenesis is induced by low oxygen concentrations [33].

#### **Effects of prophylactic medication**

Prophylactic medications to prevent or to decrease HO are widely discussed in hip and acetabular surgery. Moreover, several studies revealed the effectiveness of prophylactic treatment after knee arthroplasty [18,19,39]. Prophylactic strategies may lead to decrease the development and the resulting size of the HO; these strategies include treatment with NSAID or postoperative radiotherapy. Best evidence for prophylactic medication is shown for indomethacine for at least 7 days, other NSAIDs are also well documented [19]. To our knowledge, there are no reports on the effect of prophylactic medication on HO formation in multiple trauma patients. In our study, up to 30% (group PLATE) of the patients received prophylactic medications, there were no differences of NSAIDs prescribed (IMN: 22% vs. PLATE: 30%;  $p = 0.47$ ).

The missing effect of the prophylactic treatment in our study may be the result of the low fraction of patients who received prophylactic treatment. On the other hand, HO formation in multiply injured patients may result out of interactions of multiple systemic and local factors, thereby limiting the effect of a single intervention or substance.

#### **Conclusion**

We demonstrate that fracture care by plate osteosynthesis in multiple trauma patients is significantly associated with the formation of symptomatic heterotopic ossifications.

We also found intramedullary nails being associated with a higher incidence of HO remote to the fracture site. Since HO was shown to lead to considerable long term complaints, our results may serve clinicians to critically verify their strategies for acute fracture care in multiple trauma patients to prevent future HO formation. However, the individual therapeutic approach has to be subject to the patient's status.

### Competing interests

*Financial competing interests:*

The author(s) declare that they have no competing interests

*Non-financial competing interests:*

There are no non-financial competing interests (political, personal, religious, ideological, academic, intellectual, commercial or any other) to declare in relation to this manuscript.

### Authors' contributions

CZ performed data analysis and interpretation and drafted the manuscript. FH interpreted data and helped drafting the manuscript. PM carried out data analysis. JS has made substantial contributions to acquisition of data. MF participated in data analysis and interpretation. HCP made substantial contributions to conception and design of the study. CK made substantial contributions to conception of the study. CP performed statistical analysis and helped to draft the manuscript. All authors read and approved the final manuscript.

### References

1. Bidner SM, Rubins IM, Desjardins JV, Zukor DJ, Goltzman D: **Evidence for a humoral mechanism for enhanced osteogenesis after head injury.** *J Bone Joint Surg Am* 1990, **72**:1144-1149.
2. Dellestable F, Voltz C, Mariot J, Perrier JF, Gaucher A: **Heterotopic ossification complicating long-term sedation.** *British journal of rheumatology* 1996, **35**:700-701.
3. Garland DE: **Clinical observations on fractures and heterotopic ossification in the spinal cord and traumatic brain injured populations.** *Clinical orthopaedics and related research* 1988:86-101.
4. Lehmann U, Pape HC, Seekamp A, Gobiet W, Zech S, Winny M, Molitoris U, Regel G: **Long term results after multiple injuries including severe head injury.** *The European journal of surgery = Acta chirurgica* 1999, **165**:1116-1120.
5. Pape HC, Marsh S, Morley JR, Krettek C, Giannoudis PV: **Current concepts in the development of heterotopic ossification.** *The Journal of bone and joint surgery* 2004, **86**:783-787.
6. Balboni TA, Gobeze R, Mamon HJ: **Heterotopic ossification: Pathophysiology, clinical features, and the role of radiotherapy for prophylaxis.** *International journal of radiation oncology, biology, physics* 2006, **65**:1289-1299.
7. Pape HC, Lehmann U, van Griensven M, Gansslen A, von Glinski S, Krettek C: **Heterotopic ossifications in patients after severe blunt trauma with and without head trauma: incidence and patterns of distribution.** *Journal of orthopaedic trauma* 2001, **15**:229-237.

8. Toyoda T, Matsumoto H, Tsuji T, Kinouchi J, Fujikawa K: **Heterotopic ossification after total knee arthroplasty.** *The Journal of arthroplasty* 2003, **18**:760-764.
9. Martin BD, Johansen JA, Edwards SG: **Complications related to simple dislocations of the elbow.** *Hand clinics* 2008, **24**:9-25.
10. Sperling JW, Cofield RH, Rowland CM: **Heterotopic ossification after total shoulder arthroplasty.** *The Journal of arthroplasty* 2000, **15**:179-182.
11. Garland DE: **A clinical perspective on common forms of acquired heterotopic ossification.** *Clinical orthopaedics and related research* 1991:13-29.
12. Garland DE, Hanscom DA, Keenan MA, Smith C, Moore T: **Resection of heterotopic ossification in the adult with head trauma.** *J Bone Joint Surg Am* 1985, **67**:1261-1269.
13. Ellerin BE, Helfet D, Parikh S, Hotchkiss RN, Levin N, Nisce L, Nori D, Moni J: **Current therapy in the management of heterotopic ossification of the elbow: a review with case studies.** *American journal of physical medicine & rehabilitation/Association of Academic Physiatrists* 1999, **78**:259-271.
14. Andermahr J, Elsner A, Brings AE, Hensler T, Gerbershagen H, Jubel A: **Reduced collagen degradation in polytraumas with traumatic brain injury causes enhanced osteogenesis.** *Journal of neurotrauma* 2006, **23**:708-720.
15. Hendricks HT, Geurts AC, van Ginneken BC, Heeren AJ, Vos PE: **Brain injury severity and autonomic dysregulation accurately predict heterotopic ossification in patients with traumatic brain injury.** *Clinical rehabilitation* 2007, **21**:545-553.
16. Chalidis B, Stengel D, Giannoudis PV: **Early excision and late excision of heterotopic ossification after traumatic brain injury are equivalent: a systematic review of the literature.** *Journal of neurotrauma* 2007, **24**:1675-1686.
17. Macfarlane RJ, Ng BH, Gamie Z, El Masry MA, Velonis S, Schizas C, Tsiridis E: **Pharmacological treatment of heterotopic ossification following hip and acetabular surgery.** *Expert opinion on pharmacotherapy* 2008, **9**:767-786.
18. Karunakar MA, Sen A, Bosse MJ, Sims SH, Goulet JA, Kellam JF: **Indometacin as prophylaxis for heterotopic ossification after the operative treatment of fractures of the acetabulum.** *The Journal of bone and joint surgery* 2006, **88**:1613-1617.
19. Fijn R, Koorevaar RT, Brouwers JR: **Prevention of heterotopic ossification after total hip replacement with NSAIDs.** *Pharm World Sci* 2003, **25**:138-145.
20. Baker SP, O'Neill B: **The injury severity score: an update.** *The Journal of trauma* 1976, **16**:882-885.
21. Baker SP, O'Neill B, Haddon W Jr, Long WB: **The injury severity score: a method for describing patients with multiple injuries and evaluating emergency care.** *The Journal of trauma* 1974, **14**:187-196.
22. Garthe E, States JD, Mango NK: **Abbreviated injury scale unification: the case for a unified injury system for global use.** *The Journal of trauma* 1999, **47**:309-323.
23. Brooker AF, Bowerman JW, Robinson RA, Riley LH Jr: **Ectopic ossification following total hip replacement. Incidence and a method of classification.** *J Bone Joint Surg Am* 1973, **55**:1629-1632.
24. Simonsen LL, Sonne-Holm S, Krashennikoff M, Engberg AVV: **Symptomatic heterotopic ossification after very severe traumatic brain injury in 114 patients: incidence and risk factors.** *Injury* 2007, **38**:1146-1150.
25. Nast-Kolb D, Aufmkolk M, Rucholtz S, Obertacke U, Waydhas C: **Multiple organ failure still a major cause of morbidity but not mortality in blunt multiple trauma.** *The Journal of trauma* 2001, **51**:835-841. discussion 841-832
26. Norwood SH, McAuley CE, Berne JD, Vallina VL, Creath RG, McLarty J: **A prehospital glasgow coma scale score < or = 14 accurately predicts the need for full trauma team activation and patient hospitalization after motor vehicle collisions.** *The Journal of trauma* 2002, **53**:503-507.
27. Pal J, Brown R, Fleischer D: **The value of the Glasgow Coma Scale and Injury Severity Score: predicting outcome in multiple trauma patients with head injury.** *The Journal of trauma* 1989, **29**:746-748.
28. Casavant AM, Hastings H 2nd: **Heterotopic ossification about the elbow: a therapist's guide to evaluation and management.** *J Hand Ther* 2006, **19**:255-266.
29. Smith R: **Head injury, fracture healing and callus.** *The Journal of bone and joint surgery* 1987, **69**:518-520.

30. Morley J, Marsh S, Drakoulakis E, Pape HC, Giannoudis PV: **Does traumatic brain injury result in accelerated fracture healing?** *Injury* 2005, **36**:363-368.
31. Spencer RF: **The effect of head injury on fracture healing. A quantitative assessment.** *The Journal of bone and joint surgery* 1987, **69**:525-528.
32. Mital MA, Garber JE, Stinson JT: **Ectopic bone formation in children and adolescents with head injuries: its management.** *Journal of pediatric orthopedics* 1987, **7**:83-90.
33. Brighton CT, Krebs AG: **Oxygen tension of healing fractures in the rabbit.** *J Bone Joint Surg Am* 1972, **54**:323-332.
34. Brighton CT, Schaffer JL, Shapiro DB, Tang JJ, Clark CC: **Proliferation and macromolecular synthesis by rat calvarial bone cells grown in various oxygen tensions.** *J Orthop Res* 1991, **9**:847-854.
35. Michelsson JE, Granroth G, Andersson LC: **Myositis ossificans following forcible manipulation of the leg. A rabbit model for the study of heterotopic bone formation.** *J Bone Joint Surg Am* 1980, **62**:811-815.
36. Michelsson JE, Rauschnig W: **Pathogenesis of experimental heterotopic bone formation following temporary forcible exercising of immobilized limbs.** *Clinical orthopaedics and related research* 1983:265-272.
37. Horne LT, Blue BA: **Intraarticular heterotopic ossification in the knee following intramedullary nailing of the fractured femur using a retrograde method.** *Journal of orthopaedic trauma* 1999, **13**:385-388.
38. Schulze M, Lobenhoffer HP: **[Heterotopic ossifications of 5 large body joints after 105 days of intensive care with 72 days of artificial ventilation].** *Der Unfallchirurg* 1997, **100**:839-844.
39. Board TN, Karva A, Board RE, Gambhir AK, Porter ML: **The prophylaxis and treatment of heterotopic ossification following lower limb arthroplasty.** *The Journal of bone and joint surgery* 2007, **89**:434-440.

Publish with **BioMed Central** and every scientist can read your work free of charge

"BioMed Central will be the most significant development for disseminating the results of biomedical research in our lifetime."

Sir Paul Nurse, Cancer Research UK

Your research papers will be:

- available free of charge to the entire biomedical community
- peer reviewed and published immediately upon acceptance
- cited in PubMed and archived on PubMed Central
- yours — you keep the copyright

Submit your manuscript here:  
[http://www.biomedcentral.com/info/publishing\\_adv.asp](http://www.biomedcentral.com/info/publishing_adv.asp)

