

Potential factors influencing the development of oral tongue squamous cell carcinoma in young mature patients: Lingual position of the mandibular second molar and narrow tongue space

YUSOON KIM¹, KOHEI OKUYAMA², YASUYUKI MICHI¹,
YOSHIO OHYAMA¹, NARIKAZU UZAWA¹ and SATOSHI YAMAGUCHI¹

¹Section of Maxillofacial Surgery, Department of Maxillofacial and Neck Reconstruction, Graduate School of Medical and Dental Sciences, Tokyo Medical and Dental University, Tokyo 113-8549; ²Department of Clinical Oral Oncology, Unit of Translational Medicine, Course of Medical and Dental Sciences, Nagasaki University Graduate School of Biomedical Sciences, Nagasaki University, Nagasaki 852-8588, Japan

Received February 15, 2017; Accepted August 23, 2017

DOI: 10.3892/ol.2017.7135

Abstract. The lingual position of the mandibular second molar and narrow tongue space are associated with oral tongue squamous cell carcinoma (OTSCC) development in young mature patients. The present study aimed to assess the role of the mandibular second molar position and tongue space in young mature patients with OTSCC. The medical records of 21 patients with OTSCC aged <50 years, who had an intact mandibular second molar and had undergone computed tomography (CT) imaging between April 2009 and December 2015 at the Section of Maxillofacial Surgery in Tokyo Medical and Dental University, were retrospectively examined. As controls, 21 sex-matched patients of a similar age to the patients in the OTSCC group, and with a height and weight within 5% of those of the OTSCC group, were collected. The location of the mandibular second molar on the affected side and area of the tongue space were determined using coronal and axial CT images. Mann-Whitney U test analysis revealed that the location of the mandibular second molar and the area of the tongue space differed significantly between young mature patients with OTSCC and the controls. The present study thus revealed that the lingual position of the mandibular second molar and the narrow tongue space may be potential factors influencing OTSCC development in young maturity.

Introduction

Multiple clinical studies have reported on the factors involved in the development of oral tongue squamous cell carcinoma (OTSCC), which include unsuitable tooth fillings or prosthesis placement, smoking, alcohol consumption, inflammation, precancerous lesions such as leukoplakia, infection, endocrine disease, poor oral hygiene and heredity (1-4). Fan *et al* (2) revealed that mechanical trauma and galvanic phenomena, as a result of dental prosthesis placement, may also have a major role in the etiology of OTSCC (2), whereas Hougeir *et al* (5) demonstrated that contact allergy to metal dental restorations is a risk factor for OTSCC development (5). However, in young and young mature patients, the duration of such damage or exposure is short; hence, these factors cannot be considered. The broad factors involved in OTSCC development, including chemical and epigenetic causes, appear to be less applicable to young mature patients than to older patients (6). The present study hypothesized that the lingual position of the mandibular second molars, which are affected by features such as excessive lingual inclination, may serve as a potential factor for the development of OTSCC in young mature patients. Based on the clinical experience of the authors, the excessive lingual inclination across an extended period may be potentially associated with the development of OTSCC. This chronic damage to the surface of the tongue mucosa by a lingualized mandibular second molar may induce malignant transformation (7).

OTSCC in young mature patients is associated with particularly high rates of regional and distant metastases; recurrence is more aggressive, with a higher fatality rate in such cases (8-16). Thus, detailed examination of the position of the mandibular molars may indirectly aid reduction of the risk of developing OTSCC in young mature patients. In addition to determination of the position of the mandibular second molars, the tongue space is vital to ensuring a thorough and accurate evaluation. The present study measured these two parameters using computed tomography (CT), establishing an association between the position of the mandibular second

Correspondence to: Dr Yasuyuki Michi, Section of Maxillofacial Surgery, Department of Maxillofacial and Neck Reconstruction, Graduate School of Medical and Dental Sciences, Tokyo Medical and Dental University, 1-5-45 Yushima, Bunkyo, Tokyo 113-8549, Japan
E-mail: y-mic.mfs@tmd.ac.jp

Abbreviations: OTSCC, oral tongue squamous cell carcinoma; CT, computed tomography

Key words: oral tongue squamous cell carcinoma, young mature patients, mandibular second molar, tongue space, computed tomography

molar and the tongue space with the development of OTSCC in young mature patients. A comparison of the position of the mandibular second molar on the healthy side and on the affected side in young mature patients with OTSCC was also performed.

Materials and methods

Patients. A total of 21 patients with OTSCC with an intact mandibular second molar on the affected side of the tongue were included in the present study; the medical records of these 21 patients with OTSCC aged <50 years, who had undergone coronal and axial CT prior to glossectomy (along with neck dissection in certain cases) between April 2009 and December 2015 at the Section of Maxillofacial Surgery in Tokyo Medical and Dental University, were retrospectively examined. In the present study, patients aged <50 years were considered to be ‘young mature patients’, as the mean age at diagnosis of OTSCC is reportedly 60 years (2). With regard to the control group, 21 sex-matched patients with oral diseases, such as mandibular cysts, ranulas, submandibular gland salivolithiasis, and maxillary gingival carcinoma, with a similar age to that of the OTSCC group, and with height and weight within 5% of the value of the OTSCC group were included. None of the 42 patients had any prosthesis placement, including metal inlays, metal onlays, full metal crowns, bridges and prosthetics, periodontal or endodontic disease in the mandibular second molars, or endocrine disease, such as diabetes mellitus. The medical charts of the 21 patients with OTSCC and the 21 control patients, including the sex, age, and tumor-node-metastasis classification of the tumor according to the Union for International Cancer Control (17), were examined (Table I). The present study was retrospective and followed the Declaration of Helsinki on ethics, and the regional Ethical Review Board of Tokyo Medical and Dental University (Tokyo, Japan) approved the study.

Evaluation of OTSCC status. To evaluate the position of the mandibular second molar, the angular inclination was measured. The angle of the mandibular second molar on the affected side, against the tangential line connecting the inferior borders of the bilateral mandibular bone on coronal CT imaging (termed θ ; Fig. 1), was also measured. The lingual point of the mandibular second molar on the affected side was determined as being the tangential point of the perpendicular line against the tangential line that connected the inferior borders of the bilateral mandibular bone. The angles of the mandibular second molars in the healthy side and the affected side in each of the 21 young adult patients with OTSCC were also compared (Fig. 2). The measurement side of the control group was the same side as that of the OTSCC group in each matched patient.

In addition, the tongue-space (S) was estimated as being the area of the rectangle formed by the lingual edge of the bilateral posterior corners of the mandibular second molars and around the center of the lingual side of the first premolars on axial CT images. The two vertices on the first premolars were determined along a line parallel to the two lingual edges of the bilateral posterior corners of the mandibular second molars, which passed along the bilateral first premolars (Fig. 1). The

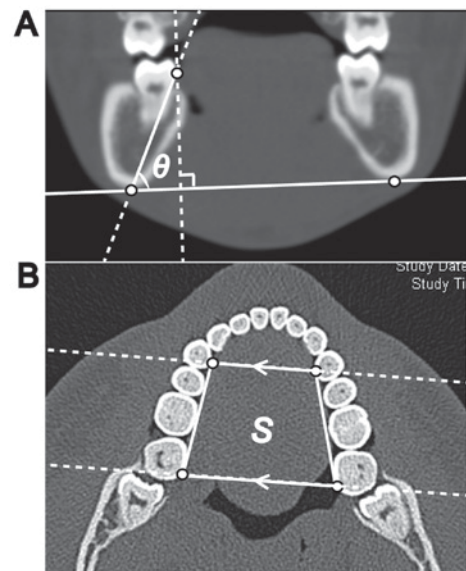


Figure 1. Measurement methods for the θ and S values. (A) The position of the mandibular second molar on the affected side is represented by the angle θ , formed against the straight line connecting two tangential points along the inferior borders of the bilateral mandibular bone. The lingual contact point on the mandibular second molar is present on the line perpendicular to the inferior border of the bilateral mandibular bone on coronal CT images. Each data point is obtained through measurements taken from the same coronal CT image. (B) S represents the area of the trapezoid, formed by the lingual edges of the bilateral posterior corners of the mandibular second molars and the center of the lingual side of the first premolars on axial CT images. The two vertices on the first premolars are the intersection points of a line parallel to the lower line along the two lingual edges of the bilateral posterior corners of the mandibular second molars, which passes through the center of the lingual side of the bilateral first premolars. The slice height on the axial CT images was determined as being half of the crown height of the bilateral mandibular second molars. CT, computed tomography.

slice height of the axial CT image was determined as being half that of the crown height of the mandibular second molar on the affected side. The corresponding pairs of data points are presented in Table I.

Statistical analysis. All statistical analyses were conducted using SPSS for Windows version 19.0 (IBM Corp., Armonk, NY, USA). In addition, the distributions of θ and S values in patients with OTSCC and in control patients were analyzed using the Mann-Whitney U test (Fig. 3A and B). $P < 0.05$ was considered to indicate a statistically significant difference.

Results

The median age of the 21 young mature patients with OTSCC (8 females and 13 males) was 43 years (range, 29–49 years). The OTSCC lesion appeared to be in contact with the lingual side of the mandibular second molar in all cases. With regard to the clinical classification of the tumors, 52.4% of lesions were classified as T1, 28.6% were classified as T2, 9.5% were classified as T3, 4.8% were classified as T4 and 4.8% were classified as T-is (Table I). The median angle on the affected side was 71.3° in females (range, 56.0–79.3°) and 62.7° in males (range, 54.5–79.5°) of the OTSCC group, and was 71.7° in females (range, 57.9–80.7°) and 69.5° in males (range, 56.9–76.8°) of the control group (Table I). If the lingual position of the

Table I. Clinical characteristics, including θ and S values, of the 21 young mature patients with OTSCC and 21 control patients.

Patient no.	Group	Age, years/sex	TNM classification/Diagnosis on control patients	θ , °	S , mm ²
1	OTSCC	29/Male	T3N2bM0	62.7	10.9
	Control	29/Male	Ranula	70.8	10.9
2	OTSCC	38/Male	T1N0M0	59.3	10.3
	Control	38/Male	Mandibular cyst	75.4	12.3
3	OTSCC	35/Male	T1N0M0	54.5	10.8
	Control	35/Male	Submandibular gland sialolithiasis	64.5	11.7
4	OTSCC	45/Male	T4N2bM0	65.8	9.8
	Control	45/Male	Mandibular cyst	70.3	11.1
5	OTSCC	43/Male	T1N0M0	62.2	9.4
	Control	43/Male	Mandibular cyst	66.2	12.4
6	OTSCC	43/Male	T1N0M0	64.1	10.2
	Control	43/Male	Mandibular tumor	57.2	11.5
7	OTSCC	33/Male	T2N0M0	58.7	10.9
	Control	33/Male	Mandibular tumor	74.9	11.6
8	OTSCC	34/Male	T2N0M0	75.5	10.6
	Control	34/Male	Submandibular gland sialolithiasis	74.1	11.0
9	OTSCC	47/Male	T2N0M0	63.3	10.1
	Control	47/Male	Mandibular cyst	67.8	12.6
10	OTSCC	46/Male	T1N0M0	59.3	10.9
	Control	46/Male	Mandibular cyst	68.2	11.8
11	OTSCC	38/Male	T1N0M0	63.1	8.7
	Control	38/Male	Mandibular cyst	69.5	12.1
12	OTSCC	36/Male	T2N0M0	79.5	10.7
	Control	36/Male	Maxillary gingival carcinoma	76.8	10.9
13	OTSCC	37/Male	T3N0M0	59.6	10.0
	Control	37/Male	Mandibular tumor	56.9	10.2
14	OTSCC	42/Female	T1N0M0	56.0	12.3
	Control	42/Female	Mandibular cyst	63.8	12.5
15	OTSCC	48/Female	T1N0M0	73.9	9.0
	Control	48/Female	Submandibular gland sialolithiasis	70.1	11.1
16	OTSCC	43/Female	T1N0M0	71.5	10.1
	Control	43/Female	Mandibular tumor	80.7	12.1
17	OTSCC	49/Female	TisN0M0	61.8	10.1
	Control	49/Female	Mandibular tumor	57.9	11.2
18	OTSCC	43/Female	T1N0M0	73.2	11.2
	Control	43/Female	Mandibular cyst	72.2	12.8
19	OTSCC	47/Female	T2N0M0	62.9	9.4
	Control	47/Female	Radicular cyst	72.3	10.3
20	OTSCC	38/Female	T1N0M0	79.3	10.8
	Control	38/Female	Mandibular tumor	71.2	10.8
21	OTSCC	31/Female	T2N0M0	71.1	10.0
	Control	31/Female	Mandibular cyst	78.6	11.2

θ , angle of the mandibular second molar on the affected side against the tangential line connecting the inferior borders of the bilateral mandibular bone; S , area of the tongue space; OTSCC, oral tongue squamous cell carcinoma; TNM, tumor-node-metastasis.

mandibular second molar were critical for developing OTSCC, the θ value on the affected side would be lower than that on the healthy side. Fig. 2 depicts scatter plots for the association between the θ value on the healthy side and the affected side in the 21 patients with OTSCC. The θ value on the affected side

in 14 patients with OTSCC (66.7%) was lower than that in the other 7 patients with OTSCC, thus supporting the aforementioned reasoning.

Furthermore, Mann-Whitney U test analysis confirmed the presence of a significant difference in the distributions

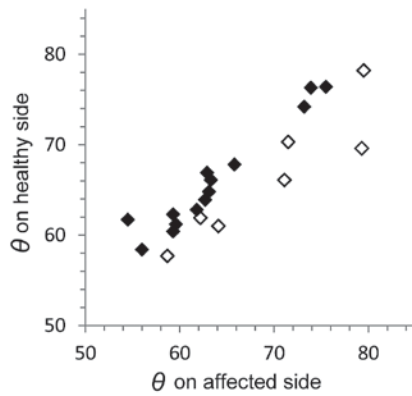


Figure 2. Scatter plot indicating θ on the healthy side vs. the affected side in 21 young mature patients with OTSCC. In the scatter plots, the rhombus indicates the data points of θ values for the affected side and healthy side in 21 young mature patients with OTSCC. The black rhombus indicates that θ values for the affected side are lower than those for healthy side. The white rhombus indicates the opposite result. In total, 14 young mature patients with OTSCC exhibited lower θ values on the affected side. θ , the angle of the mandibular second molar on the affected side against the tangential line connecting the inferior borders of the bilateral mandibular bone; OTSCC, oral tongue squamous cell carcinoma.

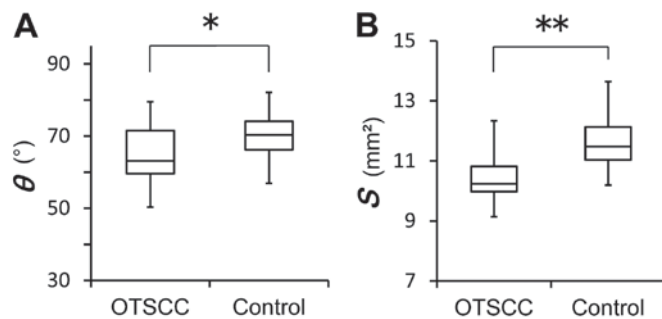


Figure 3. Results of the Mann-Whitney U test for the distribution of the θ and S values in 21 young mature patients with OTSCC and 21 control patients. (A) Significant difference is observed for the distribution of θ and S values between these two groups. * $P=0.016$ and ** $P<0.001$; θ and S values in young mature group vs. control group, respectively. θ , angle of the mandibular second molar on the affected side against the tangential line connecting the inferior borders of the bilateral mandibular bone; S , area of the tongue space; OTSCC, oral tongue squamous cell carcinoma.

of θ and S values between the OTSCC and control patients ($P=0.016$ and $P<0.001$, respectively; Fig. 3A and B).

The number of young maturities with OTSCC who habitually consumed alcohol was 3 (14.3%), the number who smoked daily was 6 (28.6%) and the number who regularly consumed both alcohol and smoked daily was 6 (28.6%). The number of control patients who habitually consumed alcohol was 8 (38.1%), the number who smoked daily was 8 (38.1%) and the number who regularly consumed alcohol and smoked daily was 6 (28.6%).

Discussion

OTSCC is an uncommon malignancy among the young mature generation (18-20). Thus far, no reports have examined the association between the findings of physical examination of teeth position and the development of OTSCC, to the best

of our knowledge. The present study aimed to evaluate the association between the development of OTSCC in young maturities and the mandibular second molar position and tongue space using coronal and axial CT images. Previous studies have identified various risk factors for OTSCC, including age, smoking status, alcohol consumption and human papilloma virus infection (2,21-24). Furthermore, nutritional deficiency and poor oral hygiene with misaligned dentition have also been identified as causative factors (25-27). A number of prior studies have also examined associations between dental prostheses, including metal crowns, bridges and prostheses, and the development of OTSCC (2,28-30). Hougeir *et al* (5) proposed that an oral metal-contact allergy was a factor that influenced the development of OTSCC. The 21 young mature patients with OTSCC in the present study had no metal prostheses in or around the mandibular second molar; hence, oral metal-contact allergy and poor prostheses were not considered suitable risk factors for the patients in the present study. However, the presence of oral galvanism, as proposed by Fan *et al* (2), cannot be completely ruled out. In addition, the present study could not exclude the presence of pre-existing dysplasia or cancer.

As predicted, the majority of young mature patients with OTSCC had a lower θ value on the affected side than on the healthy side. A lower θ value was associated with a more lingual position of the mandibular second molar, which would consequently lead to a smaller S value. Thus, the development of OTSCC in young mature patients was not only influenced by the lingual position of the mandibular second molar, but also by the narrow tongue space; the significant difference of the distributions of θ and S values between young mature patients with OTSCC and control patients supports this. No microglossia was observed in the 21 young mature patients with OTSCC; the 21 OTSCCs were in contact with or compressed by the lingualized mandibular molars. The significant difference in the tongue space noted in the present study also supports this reasoning.

Findings from the present study also revealed that alcohol consumption and smoking status may not be directly associated with OTSCC development in young maturities. The data suggest that these factors may not influence OTSCC development in young mature patients. However, the role of alcohol consumption and smoking in OTSCC development cannot be excluded, due to the limited cohort size of the present study.

Based on the findings of the present study, orthodontic treatment in young mature patients, particularly that involving bilateral molar-distance extension and tongue-space widening, would be suitable for excluding one of the factors of OTSCC development.

To conclude, the present study assessed the association between the position of the intact mandibular second molar and the development of OTSCC in young mature patients. The angle of the mandibular second molar and the area of the tongue space were measured using coronal and axial CT images. Mann-Whitney U test analysis indicated that the angle of the mandibular second molar and the tongue-space area differed significantly between young mature patients with OTSCC and matched controls. The angle of the mandibular second molar on the affected side in 66.7% of young mature

patients with OTSCC was lower than that on the healthy side. Although there are several factors that may have a role in OTSCC development in young mature patients, the position of the mandibular second molar and tongue space may be a substantial contributor.

References

- Lissowska J, Pilarska A, Pilarski P, Samolczyk-Wanyura D, Piekarczyk J, Bardin-Mikołajczak A, Zatonski W, Herrero R, Munoz N and Franceschi S: Smoking, alcohol, diet, dentition and sexual practices in the epidemiology of oral cancer in Poland. *Eur J Cancer Prev* 12: 25-33, 2003.
- Fan H, Yoon KY, Kim SM, Myoung H, Lee JH and Kim MJ: Relationship between squamous cell carcinoma of the tongue and the position of dental prosthesis. *J Adv Prosthodont* 7: 129-137, 2015.
- Zafereo ME, Xu L, Dahlstrom KR, Viamonte CA, El-Naggar AK, Wei Q, Li G and Sturgis EM: Squamous cell carcinoma of the oral cavity often overexpresses p16 but is rarely driven by human papillomavirus. *Oral Oncol* 56: 47-53, 2016.
- Amagasa T, Yamashiro M and Uzawa N: Oral premalignant lesions: From a clinical perspective. *Int J Clin Oncol* 16: 5-14, 2011.
- Hougeir FG, Yiannias JA, Hinni ML, Hentz JG and el-Azhary RA: Oral metal contact allergy: A pilot study on the cause of oral squamous cell carcinoma. *Int J Dermatol* 45: 265-271, 2006.
- Sieglmann-Danieli N, Hanlon A, Ridge JA, Padmore R, Fein DA and Langer CJ: Oral tongue cancer in patients less than 45 years old: Institutional experience and comparison with older patients. *J Clin Oncol* 16: 745-753, 1998.
- Sato T: A study on effect of mechanical irritation in development and progression of tongue cancer. *Kokubyo Gakkai Zasshi* 62: 532-550, 1995 (In Japanese).
- Hilly O, Shkedy Y, Hod R, Soudry E, Mizrahi A, Hamzany Y, Bachar G and Shpitzer T: Carcinoma of the oral tongue in patients younger than 30 years: Comparison with patients older than 60 years. *Oral Oncol* 49: 987-990, 2013.
- Jones JB, Lampe HB and Cheung HW: Carcinoma of the tongue in young patients. *J Otolaryngol* 18: 105-108, 1989.
- Garavello W, Spreafico R and Gaini RM: Oral tongue cancer in young patients: A matched analysis. *Oral Oncol* 43: 894-897, 2007.
- Park JO, Sun DI, Cho KJ, Joo YH, Yoo HJ and Kim MS: Clinical outcome of squamous cell carcinoma of the tongue in young patients: A stage-matched comparative analysis. *Clin Exp Otorhinolaryngol* 3: 161-165, 2010.
- Sarkaria JN and Harari PM: Oral tongue cancer in young adults less than 40 years of age: Rationale for aggressive therapy. *Head Neck* 16: 107-111, 1994.
- Soudry E, Preis M, Hod R, Hamzany Y, Hadar T, Bahar G, Strenov Y and Shpitzer T: Squamous cell carcinoma of the oral tongue in patients younger than 30 years: Clinicopathologic features and outcome. *Clin Otolaryngol* 35: 307-312, 2010.
- Manuel S, Raghavan SK, Pandey M and Sebastian P: Survival in patients under 45 years with squamous cell carcinoma of the oral tongue. *Int J Oral Maxillofac Surg* 32: 167-173, 2003.
- Mallet Y, Avalos N, Le Ridant AM, Gangloff P, Moriniere S, Rame JP, Poissonnet G, Makeieff M, Cosmidis A, Babin E, *et al*: Head and neck cancer in young people: A series of 52 SCCs of the oral tongue in patients aged 35 years or less. *Acta Otolaryngol* 129: 1503-1508, 2009.
- Popovtzer A, Shpitzer T, Bahar G, Marshak G, Ulanovski D and Feinmesser R: Squamous cell carcinoma of the oral tongue in young patients. *Laryngoscope* 114: 915-917, 2004.
- Pindborg JJ, Reichart PA and Smith CJ: Histological typing of cancer and precancer of the oral mucosa. 2nd edition, Springer-Verlag, Berlin, 1997.
- McGregor GI, Davis N and Robins RE: Squamous cell carcinoma of the tongue and lower oral cavity in patients under 40 years of age. *Am J Surg* 146: 88-92, 1983.
- Venables CW and Craft IL: Carcinoma of the tongue in early adult life. *Br J Cancer* 21: 645-650, 1967.
- Newman AN, Rice DH, Ossoff RH and Sisson GA: Carcinoma of the tongue in persons younger than 30 years of age. *Arch Otolaryngol* 109: 302-304, 1983.
- Mashberg A, Boffetta P, Winkelmann R and Garfinkel L: Tobacco smoking, alcohol drinking, and cancer of the oral cavity and oropharynx among U.S. veterans. *Cancer* 72: 1369-1375, 1993.
- Boffetta P, Mashberg A, Winkelmann R and Garfinkel L: Carcinogenic effect of tobacco smoking and alcohol drinking on anatomic sites of the oral cavity and oropharynx. *Int J Cancer* 52: 530-533, 1992.
- Schwartz SM, Daling JR, Doody DR, Wipf GC, Carter JJ, Madeleine MM, Mao EJ, Fitzgibbons ED, Huang S, Beckmann AM, *et al*: Oral cancer risk in relation to sexual history and evidence of human papilloma virus infection. *J Natl Cancer Inst* 90: 1626-1636, 1998.
- Laronde DM, Hislop TG, Elwood JM and Rosin MP: Oral cancer: Just the facts. *J Can Dent Assoc* 74: 269-272, 2008.
- Preston-Martin S, Henderson BE and Pike MC: Descriptive epidemiology of cancers of the upper respiratory tract in Los Angeles. *Cancer* 49: 2201-2207, 1982.
- Cox B, Taylor K and Treasure E: Trends in oral cancer by subsite in New Zealand. *Eur J Cancer B Oral Oncol* 31B: 113-117, 1995.
- Macfarlane GJ, Sharp L, Porter S and Franceschi S: Trends in survival from cancers of the oral cavity and pharynx in Scotland: A clue as to why the disease is becoming more common? *Br J Cancer* 73: 805-808, 1996.
- Jainkittivong A, Aneksuk V and Langlais RP: Oral mucosal conditions in elderly dental patients. *Oral Dis* 8: 218-223, 2002.
- Lockhart PB, Norris CM Jr and Pulliam C: Dental factors in the genesis of squamous cell carcinoma of the oral cavity. *Oral Oncol* 34: 133-139, 1998.
- Kinnebrew M, Gittleman L, Carr RF and Beazley R: Squamous cell carcinoma of the tongue in a young woman. Report of a case with etiologic considerations. *Oral Surg Oral Med Oral Pathol* 58: 696-698, 1984.