

Arthroscopic Revision with Autologous Iliac Crest Bone Graft for Failed Anatomic Glenoid Reconstruction Using Distal Tibia Allograft



Rakesh John, MBBS, M.S. (Orth), DNB (Orth), MRCS (England), MNAMS, Dip (SICOT), Catherine M. Coady, MD, FRCSC, and Ivan Wong, MD, FRCSC, MACM, Dip. Sports Med

Abstract: Recurrent instability after anterior shoulder stabilization surgery is not an uncommon complication, with variable rates of recurrences associated with different surgical procedures. The Latarjet procedure continues to be the gold standard in the management of anterior instability with significant glenoid bone loss, although a recent trend toward arthroscopic anatomic glenoid reconstruction (AAGR) with distal tibial allograft has been noted, with excellent short-term results and minimal complication rates. Arthroscopic revision stabilization for failed stabilization procedures is increasingly being performed, although it is technically more challenging than the primary stabilization procedure because of the anatomic rearrangements of the index surgery. In this article, we describe a revision arthroscopic technique for anatomic glenoid reconstruction using iliac crest autograft for a previous failed AAGR procedure secondary to nonunion of the graft. The graft is passed through the Halifax far-medial portal without splitting the subscapularis. Arthroscopic revision in the setting of a failed AAGR procedure is technically easier than after a Latarjet procedure, as the anatomy is relatively undisturbed in the former, facilitating easier identification of anatomic landmarks, accurate graft positioning, and decreased risk of neurovascular injuries. A Bankart capsulolabral repair is performed after graft fixation, making the graft extra-articular and providing additional stability.

Recurrence after arthroscopic or open primary repair for anterior shoulder stabilization is not an uncommon complication; the rate of recurrence varies from 0% to 60% depending on the surgical technique used.^{1,2} A myriad of reasons have been reported for recurrence after primary surgery: trauma, inappropriate procedure selection (failure to address capsular laxity; glenoid or humeral bone loss), improper rehabilitation protocols (too early return to activity/sports, loss to follow-up), technical factors, and patient factors.^{1,3,4}

A revision stabilization procedure is often necessary because of the variable success rates of different procedures; correct identification of the underlying causes of failure and appropriate selection of surgical technique are paramount to the success of a revision surgery. Traditionally, open surgical techniques have been used in the revision surgery setting; however, with developments in arthroscopic techniques and technology, a trend toward arthroscopic revision surgery has been noted.^{1,5}

The role of bone loss, both glenoid and humeral, has been established in postoperative failures after anterior shoulder stabilization techniques.⁶ Numerous glenoid reconstruction techniques have been described for patients who have recurrent instability with significant anterior glenoid bone loss to increase the articular surface area of the glenoid and consequently decrease the likelihood of recurrence.⁷ Wong and Urquhart⁸ described an arthroscopic anatomic glenoid reconstruction (AAGR) technique with a distal tibial allograft for the treatment of shoulder instability in the lateral decubitus position. This technique offers several advantages: anatomic reconstruction of the glenoid articular surface while preserving the coracoid and its attachments, preservation of subscapularis, more

From the Division of Orthopaedic Surgery, Department of Surgery, Faculty of Medicine, Dalhousie University, Halifax, Nova Scotia, Canada.

The authors report that they have no conflicts of interest in the authorship and publication of this article. Full ICMJE author disclosure forms are available for this article online, as [supplementary material](#).

Received April 26, 2019; accepted July 6, 2019.

Address correspondence to Dr. Ivan Wong, MD, FRCSC, MACM, Dip. Sports Med, Dalhousie University, Division of Orthopaedic Surgery, Department of Surgery, Faculty of Medicine, Halifax, NS, Canada B3H2E1. E-mail: iw@drivanwong.com

© 2019 by the Arthroscopy Association of North America. Published by Elsevier. This is an open access article under the CC BY-NC-ND license (<http://creativecommons.org/licenses/by-nc-nd/4.0/>).

2212-6287/19562

<https://doi.org/10.1016/j.eats.2019.07.009>

accurate positioning of graft compared with open technique, and provision for an additional soft tissue repair (capsulolabral complex) over the graft.^{8,9} Short-term outcomes for this technique have been favorable, with no subluxations or dislocations in 97% of cases at a mean follow-up of 2 years. The safety profile of this technique is also well established.^{9,10}

Open shoulder stabilization techniques have hitherto been preferred in revision scenarios.^{1,3,11,12} Revision arthroscopic Bankart repair is now increasingly being used after failed instability surgery, with some surgeons using it after failed open surgeries as well.^{1,5,13,14} Only 1 study has been published on the use of arthroscopic iliac crest autograft (ICA) technique for revision surgery; however, the index surgeries in that study were mainly open Latarjet procedures and a few arthroscopic Bankart repairs.¹⁵

In this article, we describe an all-arthroscopic anatomic glenoid revision technique using ICA to reconstruct the glenoid in a patient who previously had an AAGR procedure with a distal tibial allograft. The reason for recurrence in this case was graft nonunion and broken hardware.

Surgical Technique

Preoperative Assessment and Operating Room Setup

The preoperative clinical assessment of the patient is performed as described in our previously published technique.⁸ Shoulder imaging consists of anteroposterior, axillary, and trans-scapular Y-views, as well as a computed tomography (CT) scan with 3-dimensional reconstruction, all performed to assess glenoid bone loss, degree of nonunion/malunion of the previously placed allograft, and the volume of Hill-Sachs lesion, if any (Fig 1). A 3-dimensional model is printed to better understand the anatomy and to assist in preoperative planning. The patient is positioned in the lateral decubitus position, and landmarks are drawn on the skin as described in our previously published technique (Fig 2).⁸

Evaluation and Debridement

A standard diagnostic arthroscopy is performed according to Snyder's described technique after establishing a posterior portal.¹⁶ The steps of our procedure can be viewed in Video 1. Anterosuperior and anteroinferior portals are established using outside-in technique as described previously.⁸ Scar tissue, especially in relation to the subscapularis, should be debrided thoroughly until the muscle is freely mobile to allow easy retraction later on. Bony union of the previously placed allograft is assessed and correlated with CT findings. The tip of the coracoid, along with the conjoined tendon, should be visualized clearly, followed by the coracoacromial ligament, which is released partially (one-third of ligament). Hardware from the previous surgery is retrieved as necessary.

The arthroscope is then switched to the anterosuperior portal, and a cannula is placed in the posterior portal to serve as an outflow for irrigation fluid. The rotator interval healing, suture anchor placement, and soft tissue integrity after previous surgery are assessed through this portal. The screw tips are removed under visualization. (In this case, we were able to clearly see the previous Bankart repair in place.) With the goal of saving as much soft tissue as possible, the soft tissue over the anterior rim of the glenoid is raised en bloc with a labral elevator through the anteroinferior portal. (A nonunion of the allograft was noted in this case with resultant broken screws.) Broken screw tops should be removed, and the remaining screws, if well within the glenoid, may be left in situ even if they are not visualized. A Wissinger rod inserted through the posterior portal is used for subscapularis retraction inferiorly. A stonecutter burr is used to clear any malunited bone from the anterior rim of the glenoid, followed by decortication and rasping to allow healthy bleeding from the raw, cancellous bony surface. The glenoid bone loss and Hill-Sachs lesion are measured with a calibrated probe and correlated with the CT scan measurements.

The patient's arm is then repositioned with the arm in adduction and elbow flexed to 90° to release the

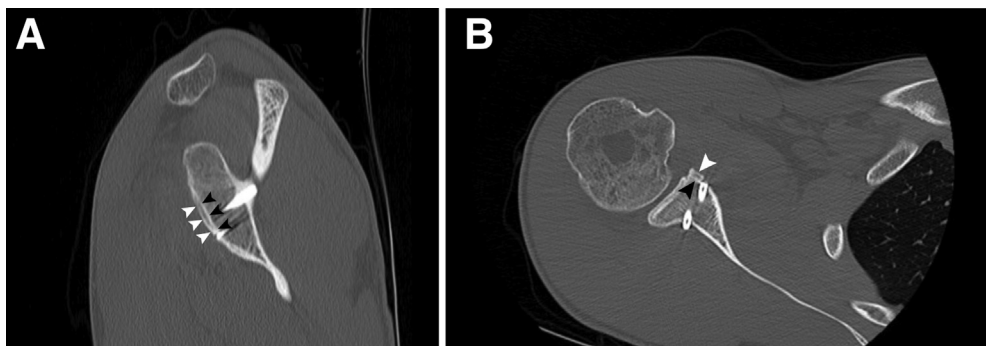


Fig 1. Sagittal and axial computed tomography images showing nonunion (A) and near-complete resorption (B) of the distal tibial allograft in the right shoulder of the patient (white arrow, new cortical bone; black arrow, original cortical bone).

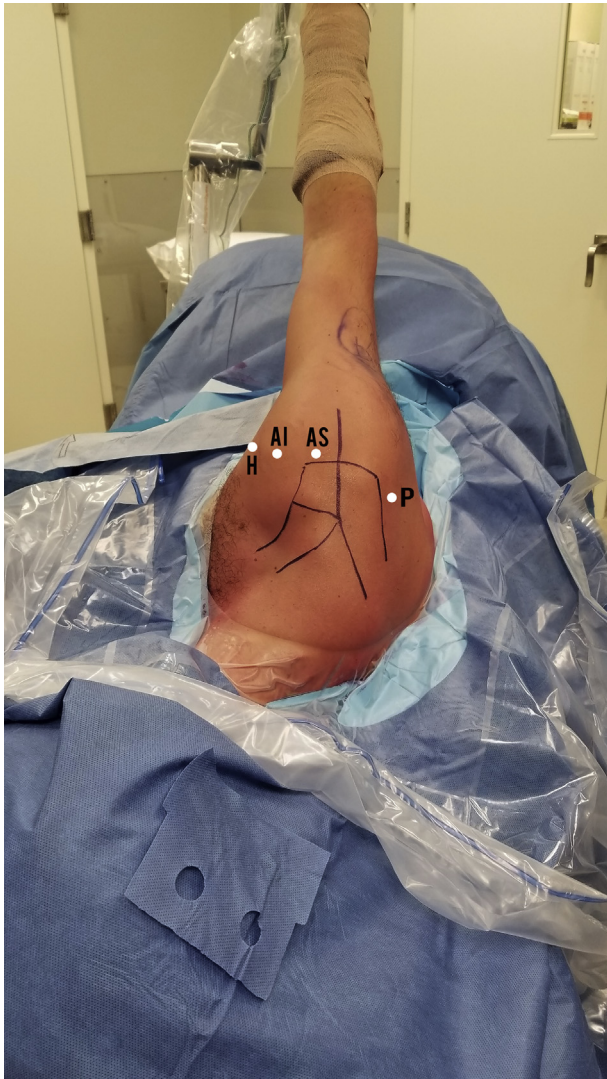

Fig 2. Patient positioning in lateral decubitus with arm positioning in SPIDER2 limb positioner and marking of surgical landmarks and arthroscopic portals. AI, anteroinferior portal; AS, anterosuperior portal; H, head of humerus; P, posterior portal.

tension on the conjoined tendon. Traction is released from the shoulder, allowing the head of the humerus to be reduced into the glenoid under direct vision. The far medial portal or Halifax portal is now created using the inside-out technique previously published by our team.^{8,17,18}

Graft Preparation and Insertion

The ipsilateral iliac crest graft donor site is prepared and draped according to standard procedure. A tricortical segment of bone is harvested from the iliac crest, sizing it according to the dimensions of the bony defect measured.¹⁹ The cancellous surface of the tricortical bone block is positioned on the back table such that it will face the anterior glenoid rim. Either the inner or outer surface of the graft can be positioned

laterally depending on which surface better suits the anatomic glenoid concavity. The graft is attached to a double-barreled clear cannula (Depuy-Mitek) with 2 top-hat washers (Fig 3).¹⁹

The graft is introduced through the Halifax portal ensuring that it is placed flush with the prepared glenoid neck, with a 1- to 2-mm step-off from the glenoid articular cartilage. In the coronal plane, the graft should be positioned with 25% to 50% of the graft above the glenoid equator (Fig 4). Two long guidewires are drilled in a parallel direction from anterior to posterior through the double-barrel cannula and exiting the skin posterior to shoulder joint, taking care to avoid any previous screw tracks. A 3.2-mm calibrated, cannulated drill is passed over the guidewires, depth is measured, and 2 cannulated screws are inserted; these are alternatively tightened to allow the top-hat washers to absorb hoop stresses effectively.⁸

Capsulolabral Complex Management

The capsulolabral complex, which was mobilized earlier, can be repaired over the graft in most cases using small soft tissue suture anchors and standard Bankart repair technique, taking care to avoid placing suture anchors over the screws (Fig 4). The construct is then viewed through all portals to ensure that the humeral head is stable on the glenoid while taking it through a range of motion and stress tests. The arthroscopic portals are closed, and the arm is placed in a neutral rotation sling with wedge.

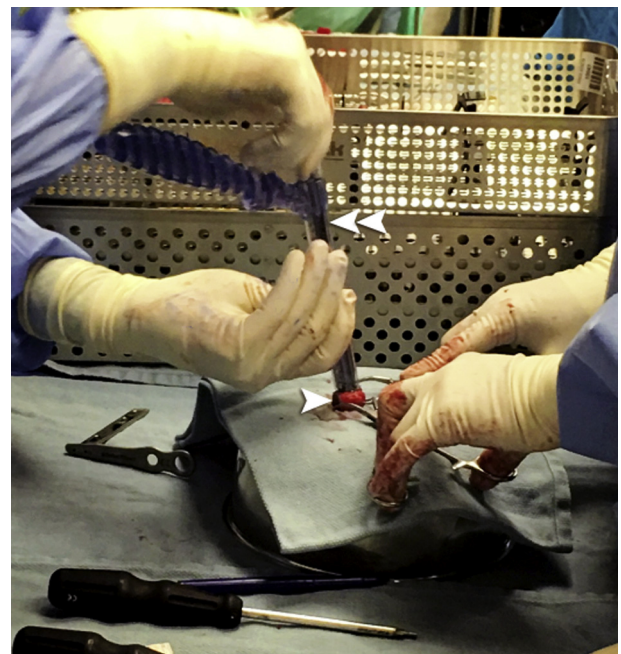

Fig 3. Double-barreled cannula (white double arrow) attached to the prepared tricortical iliac crest autograft (white single arrow) over the back table.

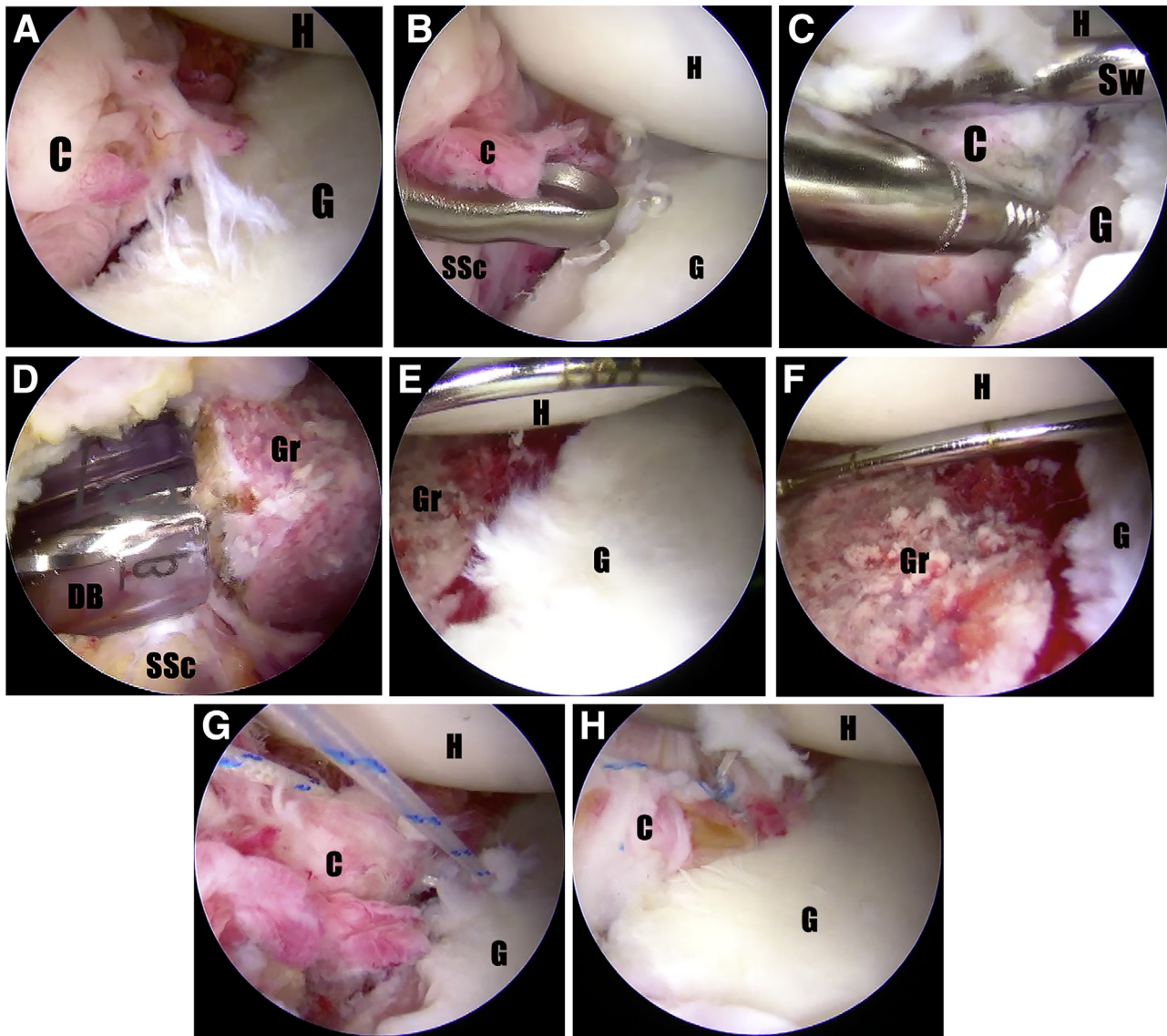


Fig 4. The patient was in the lateral decubitus position. The viewing portal for all images was anterosuperior. Working portal was anteroinferior for all images except Fig 4D which was the Halifax portal. The switching stick was coming from the posterior portal. The following are the details of the intraoperative arthroscopic images of the technique: (A) View after hardware removal; (B) Thin layer of articular cartilage removed with a ring curette; (C) High-speed burr to roughen the anterior glenoid surface to create a healthy, bleeding bone surface; (D) Iliac crest graft introduced through the Halifax portal attached to a double-barrel cannula; (E, F) Images showing the graft positioned flush with the anterior glenoid; and (G, H) Capsulolabral repair being performed with suture anchors. (C, capsule; DB, double barrel; G, glenoid; Gr, graft; H, head of humerus; SSc, subscapularis; Sw, switching stick.)

Table 1. Pearls and Pitfalls

Pearls	Pitfalls
Lateral decubitus position allows good visualization of glenoid	Poor visualization makes anterior glenoid preparation and graft fixation difficult
Improved access to iliac crest bone graft harvest in the lateral decubitus position	Relatively difficult to harvest iliac crest bone graft in beach chair position
Posterior portal parallel to glenoid makes creation of Halifax portal and graft positioning easier	Unparallel posterior portal makes Halifax portal creation and graft positioning difficult
Meticulous dissection of rotator interval to allow accurate identification of anatomic landmarks	Increased risk of neurovascular injuries and difficulties in graft positioning with inadequate dissection
Creates a healthy, bleeding bone surface on the anterior glenoid for good bone-to-bone fixation and healing	Chances of delayed union/nonunion with inadequate decortication
Step of 1 to 2 mm between bone block and glenoid	Abnormal contact surface pressures on humeral head if bone block is proud
Graft is extra-articularized after Bankart repair	Intra-articular graft will increase chances of glenohumeral arthritis

Table 2. Advantages and Disadvantages

Advantages	Disadvantages
Easier to revise: relatively well-maintained anatomy after arthroscopic anatomic glenoid reconstruction compared with a Latarjet	Graft donor site morbidity
Better accuracy in graft placement compared with open technique	Steep learning curve
Additional constraint with Bankart repair to create extra-articular graft	
Ability to address concomitant intra-articular pathologies	
Subscapularis sparing with better strength and recovery	
Decreased risk of postoperative adhesions and stiffness	
Better cosmesis	
Improved pain control; faster rehabilitation and return to activity	
Lesser risk of neurovascular injuries because of easier identification of landmarks	
Can address humeral head bone loss (if necessary)	

Discussion

Traditionally, open surgical techniques have been the mainstay in the setting of revision for failed anterior instability surgeries.^{1,3,12} The use of arthroscopic revision techniques is on the rise but is predominantly limited to revision arthroscopic Bankart repair after failed soft tissue stabilization surgeries.^{3,13} Revision arthroscopic Bankart repair has also been reported for failed open anterior stabilization procedures, mainly open Latarjet procedure, with good results.^{5,14} A systematic review conducted by Friedman et al¹ noted no difference in recurrence rates after revision stabilization with arthroscopic Bankart repair, open Bankart repair, or open Latarjet procedures.

Giannakos et al¹⁵ published a surgical technique and preliminary results of an all-arthroscopic Eden-Hybinette revision procedure for failed anterior instability surgery in 12 shoulders. Ten of the 12 cases had a failed open Latarjet procedure, and 2 had a failed arthroscopic Bankart repair. They reported that this arthroscopic technique was safe, effective, and reproducible with good or excellent results in 67% of cases. However, none of the cases in their study had a prior arthroscopic AAGR using an allograft as an index surgery.¹⁵

The revision technique we describe offers several advantages: increased accuracy of graft placement, provision of additional Bankart repair, ability to address concomitant pathologies (e.g., cuff tears, SLAP lesions), minimized neurovascular risk, sparing of subscapularis, option of addressing humeral head bone loss (if necessary), decreased risk of postoperative adhesions and stiffness, better cosmetic results, improved pain control, and faster rehabilitation and return to activity (Tables 1 and 2). The anatomy is relatively undisturbed after a previous anatomic glenoid reconstruction with a free graft compared with a Latarjet procedure; identification of landmarks is easier with this technique, thereby minimizing the risk of neurovascular injuries.

The main disadvantage of this procedure is the graft donor site morbidity (pain, hypoesthesia, potential for hernia); however, it is preferable to use autograft over

allograft in the revision scenario because of concerns over resorption of allograft in nonunion cases. The steep learning curve expected for this relatively complex arthroscopic technique is another potential disadvantage.

Conclusions

An AAGR with ICA is a safe, effective technique to address revision shoulder stabilization in the face of glenoid bone loss; it accurately recreates the antero-inferior glenoid anatomy arthroscopically while preserving the integrity of the subscapularis tendon. We believe that this technique can be a useful option in revision instability surgery.

References

1. Friedman LGM, Griesser MJ, Miniaci AA, Jones MH. Recurrent instability after revision anterior shoulder stabilization surgery. *Arthroscopy* 2014;30:372-381.
2. Randelli P, Ragone V, Carminati S, Cabitza P. Risk factors for recurrence after Bankart repair: A systematic review. *Knee Surg Sports Traumatol Arthrosc* 2012;20:2129-2138.
3. Abouali JAK, Hatzantoni K, Holtby R, Veillette C, Theodoropoulos J. Revision arthroscopic Bankart repair. *Arthroscopy* 2013;29:1572-1578.
4. Shah AS, Karadsheh MS, Sekiya JK. Failure of operative treatment for glenohumeral instability: Etiology and management. *Arthroscopy* 2011;27:681-694.
5. Boileau P, Richou J, Lisai A, Chuinard C, Bicknell RT. The role of arthroscopy in revision of failed open anterior stabilization of the shoulder. *Arthroscopy* 2009;25:1075-1084.
6. Burkhart SS, De Beer JF. Traumatic glenohumeral bone defects and their relationship to failure of arthroscopic Bankart repairs: Significance of the inverted-pear glenoid and the humeral engaging Hill-Sachs lesion. *Arthroscopy* 2000;16:677-694.
7. Rabinowitz J, Friedman R, Eichinger JK. Management of glenoid bone loss with anterior shoulder instability: Indications and outcomes. *Curr Rev Musculoskelet Med* 2017;10:452-462.

8. Wong IH, Urquhart N. Arthroscopic anatomic glenoid reconstruction without subscapularis split. *Arthrosc Tech* 2015;4:e449-e456.
9. Amar E, Konstantinidis G, Coady C, Wong IH. Arthroscopic treatment of shoulder instability with glenoid bone loss using distal tibial allograft augmentation: Safety profile and short-term radiological outcomes. *Orthop J Sports Med* 2018;6:232596711877450.
10. Wong I, Amar E, Coady CM, Dilman DB, Smith B. Arthroscopic treatment for shoulder instability with glenoid bone loss using distal tibia allograft augmentation: Short term results. *Orthop J Sports Med* 2016;4(7 suppl 4):2325967116S0009.
11. Tauber M, Resch H, Forstner R, Raffl M, Schauer J. Reasons for failure after surgical repair of anterior shoulder instability. *J Shoulder Elbow Surg* 2004;13:279-285.
12. Lunn JV, Castellano-Rosa J, Walch G. Recurrent anterior dislocation after the Latarjet procedure: Outcome after revision using a modified Eden-Hybinette operation. *J Shoulder Elbow Surg* 2008;17:744-750.
13. Kim S-H, Ha K-I, Kim Y-M. Arthroscopic revision Bankart repair: A prospective outcome study. *Arthroscopy* 2002;18:469-482.
14. Millar NL, Murrell GA. The effectiveness of arthroscopic stabilisation for failed open shoulder instability surgery. *J Bone Joint Surg Br* 2008;90:745-750.
15. Giannakos A, Vezeridis PS, Schwartz DG, Jany R, Lafosse L. All-arthroscopic revision Eden-Hybinette procedure for failed instability surgery: Technique and preliminary results. *Arthroscopy* 2017;33:39-48.
16. Snyder SJ, Bakh M, Burns J, eds. *Shoulder Arthroscopy*. 3rd ed. Philadelphia: Lippincott Williams & Wilkins, 2014;405.
17. Lewington MR, Urquhart N, Wong IH. Lateral Decubitus all-arthroscopic Latarjet procedure for treatment of shoulder instability. *Arthrosc Tech* 2015;4:e207-e213.
18. Moga I, Konstantinidis G, Wong IH-B. The safety of a far medial arthroscopic portal for anatomic glenoid reconstruction: A cadaveric study. *Orthop J Sports Med* 2018;6:2325967118795404.
19. Fortun CM, Wong I, Burns JP. Arthroscopic iliac crest bone grafting to the anterior glenoid. *Arthrosc Tech* 2016;5:e907-e912.