


How I Do It

Type I Thyroplasty Using a Titanium Implant Combined With Modified Arytenoid Adduction

Koji Matsushima, MD, PhD 

Key Words: Modified arytenoid adduction, titanium implant, type I thyroplasty.

Laryngoscope, 130:2625–2630, 2020

INTRODUCTION

Laryngeal framework surgery, contrived by Isshiki et al.¹ has proven to be effective in adjusting the position and tension of the vocal folds by manipulating the laryngeal cartilages. Type I thyroplasty (TPI) moves the vocal folds inward, and arytenoid adduction (AA) adducts the vocal folds.² Both surgical methods have improved glottal insufficiency caused by incomplete closure of the vocal folds seen in unilateral vocal fold palsy.

A variety of implants are used to fix the vocal folds medially during TPI.^{3–6} The present author has developed the “titanium medialization laryngoplasty implant” (TMLI) (patent number in Japan: 6434921) and reported on its usability.⁷ Further, a number of modifications to AA, along with the surgical indications, have also been reported.^{8–11} The present author also developed and proved the clinical utility of the “all muscles preserved method” (AMPM).¹²

This study aims to present and discuss the results associated with a combined surgical approach of the above-mentioned methods to treat patients with severe breathy hoarseness.

METHODS

Subjects

After approval by the institutional review board of Toho University (Tokyo, Japan) (M18189) and in accordance with the

This is an open access article under the terms of the Creative Commons Attribution-NonCommercial License, which permits use, distribution and reproduction in any medium, provided the original work is properly cited and is not used for commercial purposes.

From the Department of Otolaryngology (K.M.), Toho University School of Medicine, Tokyo, Japan.

Additional supporting information may be found in the online version of this article.

Editor's Note: This Manuscript was accepted for publication on May 20, 2020.

The authors have no funding, financial relationships, or conflicts of interest to disclose.

Send correspondence to Koji Matsushima, MD, PhD, 6-11-1, Omorinishi, Otaku, Tokyo 143-8541, Japan. E-mail: yusa-k-beo@med.toho-u.ac.jp

DOI: 10.1002/lary.28865

1964 Declaration of Helsinki and its later amendments, 18 male patients underwent TPI using a TMLI combined with AA via the AMPM from February 2016 to September 2018 at the Toho University Omori Medical Center, Tokyo, Japan. Patient selection was based on the presence of a large glottal gap or/and a passive gliding movement of the flaccid arytenoid in the palsied side during phonation. Follow-up examinations for 1 year were possible for 15 of these 18 patients. To ensure preoperative symptom uniformity, the pre- and postsurgical vocal functions of 10 patients with a maximum phonation time (MPT) of ≤ 3 seconds and a mean airflow rate (MFR) of ≥ 500 mL/second were statistically compared using Wilcoxon signed-rank test, with $P < .05$ considered significant. The characteristics and electromyography findings of the 10 patients are presented in Table I.

Method

All patients underwent TPI using a TMLI combined with AA via the AMPM under general anesthesia.

Owing to the requirement for a large incision and surgical manipulations around the arytenoid cartilage, a laryngeal mask was used for ventilation. Desflurane was administered for inhalation anesthesia; dexmedetomidine, flurbiprofen axetil, and fentanyl for intravenous anesthesia; and lidocaine and levobupivacaine for local infiltration.

AA was performed first, followed by TPI, during which time the patient was awakened and extubated to examine the effect of the medialization and to adjust positioning of the plate by listening to the voice of the patient.

However, pre- and postoperative vocal rehabilitation were not performed to exclusively evaluate the effect of the surgery. The examinations of vocal functions, including measuring the MPT, MFR, speaking fundamental frequency (SFF), pitch range (PR), and voice handicap index (VHI)¹³, performing an acoustic analysis of sustained vowel sounds using a multidimensional voice program (Pentax Medical, Montvale, NJ); and capturing video recordings of the laryngeal findings were performed before as well as 1 year following the surgery. In each case, the stability and fixation of the TMLI was examined using computed tomography (CT). Consent to publish the findings was obtained from all patients.

RESULTS

The patients' average age was 67.9 years (range, 44–83 years). The pre- and postoperative test results are

presented in Table II.^{14,15} Postoperatively, there were significant improvements in the MPT, MFR, and VHI. Pre- and postoperative comparisons of SFF, PR, and acoustic parameters were not possible in most patients because they had difficulty producing sustained vowel sounds and had a very short MPT.

The mean postoperative SFF and PR were 145.7 Hz (range B2-G3) and 21.7 ± 4.5 semitones (mean \pm standard deviation), respectively. The results of the postoperative acoustic analysis of the jitter %, shimmer %, and harmonic-to-noise ratio were $0.53 \pm 0.18\%$, $2.54 \pm 1.06\%$, and 0.12 ± 0.02 , respectively. Almost all postoperative test results were in the normal range for elderly adult males.

In the postoperative CT neck images, no implant migration, deformation, or fractures were identified.

The results associated with the pre- and postoperative endoscopic laryngeal findings of the 10 patients are presented in the Video.

DISCUSSION

The Concept Behind the Treatment of Unilateral Vocal Fold Palsy

Two main factors are associated with incomplete glottal closure leading to glottal insufficiency with severe breathy hoarseness: 1) an arcuate change (bowing) in the laterally fixed vocal fold caused by atrophy of its adductors, and 2) a passive gliding movement of the flaccid arytenoid in the palsied side during phonation.¹⁶

Therefore, treating unilateral vocal fold palsy involves the reconstruction of the palsied vocal fold to its physiological state at the time of phonation. For this purpose, a TPI using a TMLI combined with AA via the AMPM was performed. Using this surgical approach, the vibratory portion of the vocal fold was reconstructed with anterior fixation, and adequate tension was achieved through posterior fixation (Fig. 1).

Arytenoid Adduction: AMPM

The physiological rotation of the arytenoid cartilage cannot be easily reproduced by applying lateral pressure alone.¹⁷ AA aims to move the palsied vocal fold to the adducted position to reduce the glottal gap during phonation.

In my AA approach with AMPM, access to the arytenoid cartilage with minimum surgery requires accurate preoperative measurements of the arytenoid cartilage site. CT imaging is useful for this purpose. Multiplanar reconstructions of the image data allow detailed measurements to be made. Sagittal images are used to measure the distance between the inferior notch of the thyroid cartilage and the arytenoid cartilage, and axial images allow the distance between the posterior edge of the thyroid cartilage and the arytenoid cartilage to be measured. Obtaining preoperative CT sagittal images of the arytenoids helped preserve the external laryngeal and pharyngeal constrictors that aid swallowing and supplement the work of compensation during phonation.¹² The external

	Age	Primary Diseases	Electromyography Findings
Case 1	83	Aortic dissection	Reinnervation potential
Case 2	44	Aortic dissection	Reinnervation potential
Case 3	63	Esophageal cancer	Decreased MUP
Case 4	74	Aortic dissection	Decreased MUP
Case 5	74	Idiopathic	Decreased MUP
Case 6	70	Thyroid cancer	Denervation potential
Case 7	77	Aortic dissection	Decreased MUP
Case 8	55	Aortic dissection	Denervation potential
Case 9	69	Aortic dissection	Decreased MUP
Case 10	70	Idiopathic	Denervation potential, decreased MUP

MUP = motor unit potential.

	Preoperative (mean \pm SD)	Postoperative (mean \pm SD)	P Value (Wilcoxon signed-rank test)	Mean in Japanese Adult Males
MPT (s)	1.7 (± 0.9)	22.7 (± 6.0)	<.01	16.9 [†]
MFR (ml/s)	1098.9 (± 420.5)	165.5 (± 32.4)	<.01	170 [†]
SFF (Hz)	*	145.7 (± 21.2)	—	132.0 (± 19.7) [‡]
PR (semitone)	*	21.7 (± 4.5)	—	22 [†]
VHI	60.9	10.4	<.01	
Acoustic analysis				
Jitter %	*	0.53 (± 0.18)	—	0.528 (± 0.25) [‡]
Shimmer %	*	2.54 (± 1.06)	—	2.768 (± 0.97) [‡]
NHR	*	0.12 (± 0.02)	—	0.139 (± 0.01) [‡]

Values are presented as mean \pm standard deviation (n=10).

MFR = mean flow rate; MPT = maximum phonation time; NHR = noise-to-harmonic ratio; PR = pitch range; SD = standard deviation; SFF = speech fundamental frequency; VHI = voice handicap index.

*Unmeasurable.

[†]Value averaged from the data of 74 individuals aged 51 years or older.¹⁴

[‡]Acoustic analysis for normal voices using a multi-dimensional voice program.¹⁵

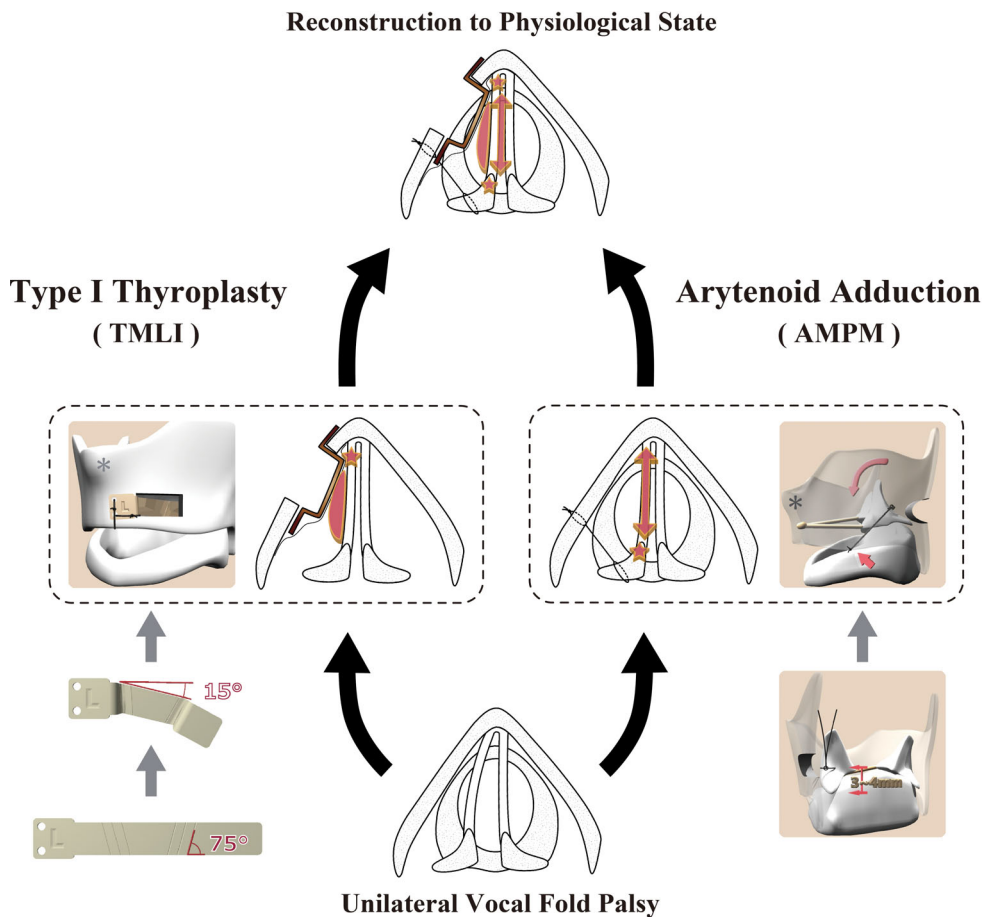


Fig. 1. The concept behind the treatment of unilateral vocal fold palsy. Vocal fold reconstruction to its physiological state during phonation involves compensation of the fixation of the vocal fold anteriorly, reforming its vibratory portion via type I thyroplasty, fixing the vocal fold posteriorly at adduction, and providing adequate tension on the vocal fold via arytenoid adduction. *Anterior notch. AMPM = all muscles preserved method; TMLI = titanium medialization laryngoplasty implant.

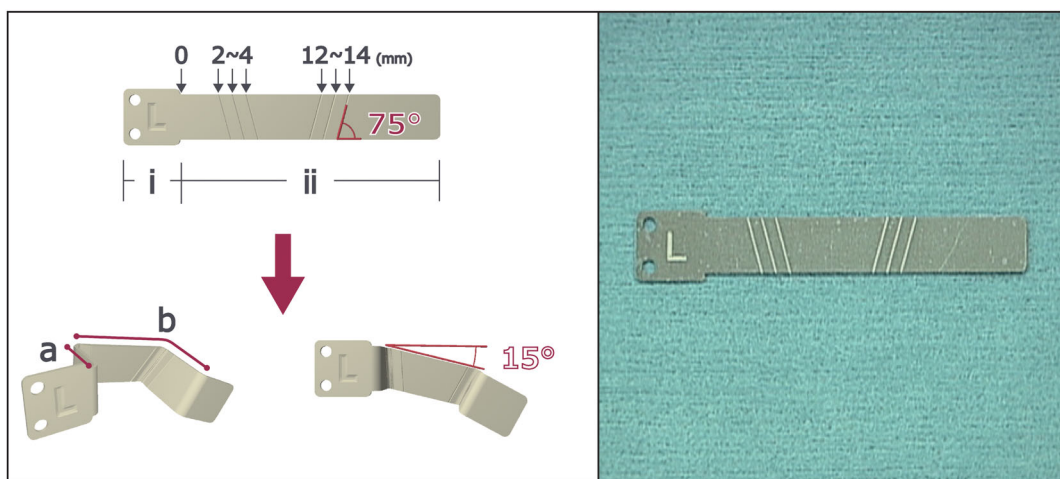


Fig. 2. Titanium medialization laryngoplasty implant. (Left side: scheme). The adjustment to achieve medialization is performed by molding the implant at a suitable site. (i) Handle. (ii) Medialization part. (a) This place adjusts the medialization of the vocal fold anteriorly and carries out compensation of the work of the thyroarytenoid muscle. (b) Adjusting the width and distance that carries out the medialization of the vocal fold here reforms the vibratory portion of the vocal fold. When the implant bends along the line imprinted on it, the medialization part is at a 15° incline to the handle. The implant is bent according to the position of the palsied vocal fold.

branches of the superior laryngeal nerve (ESLN), located in the pharyngeal constrictor muscles, innervate the cricothyroid muscle that controls the tension of the vocal folds during phonation, adjusting the pitch of the voice. Anecdotal evidence of anastomosis of the ESLN and the thyroarytenoid-muscle branch (from the recurrent laryngeal nerve)¹⁸ suggests the postoperative risk of further vocal-fold atrophy if the ESLN is damaged during surgery. Isshiki's original method involves transection of the cricothyroid joint. However, this articular transection is avoided in AMPM to preserve voice quality postoperatively.

The adduction sutures are placed at the base of the muscular process of the arytenoid cartilage, and traction is applied caudally along the direction of the lateral cricoarytenoid muscle at an acute angle when compared to Isshiki's original method.¹⁹

Type I Thyroplasty: TMLI

The implant used here comprises a plate made from pure titanium classified as Japanese Industrial Standards grade 2 (equivalent to ASTM grade 2), with multiple parts enabling its fixation to the thyroid cartilage and medialization of the vocal fold (Fig. 2). The provision of holes enabled its fixation to the cartilage using sutures (Fig. 3); folding the plate four times in the order "mountain-valley-valley-mountain" medialized the vocal fold (Fig. 4). The anterior commissure tendon attaches to the thyroid cartilage, fixing the position of the anterior vocal fold, whereas the posterior vocal fold changes in line with the arytenoids. Therefore, the angle of the palsied vocal fold to the thyroid cartilage is influenced by the paretic grade and AA surgery. The handle of the TMLI is placed at the anterior vocal fold. As the angle of the first valley fold changes, the TMLI is maintained parallel to the vocal

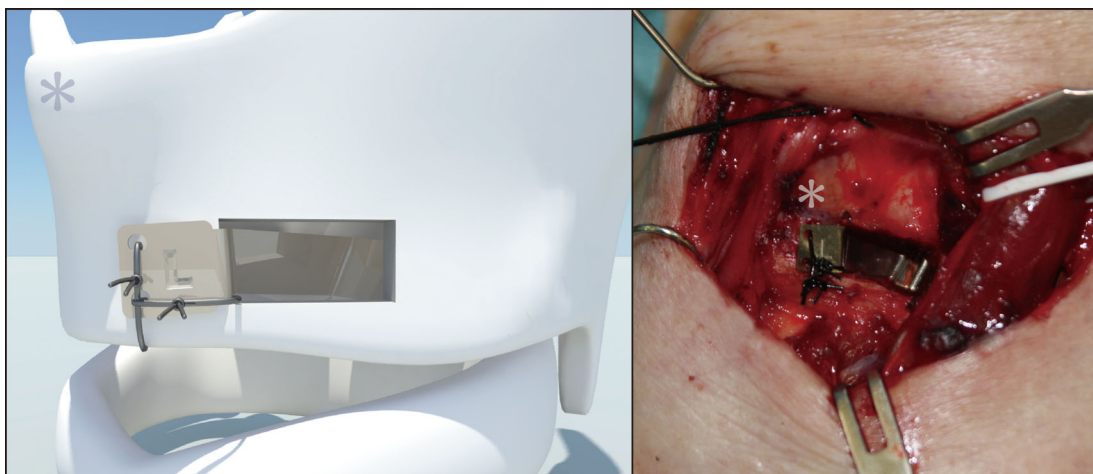


Fig. 3. Fixation of the titanium medialization laryngoplasty implant (left side: scheme). (Left) Implant fixation to the thyroid cartilage by threading nylon sutures through two holes in its handle. (Right) The view of the surgical field. * = anterior notch.

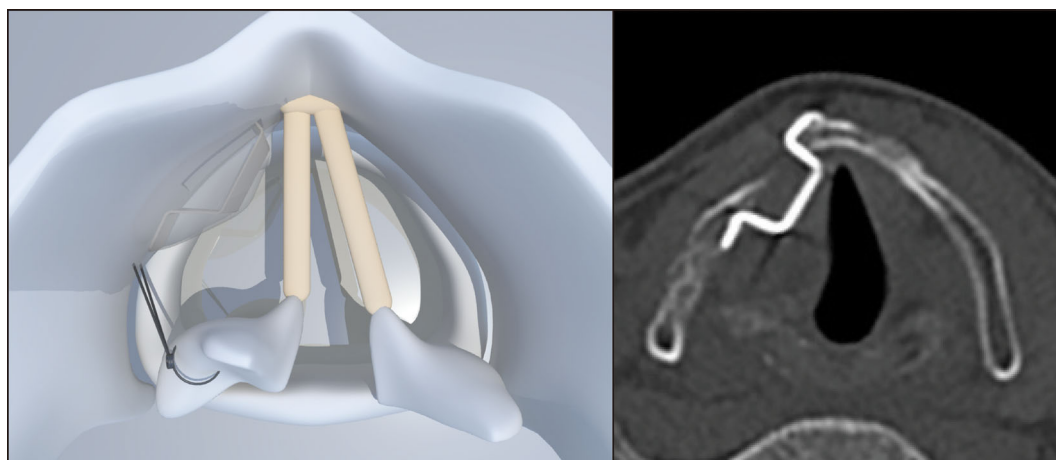


Fig. 4. A postoperative computed-tomography image of the titanium medialization laryngoplasty implant (left side: scheme).

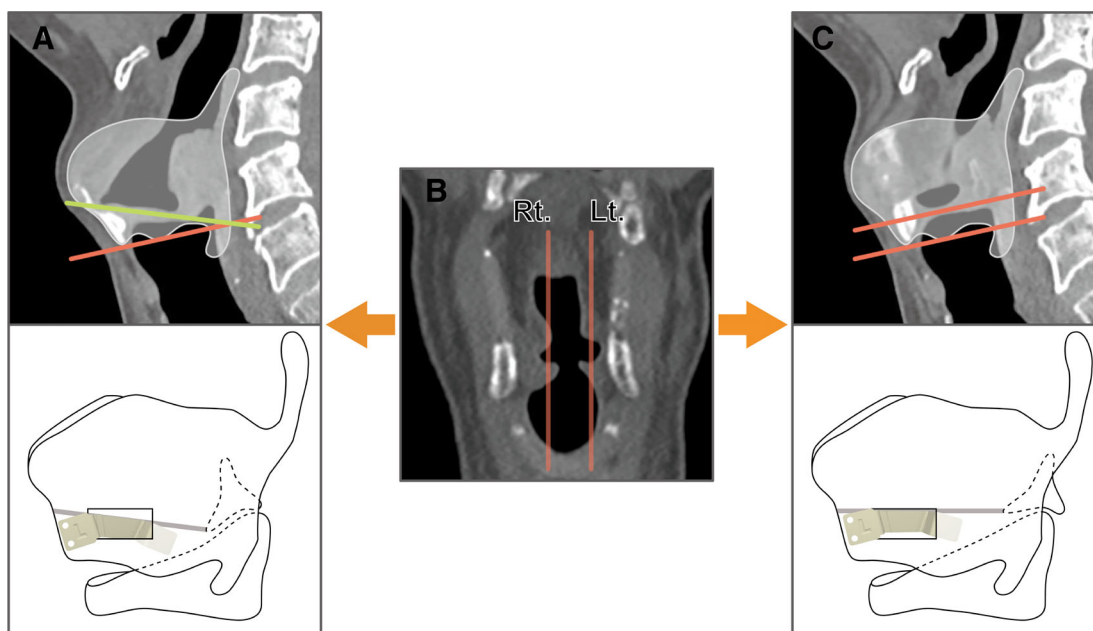


Fig. 5. The characteristic of TMLI. Multi-reconstruction computed tomography image in a patient with left vocal fold palsy (at the time of phonation). Right vocal fold (sagittal image): The right vocal fold is presumed that the arytenoid adduction surgery was performed to treat Right vocal fold palsy. Coronal image: Atrophy of the left vocal fold. Left vocal fold (sagittal image): Palsied vocal fold. The angle between the vocal fold and thyroid cartilage can differ. When the angle of a first valley fold changes, the TMLI is maintained parallel to the vocal fold. TMLI = titanium medialization laryngoplasty implant.

fold (Fig. 5). Moreover, preoperative CT has been shown to aid the performance of TPI as well as AA surgery.²⁰ Because the position of a vocal fold, grade of an atrophy, and shape of a thyroid cartilage can be examined preoperatively, an effective operation can be performed. Although the plate may be used for both sexes, its length can be easily shortened to accommodate small female larynxes using an ordinary nipper.

Because we previously have evaluated the postoperative outcomes, such as the migration, deformation, and fractures of the implant via CT imaging in 73 patients,²⁰ none of the aforementioned findings were studied here. Therefore, we concluded that our results confirmed the stability and permanence of the fixation of the TMLI following its placement.

Based on our professional experience, we believe/opine that TMLI has silicon-like elasticity and allows for fine adjustment similar to the extended polytetrafluoroethylene (ePTFE) sheets.

The results of the present study revealed that patients obtained excellent improvements in their vocal function postoperatively. Further, it can be stated with certainty that the use of the TMLI combined with AA can produce favorable postoperative outcomes in unilateral vocal fold palsy with severe breathy hoarseness.

ACKNOWLEDGMENT

The author would like to thank Dr. Isshiki and Dr. Tanabe for their advice on developing the implant. The author also would like to thank Dr. Hirose for suggestions

on writing the article and on naming the implant “titanium medialization laryngoplasty implant.” In addition, the author would like to thank Dr. Oridate for recognizing the usefulness of the TMLI.

BIBLIOGRAPHY

1. Isshiki N, Morita M, Okamura H, Hiramoto M. Thyroplasty as a new phonosurgical technique. *Acta Otolaryngol* 1974;78:451–457.
2. Isshiki N, Tanabe M, Sawada M. Arytenoid adduction for unilateral vocal cord paralysis. *Arch Otolaryngol* 1978;104:555–558.
3. Montgomery WW, Montgomery SK. Montgomery thyroplasty implant system. *Ann Otol Rhinol Laryngol Suppl* 1997;170:1–16.
4. McCulloch TM, Hoffman HT. Medialization laryngoplasty with expanded polytetrafluoroethylene. Surgical technique and preliminary results. *Ann Otol Rhinol Laryngol* 1998;107:427–432.
5. Friedrich G. Titanium vocal fold medializing implant: introducing a novel implant system for external vocal fold medialization. *Ann Otol Rhinol Laryngol* 1999;108:79–86.
6. Matsushima K, Isshiki N, Tanabe M, Suetsugu T. Thyroplasty type I with titanium implant for vocal fold medialization. *Pract Otol* 2015;143:68–74.
7. Matsushima K. Investigation of type I thyroplasty using titanium implant. *Nihon Jibiinkoka Gakkai Kaiho* 2015;118:1027–1036.
8. Maragos NE. The posterior thyroplasty window: anatomical considerations. *Laryngoscope* 1999;109:1228–1231.
9. Tokashiki R, Hiramatsu H, Tsukahara K, et al. A “fenestration approach” for arytenoid adduction through the thyroid ala combined with type I thyroplasty. *Laryngoscope* 2007;117:1882–1887.
10. Benninger MS, Manzoor N, Ruda JM. Short- and long-term outcomes after silastic medialization laryngoplasty: are arytenoid procedures needed? *J Voice* 2015;29:236–240.
11. Zimmermann TM, Orbelo DM, Pittelko RL, Youssef SJ, Lohse CM, Ekbohm DC. Voice outcomes following medialization laryngoplasty with and without arytenoid adduction. *Laryngoscope* 2019;129:1876–1881.
12. Matsushima K. All muscle preserved method in arytenoid adduction. *Clin Otolaryngol* 2019;44:1186–1189.
13. Shiramoto O, Oridate N, Ikui Y, et al. Reliability and validity of the Japan Society of Logopedics and Phoniatrics version of VHI and VHI-10. *Jpn J Logop Phoniatr* 2014;55:291–298.
14. Hagio Y. Investigation of the standard voice function value of the elderly. *Larynx Jpn* 2004;16:111–121.

15. Nishio M, Niimi S. Multi-parametric analysis for normal voices using a multi-dimensional voice program. *Sogo Rihabiriteshon* 2002;30:927–933.
16. Hiramatsu H, Tokashiki R, Suzuki M. Usefulness of three-dimensional computed tomography of the larynx for evaluation of unilateral vocal fold paralysis before and after treatment: technique and clinical applications. *Eur Arch Otorhinolaryngol* 2008;265:725–730.
17. von Leden H, Moore P. The mechanics of the cricoarytenoid joint. *Arch Otolaryngol* 1961;73:541–550.
18. Sanudo JR, Maranillo E, Leon X, Mirapeix RM, Orus C, Quer M. An anatomical study of anastomoses between the laryngeal nerves. *Laryngoscope* 1999;109:983–987.
19. Matsushima K, Matsui H, Ohira S, Matsuura K. Outcomes in two patients with vocal fold palsy who underwent revision arytenoid adduction surgery. *J Laryngol Otol* 2019;133:1017–1020.
20. Matsushima K. Type I thyroplasty. *Larynx Jpn* 2019;31:112–116.