

Available online at www.sciencedirect.com

ScienceDirect

journal homepage: <http://Elsevier.com/locate/radcr>

Chest

Occult lawn mower projectile injury presenting with hemoptysis

Patric J. Darvie BS^a, David H. Ballard MD^{b,*}, Nicholas Harris MD^c,
Peeyush Bhargava MD, MBA^d, Vyas R. Rao MD^c, Navdeep S. Samra MD^c

^a School of Medicine, Louisiana State University Health-Shreveport, Louisiana, USA

^b Mallinckrodt Institute of Radiology, Washington University School of Medicine, 510 S. Kingshighway Blvd, St. Louis, MO 63110, USA

^c Department of Surgery, Louisiana State University Health-Shreveport, Louisiana, USA

^d Department of Radiology, Louisiana State University Health-Shreveport, Louisiana

ARTICLE INFO

Article history:

Received 25 July 2017

Received in revised form 27 July 2017

Accepted 8 August 2017

Available online

Keywords:

Penetrating injury

Hemoptysis

Lawn mower injury

ABSTRACT

We present the case of a 72-year-old man with hemoptysis after a thoracic projectile injury, which occurred while mowing the lawn. Chest radiograph followed by a computed tomography angiogram revealed a metallic foreign body in the right middle lobe of the lung. The patient underwent a right anterolateral thoracotomy where the object was successfully retrieved. The patient had an uneventful postoperative recovery.

© 2017 the Authors. Published by Elsevier Inc. under copyright license from the University of Washington. This is an open access article under the CC BY-NC-ND license (<http://creativecommons.org/licenses/by-nc-nd/4.0/>).

Introduction

Power lawn mowers have the potential to cause severe injury and even death. Typically, direct contact with the turning blades causes severe wounds that require hospitalization. These injuries can occur by running over limbs, injury while attempting to remove debris when the mower is running, and falls that could cause the lawn mower blades to come into contact with the torso and other parts of the body. The blades are able to

cause significant injuries because they can spin at 3000 rpm and produce 2100 ft lb of kinetic energy [1]. This force is 3 times as powerful as a 0.357 magnum revolver [2,3]. However, there are multiple other ways lawn mowers can cause severe injury and hospitalization including burns, broken blades, driver falling off riding mower, and debris projectile injury. Injuries from projectiles can be severe as they can be thrown at a speed of 232 mph (374 kph; 104 m/s) [1].

Approximately 30 million lawn mowers are currently in use in the United States and are a significant cause of morbidity,

Competing Interests: All authors claim no conflicts of interest or disclosures.

* Corresponding author.

E-mail address: davidballard@wustl.edu (D.H. Ballard).

<https://doi.org/10.1016/j.radcr.2017.08.007>

1930-0433/© 2017 the Authors. Published by Elsevier Inc. under copyright license from the University of Washington. This is an open access article under the CC BY-NC-ND license (<http://creativecommons.org/licenses/by-nc-nd/4.0/>).

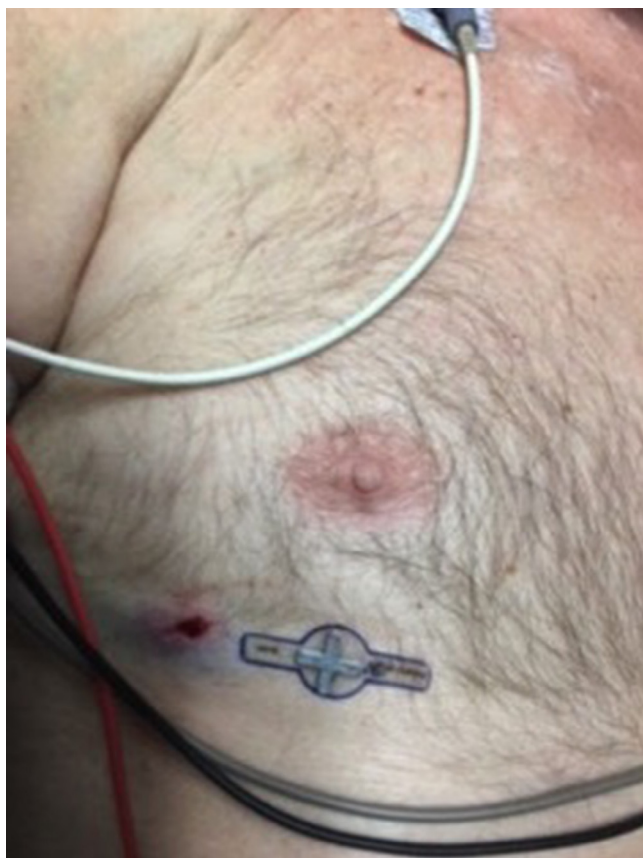

Fig. 1 – Photograph of skin laceration lateral and inferior to the right nipple.

with approximately 74,000 annual emergency room visits for lawn mower-related injuries [3,4]. Projectiles-related injuries are the most frequent injury requiring treatment [4]. We present a case of an occult projectile injury, which presented with hemoptysis.

Case presentation

A 72-year-old man presented to the emergency department with right-sided chest pain and hemoptysis, which began while mowing the lawn 2 hours before admission. A small hemostatic laceration was noted just below and lateral to the right nipple (Fig. 1). Chest radiograph revealed a linear radiopaque foreign body in the right lung (Fig. 2). Computed tomography angiogram showed the metallic foreign body to be located in the right middle lobe, possibly involving a subsegmental artery and surrounded by extensive pulmonary hemorrhage with associated right hemothorax without pneumothorax or pneumomediastinum (Fig. 3). Additionally, the projectile was located less than 1 cm from the cardiac silhouette and ascending aorta, but it did not penetrate the pericardial sac. Because of potential further bleeding, the patient was offered surgical exploration with goal of removing the foreign body, which he elected to undergo.

The patient was taken to the operating room for a right anterolateral thoracotomy. The projectile was palpated in the medial aspect of the right middle lobe just deep to the parietal pleura. A small incision was made, and the foreign body was extracted. It was found to be either a nail or a small piece of wire (Fig. 4). A C-arm was used to ensure no pieces or other projectiles were left before closure. A 32-Fr chest tube was placed intraoperatively before the wound was closed.

Postoperatively, the patient was taken from the operating room to the intensive care unit and remained intubated. He was extubated the following morning and had self-limited minimal hemoptysis. The chest tube was removed 2 days postoperatively and he was discharged that same day.

Discussion

Power lawn mower injuries from debris and projectiles can be extensive despite mild or nearly imperceptible entry wounds. Patients may be asymptomatic or have mild symptoms, which

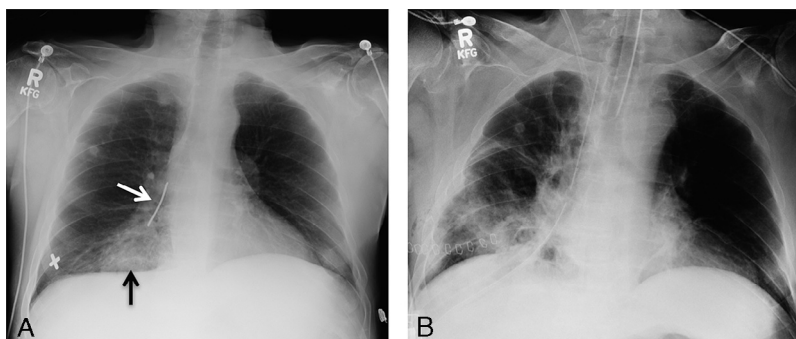


Fig. 2 – Initial portable chest radiograph (A) shows the metallic nail projecting over the right hilum (white arrow). The X in the right lower chest marks the entrance wound on the skin. Diffuse airspace opacification in the right cardiophrenic angle (black arrow) suggests lung contusion or hemorrhage. The follow-up portable chest radiograph (B), obtained after the surgery, shows absence of the nail in the right lung, right lower chest wall skin staples, a right-sided chest tube, and an endotracheal tube. Patchy opacities are seen in the right lung, suggesting contusion, hemorrhage, and linear atelectasis.

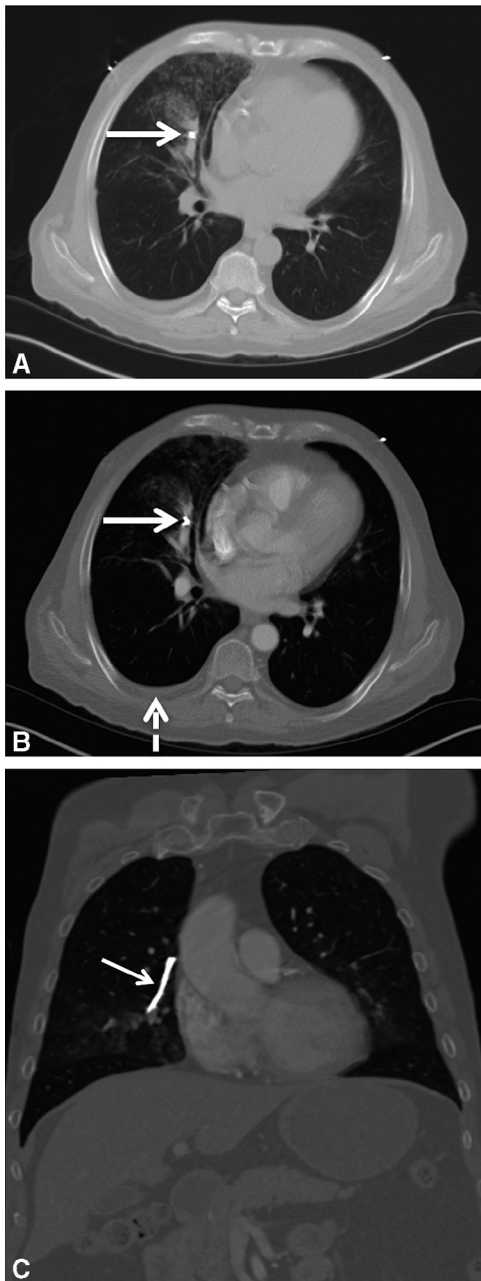


Fig. 3 – Axial computed tomography (CT) image in the lung window (A) shows the metallic nail (white arrow) in the right paracardiac region (right middle lobe) with surrounding airspace opacification suggesting hemorrhage or contusion. Axial CT image at the same level (B), from the IV contrast-enhanced study (displayed in the soft tissue window), shows the nail (white arrow) in the right middle lobe pulmonary artery branch. Small hemothorax is also visualized on the right side (dashed arrow). Coronal reconstruction (C) shows the nail in its entire length (white arrow), along with its dangerous proximity to the ascending aorta.

progress to hemoptysis, as in the present case. In our case, the patient stated he saw a flash when the projectile was thrown toward him and felt it hit his upper body. When he inspected the wound, he noticed only minimal blood and what appeared to be a small scratch, which he dismissed and continued to mow the lawn. He came to the hospital only once the hemoptysis began. In cases such as ours where a patient is hemodynamically stable with minimal outward signs of serious injury, imaging may determine the extent of injury and need for intervention [4].

The diagnosis and subsequent management of penetrating thoracic injuries and hemoptysis is dependent on imaging. As with our patient, a chest radiograph is the most common initial study for penetrating thoracic trauma or hemoptysis, and a computed tomography (CT) is typically obtained next if necessary [4,5]. A chest radiograph can be used to lateralize bleeding and detect lung involvement in hemoptysis cases without obvious injury [5]. In a study of 208 patients with traumatic and atraumatic hemoptysis, chest radiographs were abnormal and contributed to the final diagnosis in 50% of cases [6]. CT is crucial in localizing and determining the extent of bleeding and injury [5,7]. A study of 50 patients with hemoptysis by Abdel-Ghany et al. demonstrated that multidetector CT was able to detect the cause in 84% of patients [8]. In the previously mentioned study of 208 patients with hemoptysis, a normal CT scan was diagnostic in only 67% of patients [6]. However, in many cases, chest radiograph and CT are essential to the formulation of the treatment plan [5,7].

From 1996 to 2004, there was an average of 74,000 annual emergency room visits for lawn mower-related injuries [3,4]. The incidence of injury was significantly higher in men and increased with age [9]. Across all age groups, debris projectile trauma to the eye or other body parts was the most common cause of injury, approximately 13.2%, followed by pain while using the mower [9]. However, in the 65 and older age group, the 3 most common mechanisms of injury were pain with use (11.9%), debris projectile (10.1%), and falling (9.0%) [9].

Deciding whether to surgically remove foreign bodies from the thorax depends on multiple factors including the condition of the patient, location of foreign body, degree of injury, and potential of future infection. In all cases of projectile injury, common skin flora are able to contaminate the wound. Additionally, the dirt, soil, and other objects may contain other microorganisms capable of causing infection, including anaerobic bacteria, in cases where the projectile is hit by a lawn mower [3,10]. In children, wound infection rate from lawn mower injury is reported to be between 5% and 60% [3]. In our patient, the entrance wound was small, but the retained body's source made it a potential nidus of infection.

In conclusion, lawn mower projectile injuries can seem indolent superficially, but the high-speed nature of the projectile can cause severe internal damage. As with all penetrating thoracic injuries, plain chest radiographs are the most appropriate first imaging modality. With hemoptysis, computed tomography angiogram can be helpful in localizing the source.

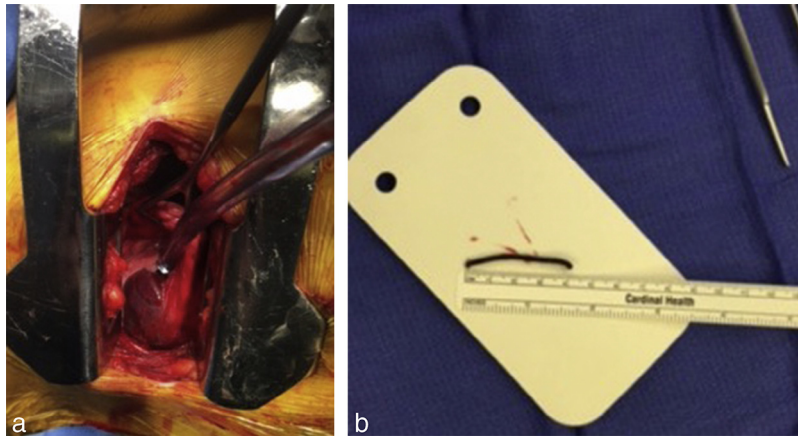


Fig. 4 – Right anterolateral thoracotomy, which revealed the metallic foreign body (A). The projectile appeared to be either a nail or a metal wire (B).

REFERENCES

- [1] Park WH, DeMuth WE Jr. Wounding capacity of rotary lawn mowers. *J Trauma* 1975;15:36–8.
- [2] Esfahani SA, Yousefzadeh DK. Pericardial tamponade with a normal cardiopericardial silhouette due to a penetrating metallic projectile propelled by a lawnmower. *Pediatr Cardiol* 2013;34:2044–6.
- [3] Campbell JR. Infectious complications of lawn mower injuries. *Pediatr Infect Dis J* 2001;20:60–2.
- [4] Durso AM, Caban K, Munera F. Penetrating thoracic injury. *Radiol Clin North Am* 2015;53:675–93, vii–viii.
- [5] Larici AR, Franchi P, Occhipinti M, Contegiacomo A, del Ciello A, Calandriello L, et al. Diagnosis and management of hemothorax. *Diagn Interv Radiol* 2014;20:299–309.
- [6] Hirshberg B, Biran I, Glazer M, Kramer MR. Hemothorax: etiology, evaluation, and outcome in a tertiary referral hospital. *Chest* 1997;112:440–4.
- [7] Mirka H, Ferda J, Baxa J. Multidetector computed tomography of chest trauma: indications, technique and interpretation. *Insights Imaging* 2012;3:433–49.
- [8] Abdel-Ghany AF, Nassef MA, Osman NM. Multidetector CT chest with bronchial and pulmonary angiography determining causes, site and vascular origin of bleeding in patients with hemothorax. *Egypt J Radiol Nucl Med* 2013;44:769–78.
- [9] Costilla V, Bishai DM. Lawnmower injuries in the United States: 1996 to 2004. *Ann Emerg Med* 2006;47:567–73.
- [10] Brook I. Recovery of anaerobic bacteria from wounds after lawn-mower injuries. *Pediatr Emerg Care* 2005;21:109–10.