



# Promyelocytic Blast Phase of Chronic Myeloid Leukemia, *BCR-ABL1*-Positive: Points to be Considered at Diagnosis

Bohyun Kim , M.D., Ph.D.<sup>1</sup>, Hyun Young Chi , M.D.<sup>2</sup>, Young Ahn Yoon , M.D.<sup>1</sup>, and Young-Jin Choi , M.D.<sup>1</sup>

<sup>1</sup>Department of Laboratory Medicine, Soonchunhyang University Cheonan Hospital, Soonchunhyang University College of Medicine, Cheonan, Korea; <sup>2</sup>Samkwang Medical Lab, Seoul, Korea

Dear Editor,

Progression to promyelocytic blast phase (BP) in chronic myeloid leukemia (CML), *BCR-ABL1*-positive is very rare, and only few cases have been reported since the introduction of Tyrosine Kinase Inhibitor (TKI) therapy [1-3]. However, there are no studies on the important considerations for an accurate diagnosis. We report the case of a patient with promyelocytic BP of CML after short-term TKI therapy and provide a review on the diagnosis. The Institutional Review Board of Soonchunhyang University Cheonan Hospital, Chungcheongnam-do, Korea, approved this study (file No. 2020-10-036) and exempted the need for informed consent as there was no identifying information and no harm caused to the patient.

A 35-year-old male patient with leukocytosis ( $60.55 \times 10^9/L$ ) was admitted to Soonchunhyang University Cheonan Hospital in March 2017. Bone marrow (BM) study revealed hypercellularity with myeloid and megakaryocytic hyperplasia. Chromosomal analysis revealed 46,XY,t(9;22)(q34;q11.2)[20]. The quantity of major *BCR-ABL1* fusion transcript was 30.02% (Table 1). The patient was diagnosed as having CML, chronic phase (CP). However, he refused TKI therapy.

Two years later (in April 2019), his peripheral blood (PB) smear revealed marked leukocytosis ( $164.42 \times 10^9/L$ ), anemia, and

thrombocytosis, with 2% blasts and left-shifted neutrophilic maturation. Newly developed hepatosplenomegaly was detected. BM finding was similar to the previous results, but diffuse myelofibrosis was additionally detected. The result of chromosomal analysis was same as before, but the quantity of *BCR-ABL1* fusion transcript increased to 96.17%. The patient was started on dasatinib treatment (100 mg once daily). His leukocyte count normalized during the first month of therapy but gradually increased thereafter.

After two months of dasatinib therapy, the patient complained of oral bleeding. PB smear showed leukocytosis with 97% abnormal promyelocytes, anemia, and thrombocytopenia. The disseminated intravascular coagulation (DIC) score calculated using the International Society on Thrombosis and Haemostasis scoring system was 9 (Table 1) [4]. BM study revealed 96.20% abnormal promyelocytes (Fig. 1A). Immunophenotype of abnormal promyelocytes was consistent with acute promyelocytic leukemia (APL). Chromosomal analysis revealed 46,XY,t(9;22)(q34;q11.2),t(15;17)(q24;q21)[20]. The quantity of *BCR-ABL1* fusion transcript was 53.22%. Multiplex reverse transcriptase-PCR and interphase fluorescence *in-situ* hybridization (FISH) detected both major *BCR-ABL1* and *PML-RARA* fusion transcripts (Fig. 1B-1D). The patient was diagnosed as having promyelo-

Received: June 22, 2020

Revision received: July 13, 2020

Accepted: November 11, 2020

**Corresponding author:** Bohyun Kim, M.D., Ph.D.

Department of Laboratory Medicine, Soonchunhyang University Cheonan Hospital, 31 Soonchunhyang 6-gil, Dongnam-gu, Cheonan 31151, Korea  
Tel: +82-41-570-3571, Fax: +82-41-572-2316  
E-mail: bhkim@schmc.ac.kr



© Korean Society for Laboratory Medicine

This is an Open Access article distributed under the terms of the Creative Commons Attribution Non-Commercial License (<https://creativecommons.org/licenses/by-nc/4.0>) which permits unrestricted non-commercial use, distribution, and reproduction in any medium, provided the original work is properly cited.

**Table 1.** Clinical and laboratory features of patients with promyelocytic BP of CML with both *BCR-ABL1* and *PML-RARA* rearrangements after TKI therapy

	Oku, et al. 2007 [1]	Chung, et al. 2008 [2]	Hoehn, et al. 2013 [3]	Current study
Age/gender	66/F	32/M	72/F	35/M
At primary diagnosis of CML, CP				
WBC count ( $\times 10^9/L$ )	16.20	16.30	39.80	60.55
Hemoglobin (g/L)	Not reported	Not reported	Not reported	137
Platelet count ( $\times 10^9/L$ )	Not reported	Not reported	Not reported	413
Peripheral blood finding	Not reported	2% blasts	1% blasts	Occasional blasts, 14% myelocytes, 12% metamyelocytes, 6% band neutrophils, 55% neutrophils
Splenomegaly	Not reported	Mild	Not reported	None
Bone marrow finding	7.20% blasts, M:E ratio 9.55:1	1.00% blasts, M:E ratio 26.8:1	Not reported	1.20% blasts, M:E ratio 12.6:1
Chromosome	46,XX,t(9;22)(q34;q11)	46,XX,t(9;22)(q34;q11)	46,XX,t(9;22)(q34;q11)	46,XX,t(9;22)(q34;q11)
FISH for major <i>BCR-ABL1</i> rearrangement	Positive (89.3%)	Not reported	Positive	Not tested
Quantity of <i>BCR-ABL1</i> transcript	Not reported	0.016	Not reported	30.02%
Treatment	Imatinib 400 daily	Imatinib 400 daily	Imatinib	Dasatinib 100 mg daily two yrs after diagnosis
Clinical course after TKI therapy	CHR, good CcYr after eight months	CHR after three months	CcYr and IMMR	Not evaluated
At diagnosis of CML, BP				
Time to progression to BP	16 months after diagnosis	Six months after diagnosis	Not reported	26 months after diagnosis
WBC count ( $\times 10^9/L$ )	0.30	4.90	17.80	45.67
Hemoglobin (g/L)	96	95	98	79
Platelet count ( $\times 10^9/L$ )	49	15	9	3
Peripheral blood finding	91% leukemic promyelocytes	53% leukemic promyelocytes	90% leukemic promyelocytes	97% leukemic promyelocytes
Bleeding symptom	Gingival bleeding	None	Ecchymosis	Oral bleeding
Prothrombin time	47% (reference range 60–130)	12.6 sec (reference range 10.0–13.0)	19.0 sec (reference range 12.7–15.0)	18.6 sec (reference range 9.5–12.3)
Fibrinogen (g/L)	0.57 (reference range 2.00–4.00)	2.09 (reference range 2.00–4.00)	1.56 (reference range 2.02–4.50)	0.96 (reference range 1.94–4.32)
D-dimer (mg/L FEU)	Not reported	87.10 (reference range <0.40)	>20.00 (reference range <0.40)	6.65 (reference range <0.48)
Presence of DIC	Yes	Yes	Yes	Yes
Bone marrow finding	26.8% leukemic promyelocytes	86.6% leukemic promyelocytes	90.0% leukemic promyelocytes (microgranular variant)	96.2% leukemic promyelocytes
Immunophenotyping	Positive: CD13 and CD33 Negative: CD34 and HLA-DR	Positive: CD13, CD33, and CD117 Negative: CD34 and HLA-DR	Positive: CD2, CD13, CD15, CD33, CD34, CD56, CD64, CD117, and MPO Negative: HLA-DR	Positive: CD13, CD15, CD33, CD64, CD117, and MPO Negative: CD34 and HLA-DR

(Continued to the next page)

Table 1. Continued

	Oku, et al. 2007 [1]	Chung, et al. 2008 [2]	Hoehn, et al. 2013 [3]	Current study
Chromosome	46,XX,t(9;22)(q34;q11.2),t(15;17)(q24;q21)	Not reported	46,XX,der(3)t(3;15)(q21;q15)t(15;17)(q24.1;q21.2),t(9;22)(q34;q11.2),der(15)t(3;15),del(17)(q21)[20]	46,XY,t(9;22)(q34;q11.2),t(15;17)(q24;q21)
FISH for major <i>BCR-ABL1</i> rearrangement	89.3% fusion signal	96.0% fusion signal	85.5% fusion signal	100% fusion signal
FISH for <i>PML-RARA</i> rearrangement	95.0% fusion signal	90.0% fusion signal	81.5% fusion signal	100% fusion signal
Quantity of <i>BCR-ABL1</i> transcript	Not reported	2.21	99.73%	53.22%
Quantity of <i>PML-RARA</i> transcript	Not reported	0.81	13.28%	Not tested
Treatment	Idarubicin, Ara-C and ATRA	ATRA + imatinib	ATRA and arsenic trioxide	Idarubicin, ATRA and dasatinib
Clinical course	Normal hematopoiesis recovered	Not presented	Expired after two months	Marrow cellularity recovered, but did not reach CR

Abbreviations: M, male; F, female; BP, blast phase; CML, chronic myeloid leukemia; WBC, white blood cells; TKI, tyrosine kinase inhibitor; FISH, fluorescence *in-situ* hybridization; CHR, complete hematologic response; CCyR, complete cytogenetic response; DIC, disseminated intravascular coagulation; Ara-C, cytarabine; ATRA, all-trans-retinoic acid; CR, complete response; MMIR, major molecular response; CP, chronic phase; M:E, myeloid:erythroid.

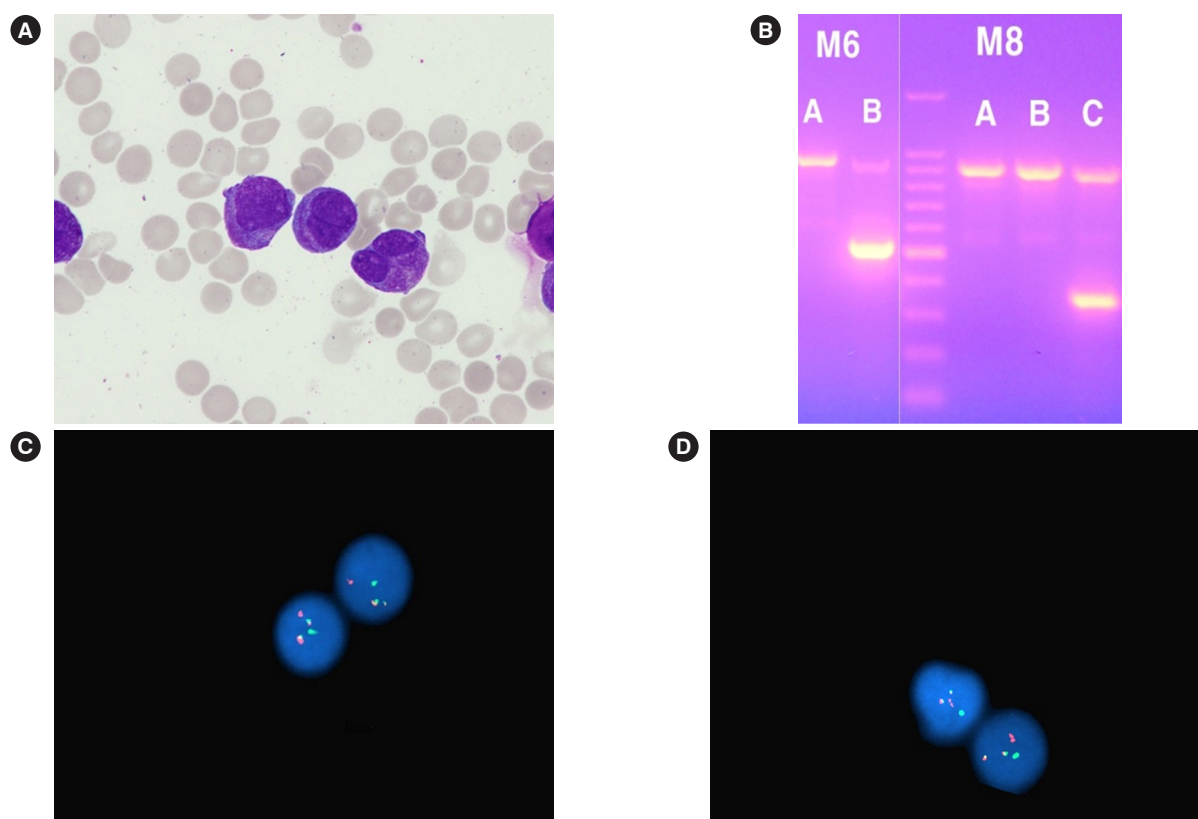
cytic BP of CML and received induction and maintenance chemotherapy. However, complete remission of promyelocytic BP was not achieved, and stem cell transplantation was considered.

We found three reported cases of promyelocytic BP of CML with *BCR-ABL1* and *PML-RARA* rearrangements that have been reported after the introduction of TKI therapy (Table 1) [1-3]. All reported patients were primarily diagnosed as having CML, CP and immediately started on TKI therapy for which they showed good response. The time to progression into promyelocytic BP after starting treatment varied from six to 16 months. In contrast, our patient's condition aggravated to promyelocytic BP just two months after starting treatment; therefore, the time was insufficient to evaluate the response to TKI therapy. Most patients showed increased hypergranular abnormal promyelocytes, and immunophenotypes were typical for APL. The quantities of fusion transcripts of *BCR-ABL1* and *PML-RARA* were variable, but the proportion of fusion signals in FISH were high in all cases.

The following mechanisms have been suggested for disease progression from CML, CP to common BP despite TKI therapy: competitive advantage to Philadelphia-negative cells with genetic instability, chromosomal aberrations, and mutations of tumor suppressor genes and oncogenes [5, 6]. Specific risk factors for disease progression to promyelocytic BP of CML have not been identified so far. Few studies have suggested selective suppression of the Philadelphia-positive clone by TKI and TKI-induced chromosomal aberrations [1, 3]. The longer the delay in starting TKI therapy, the more the cells exposed to genomic instability [5]. This finding suggests that *PML-RARA* clones may have already existed with the *BCR-ABL1* clone before the initiation of TKI therapy and may have multiplied rapidly during TKI therapy, which only killed the *BCR-ABL1* clone, although we could not confirm the presence of a *PML-RARA* clone in the sample used for primary diagnosis.

Among the reported four patients, three showed bleeding symptoms and accompanying DIC. Coagulopathy is frequently observed in APL and is associated with early death [7]. Thus, when CML patients show bleeding symptoms, early detection of disease progression and starting adequate treatment immediately are critical.

Few studies have reported APL with both *PML-RARA* and *BCR-ABL1* rearrangements [8, 9]. If a patient is primarily diagnosed as having APL with both *PML-RARA* and *BCR-ABL1* rearrangements, the possibility of progression of undiagnosed CML to promyelocytic BP, rather than *de novo* APL with both *PML-RARA* and *BCR-ABL1* rearrangements should be considered [10].



**Fig. 1.** Results of BM study, RT-qPCR, and FISH assay at the diagnosis of blast phase of CML. (A) Abnormal promyelocytes on a BM aspirate smear (Wright–Giemsa stain,  $\times 1,000$ ). (B) RT-qPCR analysis of *BCR-ABL1* translocation (HemaVision-28N, DNA Diagnostic, Risskov, Denmark), showing a 397-bp band in the M6B split-out PCR and a 353-bp band in the M8C split-out PCR, indicating *BCR-ABL1* (b3a2) and *PML-RARA* (bcr1 isoform) fusion transcripts. (C and D) FISH using a break-apart probe for *BCR-ABL1* and *PML-RARA* fusion genes (Cytocell, Cytocell Ltd, Oxford Gene Technology, Cambridge, UK) showed two fusion signals, one green and one red, suggesting both *BCR-ABL1* and *PML-RARA* rearrangements.

Abbreviations: BM, bone marrow; CML, chronic myeloid leukemia; FISH, fluorescence *in-situ* hybridization; RT-qPCR, quantitative reverse-transcription PCR.

In conclusion, disease progression of CML to promyelocytic BP should be considered when (1) *BCR-ABL1* and *PML-RARA* rearrangements are detected simultaneously and (2) sudden changes in leukocyte counts or bleeding symptoms occur despite TKI therapy, which could be an important clue suggesting disease progression to promyelocytic BP rather than adverse effects of TKI.

## ACKNOWLEDGEMENTS

None.

## AUTHOR CONTRIBUTIONS

Kim B designed the study and wrote the manuscript. Chi HY analyzed and interpreted the molecular tests. Yoon YA and Choi

YJ interpreted the results of laboratory tests and participated in discussion. All authors read and approved the final manuscript.

## CONFLICTS OF INTEREST

None declared.

## RESEARCH FUNDING

This study was supported by the Soonchunhyang University Research Fund.

## ORCID

Bohyun Kim  
Young Ahn Yoon

<https://orcid.org/0000-0003-4456-5612>  
<https://orcid.org/0000-0002-8284-6303>

Young-Jin Choi <https://orcid.org/0000-0002-7076-5725>  
Hyun Young Chi <https://orcid.org/0000-0002-5865-9292>

## REFERENCES

1. Chung HJ, Chi HS, Cho YU, Park CJ, Seo EJ, Kim KH, et al. Promyelocytic blast crisis of chronic myeloid leukemia during imatinib treatment. *Ann Clin Lab Sci* 2008;38:283-6.
2. Oku E, Imamura R, Nagata S, Takata Y, Seki R, Otsubo K, et al. Promyelocytic crisis of chronic myelogenous leukaemia during imatinib mesylate treatment. *Acta Haematol* 2007;117:191-6.
3. Hoehn D, Lu G, Konoplev S, Zhou Y, Bueso-Ramos CE, Zuo Z, et al. t(15;17)(q24.1;q21.2)/PML-RARA in blast phase of chronic myelogenous leukemia: a rare form of clonal evolution. *J Hematopathol* 2012;6:187-93.
4. Taylor FB, Jr., Toh CH, Hoots WK, Wada H, Levi M. Towards definition, clinical and laboratory criteria, and a scoring system for disseminated intravascular coagulation. *Thromb Haemost* 2001;86:1327-30.
5. Radich JP. The biology of CML blast crisis. *Hematology Am Soc Hematol Educ Program* 2007:384-91.
6. Saußele S and Silver RT. Management of chronic myeloid leukemia in blast crisis. *Ann Hematol* 2015;94(S2):S159-65.
7. Breen KA, Grimwade D, Hunt BJ. The pathogenesis and management of the coagulopathy of acute promyelocytic leukaemia. *Br J Haematol* 2012;156:24-36.
8. An GD, Lim HH, Woo KS, Kim KH, Kim JM, Kim SH, et al. A case of acute promyelocytic leukemia with co-existence of *BCR-ABL1* and *PML-RARA* rearrangements detected by PCR. *Lab Med Online* 2017;7:196-200.
9. Sun X, He Y, Mao C, Zhu L, Qin X, Huang S. BCR/ABL fusion gene detected in acute promyelocytic leukemia: a case study of clinical and laboratory results. *Leuk Lymphoma* 2014;55:435-8.
10. Chung H, Hur M, Yoon S, Hwang K, Lim H, Kim H et al. Performance evaluation of the QXDx *BCR-ABL* %IS droplet digital PCR assay. *Ann Lab Med* 2020;40:72-5.