

CASE REPORT

Inferior vena caval filter strut perforation causing intramural duodenal haematoma

Zoheb Berry Williams^{1,*}, Nicole M. Organ¹, and Stephen Deane²¹Department of Vascular Surgery, John Hunter Hospital, Lookout Road, New Lambton NSW 2305, Australia and²Department of Surgery, John Hunter Hospital, Lookout Road, New Lambton NSW 2305, Australia*Correspondence address. Department of Vascular Surgery, John Hunter Hospital, Lookout Road, New Lambton NSW 2305, Australia.
Tel: +61 02 4921 3000; E-mail: zohebw@gmail.com

Abstract

We present a case of intramural duodenal haematoma caused by inferior vena caval (IVC) filter strut perforation requiring innovative open and endovascular retrieval. A 32-year-old woman presents in shock with dull epigastric pain and non-bilious vomiting. She had previously had an IVC filter for deep venous thrombosis and pulmonary embolism. Computed tomography demonstrated strut perforation into the second part of the duodenum, causing intramural haematoma and duodenal obstruction. Laparotomy facilitated evacuation of the duodenal haematoma, while the IVC filter was retrieved by endovascular means. Causes of duodenal haematoma include blunt trauma, haematologic malignancy, coagulopathy, percutaneous or endoscopic procedures, pancreatic pathology, peptic ulcer disease and aortoenteric fistula. Duodenal haematoma is rare and is usually managed conservatively or by percutaneous drainage. While this patient had a typical presentation, IVC filter strut perforation has not been described in the literature as a cause for duodenal haematoma.

INTRODUCTION

Duodenal haematoma rare. It is often caused by blunt trauma, haematologic malignancy, coagulopathy and percutaneous or endoscopic procedure. It is also usually suitable for conservative management or percutaneous drainage. We present a case of intramural duodenal haematoma caused by inferior vena caval (IVC) filter strut perforation managed by laparotomy and endovascular filter retrieval. This cause of duodenal haematoma is not repeated in the world literature to our knowledge.

PRESENTATION OF CASE

A 32-year-old woman presented with a 24-hour history of constant dull epigastric pain, nausea and non-bilious vomiting. This was her second similar presentation to the emergency

department within 24 hours. She denied any abdominal trauma. Her background was significant for Bechet's disease and Takayasu's arteritis, which required immunosuppression with mycophenolate and prednisone, peptic ulcer disease, aortic valve replacement, hypertension, aorto-iliac bypass with visceral and renal revascularization for severe chronic visceral and lower limb ischaemia 12 months ago, she had an infrarenal IVC filter (Celect, COOK) placed at that time because of a history of deep venous thrombosis and pulmonary embolism.

She had suffered an episode of septic pulmonary emboli with methicillin-sensitive staphylococcus aureus septicaemia. At the time of this event tomography and a gallium white cell scan revealed tilting of the IVC filter with strut perforation through the IVC and into the third part of the duodenum but no evidence of filter or bypass graft infection.

Received: August 28, 2016. Accepted: October 2, 2016

Published by Oxford University Press and JSCR Publishing Ltd. All rights reserved. ©The Author 2016.

This is an Open Access article distributed under the terms of the Creative Commons Attribution Non-Commercial License (<http://creativecommons.org/licenses/by-nc/4.0/>), which permits non-commercial re-use, distribution, and reproduction in any medium, provided the original work is properly cited. For commercial re-use, please contact journals.permissions@oup.com

Current physical examination revealed a pale female in some distress. Her blood pressure was 80/40, heart rate 80 (with beta blockade). Her abdomen was firm with a tender epigastrium. There were no palpable masses. There was no percussion tenderness. Laboratory tests revealed a haemoglobin of 86 g/L and an international normalized ratio (INR) of 4.3; these had changed from 132 g/L and 3.3, respectively, the previous evening. Her white cell count was 27.8 (neutrophils 22.6) $\times 10^9/L$, pH 7.44 and potassium of 3.1 mmol/L. Computed tomography (CT) revealed filter strut perforation into the third part of the duodenum (Figs 1 and 2) with a large intramural haematoma of the second and

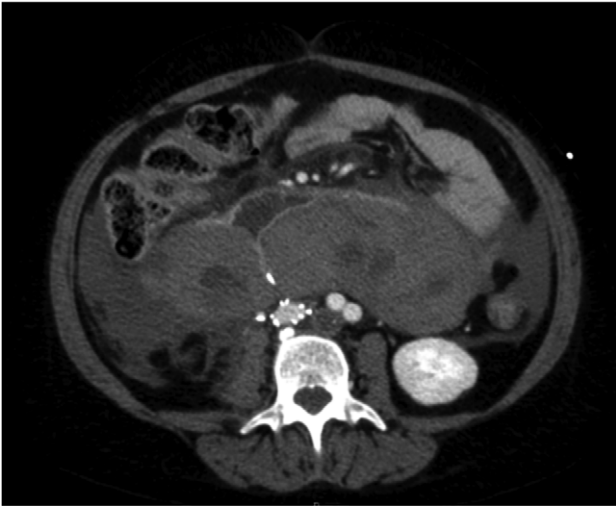


Figure 1: A venous phase abdominal CT demonstrating the end of the IVC filter strut penetrating the wall of the third part of the duodenum.

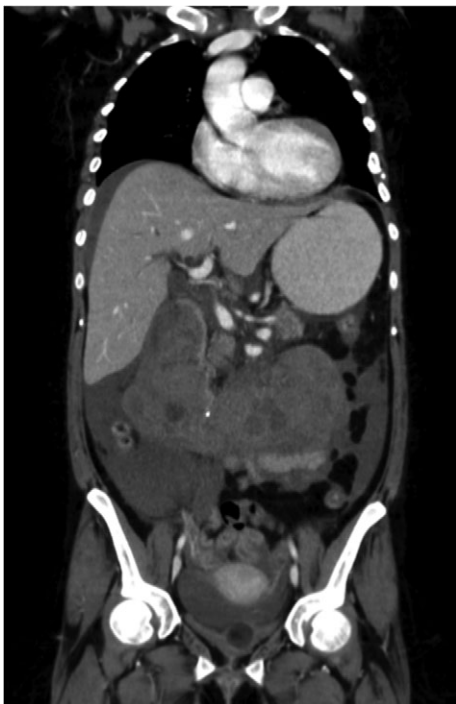

Figure 2: A coronal section of a venous phase abdominal CT demonstrating the end of the IVC filter strut penetrating the wall of the third part of the duodenum.

third parts, obstructing the duodenal lumen. There was pneumatosis of the duodenal wall, haemoperitoneum and free blood.

The patient's coagulopathy was treated and she underwent a laparotomy and evacuation of a large duodenal haematoma. After division of adhesions, a tense duodenal wall was revealed with splitting of the serosal layer. A large haematoma, of about 500 mls volume, was removed from the subserosal layer without breach of the muscularis. The penetrating strut of the IVC filter was able to be palpated within the duodenal wall but was not on view after haematoma removal. There was considerable inflammation of the retroperitoneum as well as scarring from the previous arterial bypass surgery. There was no contamination of the peritoneum with bowel contents. It was thought preferable to remove the IVC filter via the transvenous route rather than expose the IVC and risk large blood loss and arterial graft contamination in the event of duodenotomy.

The IVC filter was removed by endovascular means the next day. The procedure was challenging due to excessive tilting of the filter, causing the retrieval hook to appear outside the vessel lumen on venography (Fig. 3). The hook may have been encased in fibrin or within a venous tributary. Retrieval required a careful combination of snares, graspers and balloons to manipulate the filter into a position where the retrieval hook could be snared. Retrieval was successful and without complications.

Post operatively the patient's anticoagulation was gradually reintroduced and she made a steady and uncomplicated recovery.

DISCUSSION

Duodenal intramural haematoma can occur secondary to blunt abdominal trauma and this is the most common cause particularly in the paediatric population. Other causes include coagulopathy (inherited and acquired), haematological malignancies, mesenteric venous obstruction, endoscopic procedures, percutaneous drainage procedures, pancreatic pathology, peptic ulcer disease and aortoenteric fistula [1-3]. Bleeding is thought to occur in the submucosal layer [3]. There have been no reports in

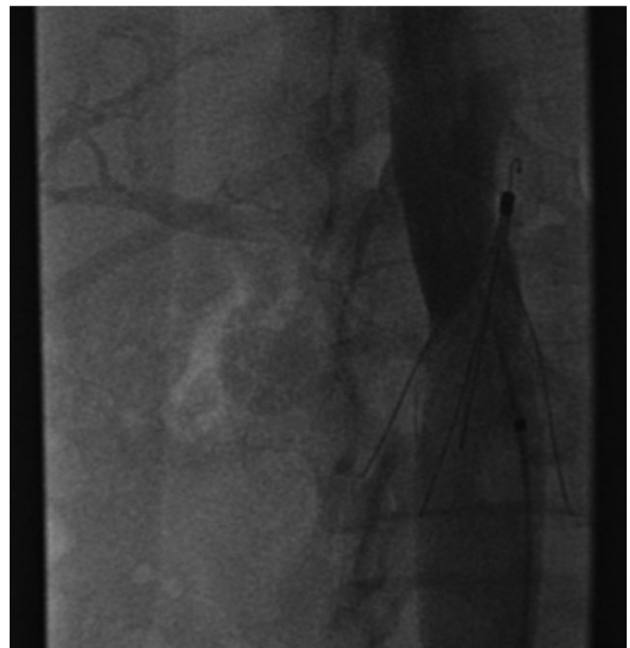

Figure 3: Excessive tilting of the IVC filter causes the hook of the filter to appear outside of the lumen of the IVC.

the literature to our knowledge of IVC filter penetration into the duodenum resulting in a duodenal intramural haematoma. This patient was on warfarin with an INR on presentation of 3.3. This alone may have contributed to her risk of duodenal haematoma.

Duodenal haematoma commonly presents with upper gastrointestinal tract obstruction with abdominal pain and non-bilious vomiting. Other clinical features may include bilious vomiting and obstructive jaundice [3, 4]. The differential diagnosis includes malignancy and there has been one report of a ruptured choledochal cyst being misdiagnosed as a duodenal haematoma [5]. Management is usually non-operative unless there are complicating circumstances [3]. In this case there was free peritoneal blood and a raised white cell count causing concern about duodenal perforation and ongoing bleeding prompting a laparotomy. Conservative therapy with CT or endoscopic guided drainage of the haematoma have also been described [6-8]. In our case, the haematoma consisted of a very firm solid clot under pressure. Non-operative management often requires intravenous nutrition while awaiting clot reabsorption.

Duodenal haematoma has a number of documented causes. We present an unusual case in a complicated patient who required an innovative combination of open surgery and endovascular techniques to achieve a good outcome. Endovascular filter removal can be achieved without bleeding complication even when significant tilting and perforation is present.

ACKNOWLEDGEMENTS

Nil.

CONFLICTS OF INTEREST STATEMENT

None declared.

REFERENCES

1. Zeppa MA, Forrest JV. Aortoenteric fistula manifested as an intramural duodenal haematoma. *Am J Roentgenol* 1991;157:47-8.
2. Ahn MS, Miyai K. Intramural duodenal haematoma presenting as a complication of peptic ulcer disease. *J Clin Gastroenterol* 2001;33:53-5.
3. Weil BR, Howard TJ, Zyromski NJ. Spontaneous duodenal haematoma: a rare cause of upper gastrointestinal tract obstruction. *Arch Surg* 2008;143:794-6.
4. Shih SL, Lin JC, Lee HC, Blickman JG. Unusual causes of obstructive jaundice in children: diagnosis on CT. *Pediatr Radiol* 1992;22:512-4.
5. Garrison AP, Weiner T, Lange P. Traumatic rupture of a choledochal cyst masking as a duodenal haematoma. *Paediatr Surg Int* 2008;24:1247-9.
6. Hanish SI, Pappas TN. CT guided drainage of a duodenal haematoma after trauma. *J Trauma* 2007;63:E10-2.
7. Banieghbal B, Vermaak C, Beale P. Laparoscopic drainage of a post-traumatic intramural duodenal haematoma in a child. *J Laparoendosc Adv Surg Tech A* 2008;18:469-72.
8. Yang JC, Rivard DC, Morello FP, Ostlie DJ. Successful percutaneous drainage of duodenal hematoma after blunt trauma. *J Paediatr Surg* 2008;43:e13-5.