



Original Research

Thoracoscopic Resection in the Treatment of Spontaneous Pneumothorax

Mesut Demir, Melih Akın, Meltem Kaba, Şeyma Filiz, Nihat Sever, Çetin Ali Karadağ,
 Ali İhsan Dokucu

Department of Pediatric Surgery, Sisli Hamidiye Etfal Training and Research Hospital, Istanbul, Turkey

Abstract

Objectives: We retrospectively evaluated the patients with primer spontaneous pneumothorax (PSP) who were treated with thoracoscopic resection.

Methods: We retrospectively collected the data of the patients with a spontaneous pneumothorax who were operated with video-assisted thoracoscopic surgery (VATS) between 2010 and 2016.

Results: During the study period, 10 patients applied to our hospital with spontaneous pneumothorax. Five children (three boys, two girls) with a mean age of 16.6 (16-17) were selected with VATS. Three of the patients had bleb, one of the patients had Congenital Cystic Adenomatoid Malformation (CCAM) type 2, and the last one had chronic emphysematous tissue on pathological analyses. Post-operative follow-up time was 2.2 (1-4) years without any complication.

Conclusion: Spontaneous pneumothorax is a disease especially seen in puberty. The main reasons are apical segment bullae formation and blebs. VATS is especially advantageous to reach apical segments and for easy resections. Blebs, CCAM and emphysematous lung tissue may cause spontaneous pneumothorax.

Keywords: Bleb; primer spontaneous pneumothorax; video-assisted thoracoscopic surgery.

Please cite this article as "Demir M, Akın M, Kaba M, Filiz Ş, Sever N, Karadağ ÇA, Dokucu Aİ. Thoracoscopic Resection in the Treatment of Spontaneous Pneumothorax. Med Bull Sisli Etfal Hosp 2020;54(1):94-97".

Primary Spontaneous Pneumothorax (PSP) is a rare disease of childhood. PSP is seen with an incidence rate of 1/3.400.000 and more frequently in men.^[1,2] PSP recurs in 30% of the patients after conservative treatment. In some series, this rate has been reported to be 50-60%.^[3] Conservative treatment is performed with the application of a chest tube. Treatment of PSPs is still controversial today.^[4,5]

Video-assisted thoracoscopic surgery (VATS) has gained popularity in the diagnosis and treatment of PSP in the last 10 years. Thanks to thoracoscopy, lesions that cause

PSP can be identified, and surgical treatment can be performed. Today, VATS has begun to replace open surgery in the treatment of PSP. Bulla resections with VATS, pleural abrasion and pleurectomy are successfully performed in the treatment of PSP.^[6] We retrospectively evaluated our patients who underwent thoracoscopic resection with the indication of the PSP based on their medical records.

Methods

In this study, we retrospectively evaluated PSP patients we treated with VATS between 2010 and 2016. In all our

Address for correspondence: Mesut Demir, MD. Sisli Hamidiye Etfal Egitim ve Arastirma Hastanesi, Cocuk Cerrahisi Klinigi, Istanbul, Turkey

Phone: +90 532 362 04 38 **E-mail:** dr.mesut.demir@gmail.com

Submitted Date: July 19, 2018 **Accepted Date:** July 23, 2018 **Available Online Date:** March 25, 2020

©Copyright 2019 by The Medical Bulletin of Sisli Etfal Hospital - Available online at www.sislietfaltip.org

OPEN ACCESS This is an open access article under the CC BY-NC license (<http://creativecommons.org/licenses/by-nc/4.0/>).



patients, the diagnosis of PSP was determined by chest radiography. Thorax tube was inserted to all patients with pneumothorax larger than 2 cm. Surgical indications were applied to patients with air leakage persisting for more than 48 hours. Other surgical indications are recurrent ipsilateral side pneumothorax presence of previous contralateral pneumothorax and persistent air leakage.

The VATS procedure was performed using double or single- lumen endotracheal intubation (ET) depending on the experience of the anesthesiologist under general anesthesia with the patient in the lateral decubitus position (Fig. 1). Two 5 mm and one 15 mm ports were used. Resections were performed with the help of a stapler in patients with bulla (Fig. 2). Postoperatively a chest tube was placed. After discharge, patients were followed up for pneumothorax that may develop on the same or contralateral side (Fig. 3).

Results

During the study period, 10 patients applied to our hospital due to spontaneous pneumothorax. Five children (three boys and two girls) with an average age of 16.6 (16-17 years) were operated with VATS. Computed tomography

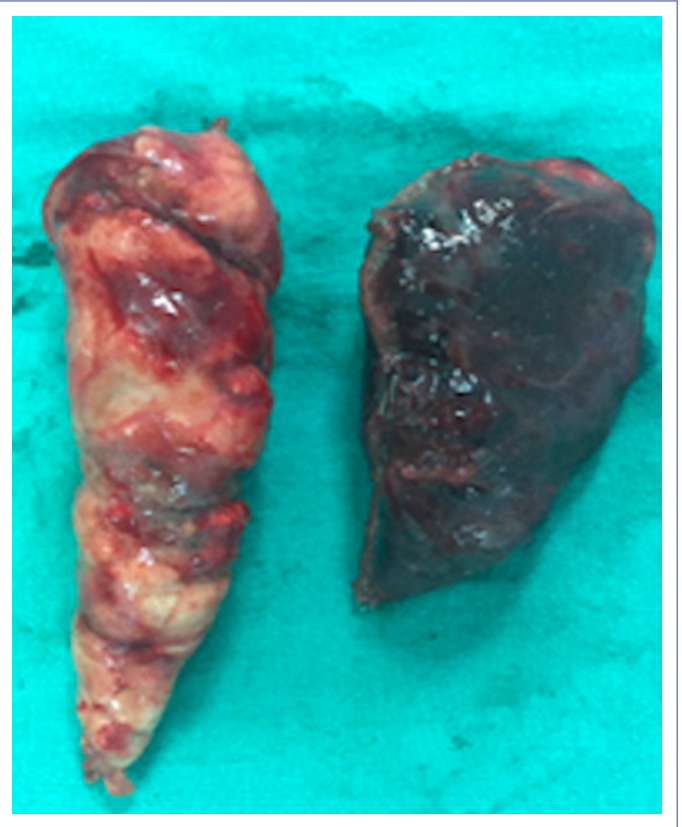


Figure 2. Lung resection material.

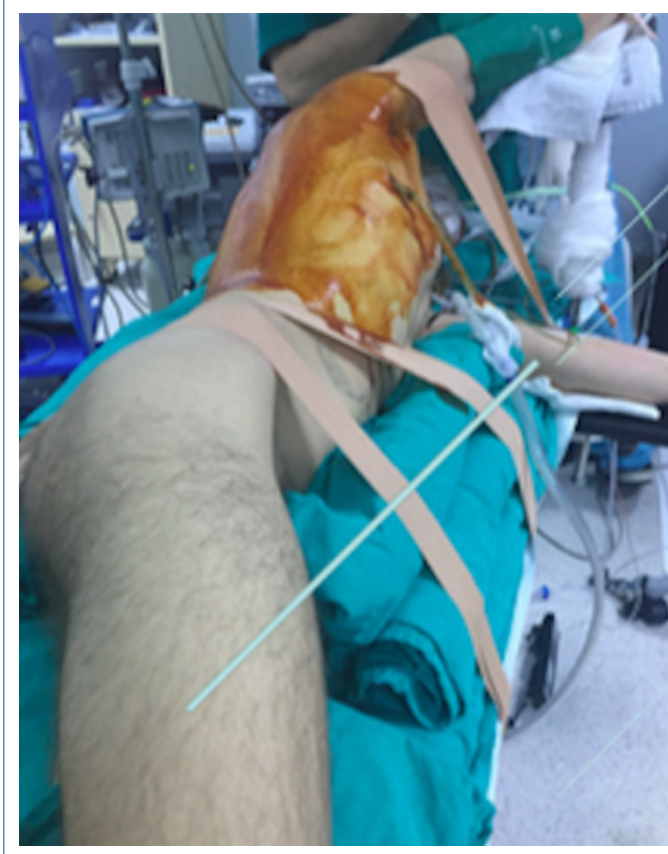

Figure 1. The patient's position.

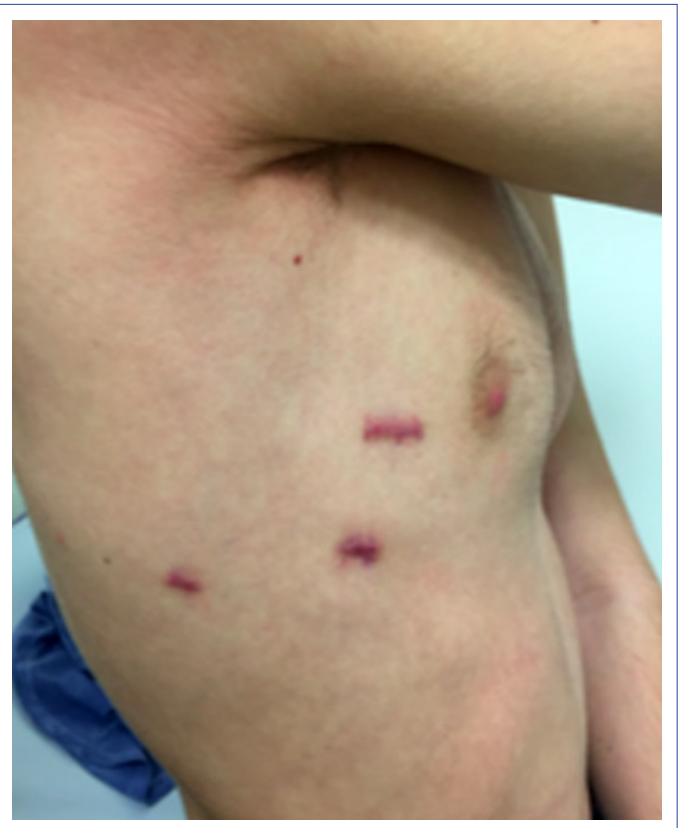

Figure 3. Postoperative appearance.

(CT) showed bulla formation in the apical region in two patients and in the superior segment of the inferior lobe in one patient (Fig. 4). All patients with persistent air leaks in tube thoracostomy were operated with VATS, and staples were used for resection. Apical lobe resection was applied in one patient due to bulla formation. The mean postoperative duration of tube thoracostomy was 3.3 (3-5 days) days. Three patients had a bulla, one patient had Congenital Cystic Adenomatoid Malformation (CCAM) type 2, and the third one had chronic emphysematous tissue detected during the pathological examination. The postoperative follow-up period was 2.2 (1-4 years) years without any complications.

Discussion

PSP is a life-threatening disease in adolescents and asthenic-looking adults.^[7] Diagnosis is usually made by chest radiography. CT is a necessary and useful test to demonstrate the presence and etiology of the bulla.^[8] The recurrence rate in patients treated with a chest tube is high (30-60%).^[9] Definitive therapy is successfully applied with VATS, which is gaining popularity nowadays.^[6] With thoracoscopy, apical segments of the lung can be easily seen. With the developments in the medical materials used, resections can be made with staples at angles appropriate to the desired region.

Pleural abrasion and pleurectomy procedures can be performed with VATS. Although these procedures reduce the rate of recurrence, they cause local adhesions and development of serious hematoma, especially after pleurectomy. Severe bleeding may occur in reoperations due to the presence of large vessels in this region. Thus, we prefer to perform the only resection in our clinic and conduct a

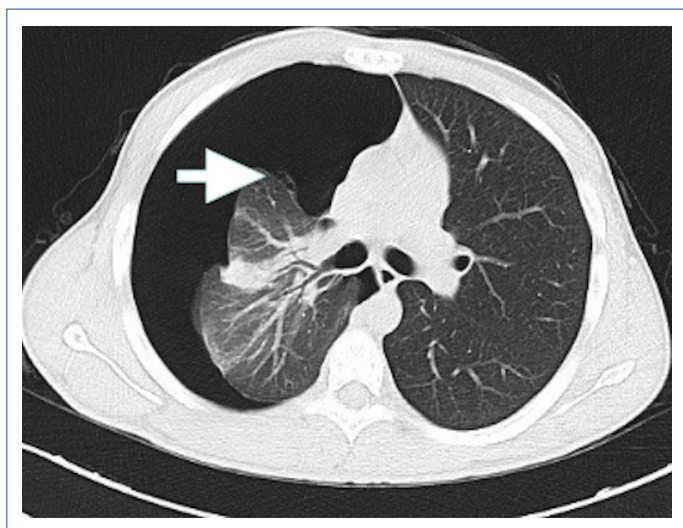


Figure 4. CT image of the bleb.

long term close follow-up instead of adding abrasion and pleurectomy procedures. Our follow-up period was 2.2 years (1-4 years). During this period, none of our patients developed recurrence. The reason for the development of PSP maybe not only bulla formation but also CCAM and emphysema.^[12] In one of our patients, we detected CCAM Type 2 and emphysema in resection material.

As a result, VATS is safe in pediatric patients with PSP and is frequently preferred today. Lung resection for etiology without pleurodesis and pleurectomy is an effective method in the treatment of PSP.^[13] Long-term follow-up of these patients should be made concerning detecting recurrence and pneumothorax that may develop on the contralateral side.

Disclosures

Ethics Committee Approval: Retrospective study.

Peer-review: Externally peer-reviewed.

Conflict of Interest: None declared.

Authorship Contributions: Concept – M.A., M.K.; Design – Ş.F.; Supervision – M.D., M.A.; Materials – Ç.A.K.; Data collection &/or processing – N.S.; Analysis and/or interpretation – M.D., A.İ.D.; Literature search – M.D., M.A.; Writing – M.D., M.A.; Critical review – A.İ.D.

References

1. Sahn SA, Heffner JE. Spontaneous pneumothorax. *N Engl J Med* 2000;342:868–74.
2. Dotson K, Timm N, Gittelman M. Is spontaneous pneumothorax really a pediatric problem? A national perspective. *Pediatr Emerg Care* 2012;28:340–4.
3. Bialas RC, Weiner TM, Phillips JD. Video-assisted thoracic surgery for primary spontaneous pneumothorax in children: is there an optimal technique?. *J Pediatr Surg* 2008;43:2151–5.
4. Henry M, Arnold T, Harvey J; Pleural Diseases Group, Standards of Care Committee, British Thoracic Society. BTS guidelines for the management of spontaneous pneumothorax. *Thorax* 2003;58 Suppl 2:ii39–52.
5. Baumann MH, Strange C, Heffner JE, Light R, Kirby TJ, Klein J, et al; AACP Pneumothorax Consensus Group. Management of spontaneous pneumothorax: an American College of Chest Physicians Delphi consensus statement. *Chest* 2001;119:590–602.
6. Tschopp JM, Bintcliffe O, Astoul P, Canalis E, Driesen P, Janssen J, et al. ERS task force statement: diagnosis and treatment of primary spontaneous pneumothorax. *Eur Respir J* 2015;46:321–35.
7. Light RW. *Pleural diseases*. 3rd ed. Baltimore: Williams and Wilkins; 1995.
8. Young Choi S, Beom Park C, Wha Song S, Hwan Kim Y, Cheol Jeong S, Soo Kim K, et al. What factors predict recurrence after an initial episode of primary spontaneous pneumothorax in children? *Ann*

- Thorac Cardiovasc Surg 2014;20:961–7.
9. Ciriaco P, Muriana P, Bandiera A, Carretta A, Melloni G, Negri G, et al. Video-assisted thoracoscopic treatment of primary spontaneous pneumothorax in older children and adolescents. *Pediatr Pulmonol* 2016;51:713–6.
 10. Robinson PD, Cooper P, Ranganathan SC. Evidence-based management of paediatric primary spontaneous pneumothorax. *Paediatr Respir Rev* 2009;10:110–7.
 11. Rokicki W, Rokicki M, Wojtacha J, Filipowski M, Dzejli A, Czyżewski D. Is it possible to standardize the treatment of primary spontaneous pneumothorax? Part 2: surgical methods of treatment. *Kardiochir Torakochirurgia Pol* 2016;13:328–33.
 12. Civelek Z, Dalgiç N, Tanik C, Ertürk ŞM, Akın M, Kafadar İ. Congenital cystic adenomatoid malformation diagnosed during adolescence. *Med Bull Sisli Etfal Hosp* 2017;51:247–51.
 13. Zhang Z, Du L, Feng H, Liang C, Liu D. Pleural abrasion should not routinely be preferred in treatment of primary spontaneous pneumothorax. *J Thorac Dis* 2017;9:1119–25.