

RESEARCH

Open Access



# Application of unicompartmental knee arthroplasty in the treatment of knee osteoarthritis

Bing Wang, Haining Sun\*, Zhihou Fu, Jian Kang and Xiuchun Yu

## Abstract

**Objective:** For the treatment of medial compartment knee osteoarthritis, unicompartmental knee arthroplasty was chosen on the basis of the clinical effects and the rate of prosthesis survival. A retrospective analysis was performed on 500 patients with osteoarthritis of the medial compartment knee treated by unicompartmental knee arthroplasty between April 2007 and April 2017. The cohort was comprised of 176 males and 324 females, aged ( $61.12 \pm 8.0$ ) years old. The clinical treatment was evaluated in terms of the range of movement (ROM), the Knee Society score (KSS), and the Oxford knee score.

**Results:** The follow-up lasted 1.59–11.60 years. Grouped in terms of age, 133 cases were in the middle-age, 295 were in the old-age group, and 72 in the advanced-age group. Against the Iwano classification of the patellofemoral joint, 104 cases were graded 0–1; 179 were graded 2; 182 were graded 3 and 35 were graded 4. The KSS score improved from ( $59 \pm 5.6$ ) points before the operation to ( $93 \pm 3.5$ ) points after the operation. The OKS score increased from ( $24 \pm 2.4$ ) points before the operation to ( $45 \pm 3.8$ ) points after the operation. The ROM of knee joint was ( $111 \pm 6.8$ )° before the operation and was ( $117 \pm 9.7$ )° after the operation. The 10-year survival rate of the prosthesis was 96%.

**Conclusion:** UKA is one of the treatments for medial compartmental knee osteoarthritis. The issues, such as age and patellofemoral joint degeneration, can be addressed by careful selection of patients and precise operational manipulation.

**Keywords:** Arthroplasty, Replacement, knee, Unicompartmental knee arthroplasty, Long term adverse effects

## Background

Osteoarthritis (OA) of the knee represents one of the most common diseases among middle-aged and elderly people, and tends to involve the medial compartment of the knee joint [1]. Since McKeever [2] first proposed the concept of unicompartmental knee arthroplasty (UKA) in 1955, the metal prosthesis of unilateral tibial plateau has been inserted into the diseased joint compartment to treat OA. Initially, UKA had a high failure rate [3, 4]. Since 1970s, Goodfellow et al. designed the Oxford unicompartmental knee prosthesis, which consists of a spherical femoral, a flat tibial, and a mobile meniscal

bearing [5–7]. In recent years, the Oxford UKA (OUKA) exhibited a clinical effect similar to that of total knee arthroplasty [8–11].

The OUKA only involves the single compartment of the knee and retains the bone mass and ligament function of the joint. It goes well with minimally invasive incision and restores the knee joint function early and quickly [12]. Some clinical studies have confirmed that UKA reduces pain and improves the range of motion (ROM) and joint function of the knee, with significant short- and medium-term clinical efficacy [13, 14]. The unconstrained design of OUKA allows rotation and translation, which ensures a large contact area of the prosthesis and reduces the stress between the prostheses, thereby minimizing the wear and prolonging the survival

\* Correspondence: [68287257@qq.com](mailto:68287257@qq.com)  
Department of Orthopedic, The 960 Hospital of PLA, 250031 Jinan, China



© The Author(s). 2021 **Open Access** This article is licensed under a Creative Commons Attribution 4.0 International License, which permits use, sharing, adaptation, distribution and reproduction in any medium or format, as long as you give appropriate credit to the original author(s) and the source, provide a link to the Creative Commons licence, and indicate if changes were made. The images or other third party material in this article are included in the article's Creative Commons licence, unless indicated otherwise in a credit line to the material. If material is not included in the article's Creative Commons licence and your intended use is not permitted by statutory regulation or exceeds the permitted use, you will need to obtain permission directly from the copyright holder. To view a copy of this licence, visit <http://creativecommons.org/licenses/by/4.0/>.

time. Price and Svard et al. reported that the 10-, 15-, and 20-year survival rates of OUKA prosthesis were 95%, 93.1%, and 91%, respectively [15–17]. Pandit et al. reported a 10-year survival rate of 94% and a 15-year survival rate of 91% in 1000 OUKA prostheses [18, 19].

However, the indications, complications, and prosthesis revision rate of the OUKA remain controversial [20–23]. The selection of the patients is a major factor affecting the survival rate of the prosthesis [24–26]. In 1989, Kozinn and Scott [27], for the first time, proposed the surgical indications for the UKA. Although these indications lack support of sufficient clinical data, they are currently in use. They include: (1) OA or osteonecrosis is confined to one compartment; (2) Low activity requirements; (3) Body weight < 82 kg; (4) Age > 60-year-old; (5) Slight pain in the affected knee joint at rest; (6) Scope of the knee joint flexion and extension > 90°; (7) Flexion contracture deformity < 5°; (8) Inside the knee, valgus < 15° and can be corrected. The indications for this operation are conservative. With the continuous improvement in the design of prosthesis and the perfection of the surgical techniques, the aforementioned indications can be expanded further. This retrospective study analyzed the long-term follow-up results of 500 patients with KO treated by OUKA and explored the indications, clinical effect, and prosthesis survival rate of OUKA.

## Materials and methods

**Inclusion criteria:** (1) The patients were diagnosed as having osteoarthritis of knee; (2) Preoperative imaging confirmed the onset of medial compartmental osteoarthritis of the knee (Ahlback radiographic investigation, grade 2–3 [28]), with the whole cartilage of lateral compartment still present, and the degree of patellofemoral joint degeneration was not taken as the evaluation standard; (3) Painful medial compartmental osteoarthritis without prepatellar pain or with mild prepatellar pain; (4) Anterior cruciate ligament and medial collateral ligament function was intact, allowing partial injury of the ligament surface; (5) The flexion deformity of the knee joint was < 15°, varus deformity was allowed but must be corrected for knee flexion; (6) Age and weight were not used as the selection criteria. The aforementioned criteria were similar to those proposed by the OUKA prosthesis design team when they reported the long-term survival of patients with a prosthesis [7].

**Exclusion criteria:** (1) Concurrently having other joint diseases, such as rheumatoid arthritis, joint infection, joint tuberculosis, bone tumor, and acute phase of intra-articular fracture; (2) Having degeneration of the lateral compartment of the knee joint or with concurrent severe deformity of the knee joint; (3) Patients had received ipsilateral knee osteotomy or joint replacement; (4) Patients could not tolerate surgery.

From April 2007 to April 2017, a total of 522 patients with knee osteoarthritis were treated with OUKA. According to the above-mentioned criteria, 500 cases of UKA surgery were included in this study. The third generation of Oxford mobile-bearing prosthesis system (Biomet Ltd., Bridgend, UK) was selected for all patients. The cohort was comprised of 176 (35.2%) males and 324 (64.8%) females, with the average age being (61.12 ± 8.0) years (range, 43–91). The patients were divided into three groups according to the age: a middle age group (< 55 years old), an old-age group (55–70 years old), and an advanced-age group (> 70 years-old). The body mass index (BMI) was (23.7 ± 4.2) kg/m<sup>2</sup> (range, 19.3–35.6 kg/m<sup>2</sup>). The unilateral replacement was performed in 400 cases (80.0%), including 205 cases of the right knee (41.0%) and 195 cases of the left knee (39.0%). The bilateral replacement was done in 88 cases (17.6%). One side received OUKA and the other side received TKA in 12 cases (2.4%). Iwano et al. [29] proposed a 0–4 scale for imaging assessment of patellofemoral joint degeneration on the basis of the axial X-ray of the patellofemoral joint (Grade 1: Joint-space narrowing is mild, in which the joint space is > 3mm. Grade 2: Joint-space narrowing is moderate, in which the joint space is < 3mm, but there is no bony contact. Grade 3: Joint-space narrowing is severe, in which the bone on bone area is < 1/4 of the joint surface. Grade 4: Joint-space narrowing is severe, the joint bony surfaces touch each other).

In all patients, operation was performed by the same group of surgeons. These patients were reviewed by a non-surgical medical team 1 month, 3 months, and 1 year after operation. The ROM, the Knee Society score (KSS) [30], and Oxford knee score (OKS) [31] were recorded to evaluate the clinical effect. All complications following surgery were recorded.

Descriptive statistics were used for data analysis. Kaplan-Meier survival analysis was employed for the evaluation of the prosthesis survival rate at different ages and the degree of patellofemoral joint degeneration. The revision of prosthesis for any reason was used as the endpoint, including replacement or removal of any component of the prosthesis. Two-sided independent sample *t*-test was utilized to compare the pre- or postoperative ROM, KSS, OKS. One-way analysis of variance (ANOVA) was used to compare postoperative ROM, KSS, and OKS between different age groups and patellofemoral joint degeneration groups. A *p* < 0.05 indicated a statistically significant difference. Statistical analysis was performed using SPSS statistical software (version 19.0, SPSS Inc., IBM Co., USA).

## Results

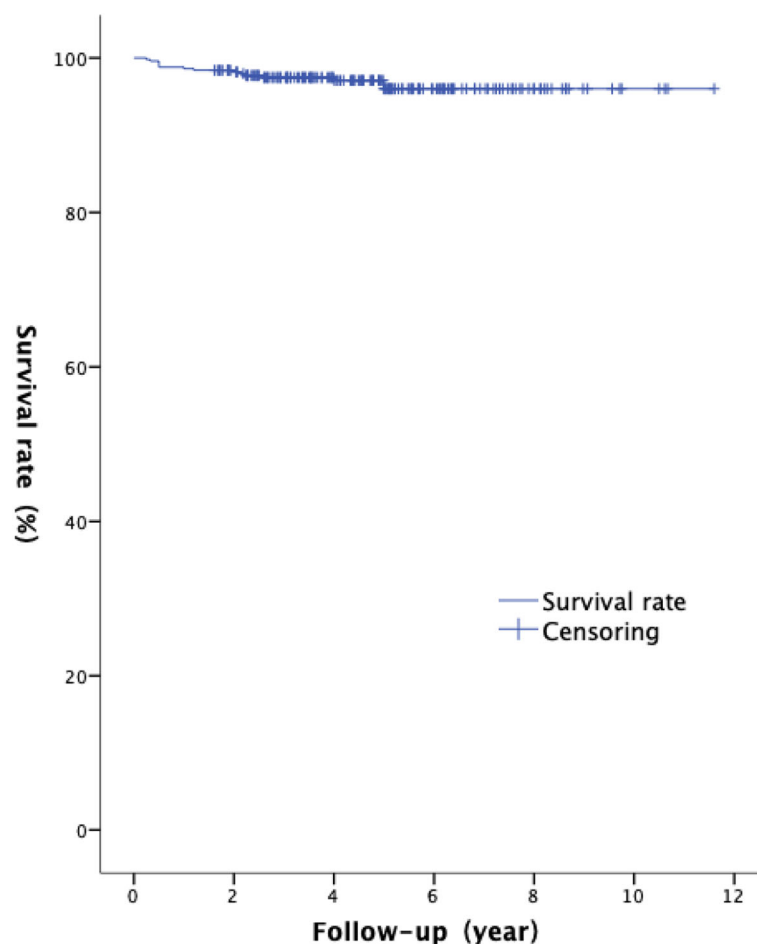
The 500 patients recruited in this study were followed up for 1.59–11.60 years (average: 5.27 years). The last follow-up was in November 2018. In terms of age, 133

(26.6%) cases were in the middle-age group, 295 (59.0%) in the old-age group, and 72 (14.4%) in the advanced-age group. Against the Iwano imaging classification, 104 cases (20.8%) were rated 0–1; 179 cases (35.8%) were rated 2, 182 cases (36.4%) were rated 3 and 35 (7.0%) were rated 4. The KSS score was improved from ( $59 \pm 5.6$ ) preoperatively to ( $93 \pm 3.5$ ) postoperatively ( $t = -2.586$ ,  $p < 0.05$ ). The OKS score increased from ( $24 \pm 2.4$ ) preoperatively to ( $45 \pm 3.8$ ) postoperatively ( $t = -2.056$ ,  $p < 0.05$ ). The average preoperative ROM of the knee joint was ( $111 \pm 6.8$ )°, and the postoperative ROM was ( $117 \pm 9.7$ )° ( $t = -2.334$ ,  $p < 0.05$ ).

The 10-year survival rate of the prosthesis was 96.0% (Fig. 1). Among the 500 patients, 20 (4%) developed complications, and 12 (2.4%) had the highest bearing dislocation rate. Of the 12 cases of bearing dislocation, 6 was due to the excessive flexion of the knee caused by injury, 3 due to the severe wear of bearing, 2 due to aseptic loosening of the femoral component, and 1 due to postoperative laxity of the anterior cruciate ligament. Furthermore, 9 of the 12 bearing dislocation cases were

treated with replacement of the thick bearing, and 2 cases of loosening femoral component were treated with femoral component revision. In addition, the one case of function loss of anterior cruciate ligament was treated with a total knee prosthesis revision. The postoperative dislocation of the bearing occurred between 0.25 and 5 (average, 2.1) years.

Other complications included delayed deep infection in 1 patient (0.2%) and the infection developed 2 years after surgery and was treated by cement spacer and staged total knee arthroplasty. Moreover, 4 cases (0.8%) had loosening of the femoral component of the prosthesis (including 2 cases of bearing dislocation), of which 3 underwent revision of femoral component and 1 received total knee arthroplasty. In 2 cases, prosthesis loosening resulted from spontaneous osteonecrosis of the knee (SONK). Two patients (0.4%) developed repeated aseptic hydrops in the joint and recovered after knee puncture and physical therapy. 2 cases (0.4%) had a bony free body from the osteophyte in the joint, which was removed by arthroscopic surgery, and 1 patient (0.2%) suffered from postoperative



**Fig. 1** Kaplan-Meier survival analysis, 10-year survival rate is 96%

knee joint pain of unknown origin, which subsided after conservative treatment and rehabilitation exercise.

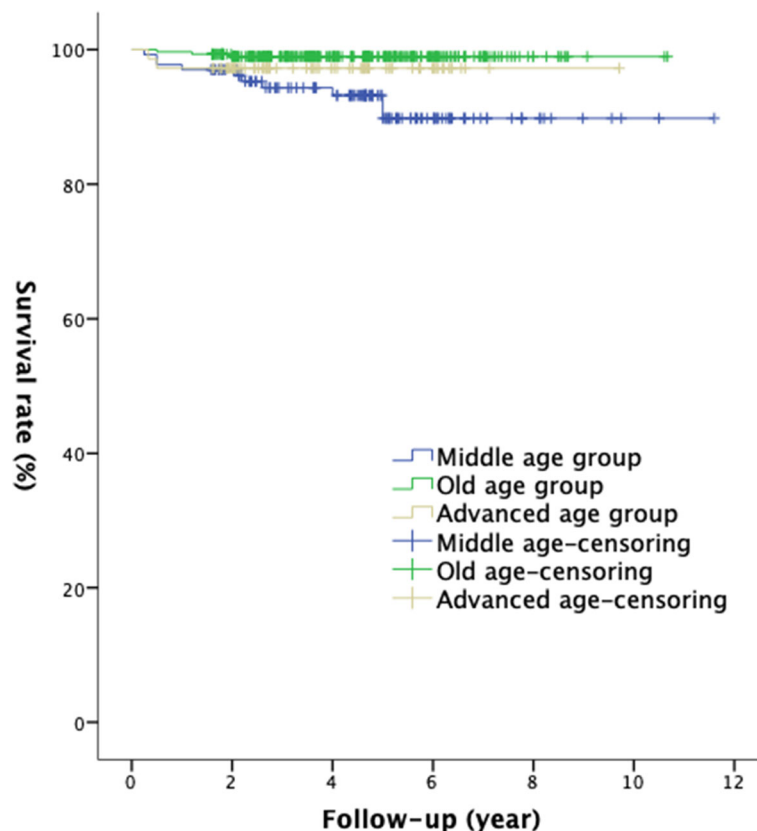
The 10-year prosthesis survival rate was 89.8% in the middle-age group ( $n = 133$ ), 99.0% in the old-age group ( $n = 295$ ), and 97.2% in the advanced-age group ( $n = 72$ ). The long-term survival rate of the prosthesis was significantly reduced in patients < 55-year old ( $\chi^2 = 12.37$ ,  $p = 0.02$ ) (Fig. 2). However, no significant difference was found in the postoperative KSS and OKS scores among different age groups, but the postoperative ROM of the knee was significantly greater in the old-age group than in the advanced-age group ( $F = 3.049$ ,  $p = 0.048$ ).

According to the Iwano imaging classification, the 10-year prosthesis survival rate was 98.9% in the grade 0–1 group, 92.7% in the grade 2 group, 97.8% in the grade 3 group, and 96% in the grade 4 group. Interestingly, the degree of patellofemoral joint degeneration did not affect the survival rate of the UKA ( $\chi^2 = 4.162$ ,  $p = 0.244$ ) (Fig. 3). In terms of clinical efficacy, although no significant difference existed in the postoperative ROM and KSS scores across all groups, the degree of patellofemoral joint degeneration did not exert a significant impact on the postoperative

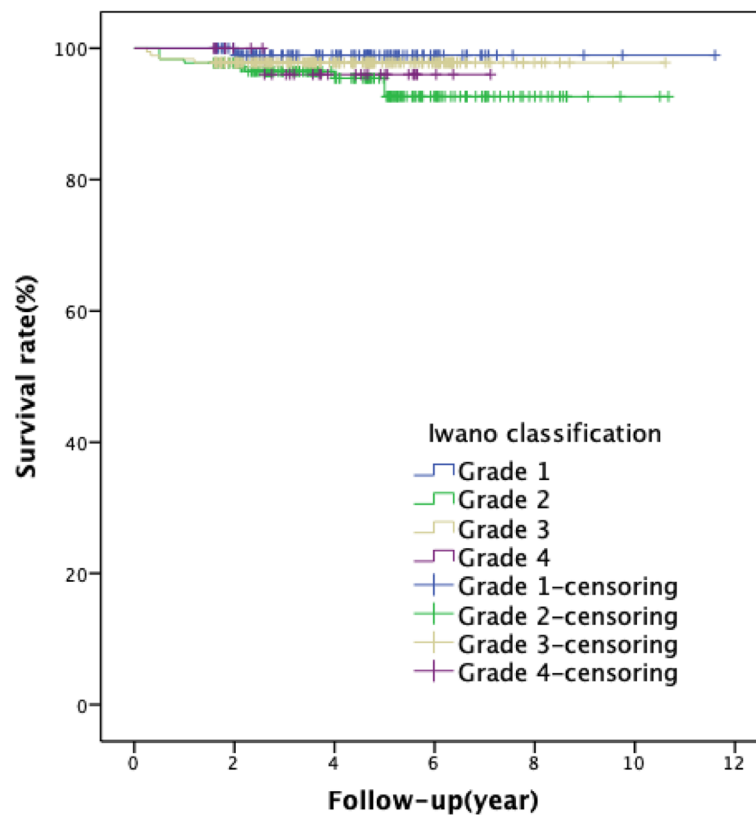
OKS scores ( $F = 10.627$ ,  $p < 0.001$ ), but was significantly reduced in the grade 4 group.

## Discussion

This study reviewed 500 OUKAs for the treatment of medial compartment osteoarthritis of the knee in a single institution. The results showed that OUKA significantly improved knee joint mobility, and could achieve reliable clinical effect. Thus, OUKA is the best choice for the treatment of anteromedial osteoarthritis. Murray et al. first reported that the 10-year survival rate of the phase III Oxford UKA was 98% [7]. In this study, the 10-year survival rate of the prosthesis in 500 patients was 96%, which was consistent to recent studies [18, 32, 33]. The long-term survival rate of OUKA did not differ significantly between the consultant and trainee surgeons. However, the postoperative complications occurred more with the trainee surgeons. The operation needed some learning curve and experience [34]. The surgical technique and clinical experience are the key factors to the improved the clinical effect and reduced complications.



**Fig. 2** Kaplan-Meier survival analysis of different age groups: the 10-year survival rate in the middle-age group was 89.8%, that of the advanced-age group was 99.0%, and that of the older age group was 97.2% ( $\chi^2 = 12.37$ ,  $p = 0.02$ )



**Fig. 3** Kaplan-Meier survival analysis for Iwano classification: the 10-year survival rate of grade 0–1 group was 98.9%, that of grade 2 group was 92.7%, that of grade 3 group was 97.8%, and that of grade 4 group was 96% ( $\chi^2 = 4.162, p = 0.244$ )

The complications of OUKA include: polyethylene bearing dislocation, bearing wear, aseptic loosening, medial collateral ligament or cruciate ligament injury, arthritis progression, deep infection, articular cavity recurrent hematoma, bone cement residual, and unexplained pain. The complications varied with different periods of follow-up [35, 36]. The dislocation of bearing is one of the main postoperative complications. The incidence of dislocation is higher in Asia than in other regions, which could be attributed to the inadequate stability of the bearing in high flexion, which was frequent in Asian patients [36, 37]. In Europe and USA, the progression of lateral compartment osteoarthritis is the most common complication (4.2%) [38]. In our cohort, 4 patients developed aseptic loosening of the femoral prosthesis, including 2 cases of spontaneous osteonecrosis of the knee (SONK), which occurred due to postoperative bone absorption in the necrotic area. The related clinical studies showed that SONK could be addressed by OUKA with satisfactory clinical effect [39, 40] but further multicenter randomized controlled studies are warranted to confirm the findings. Thus, SONK should be applied with caution.

The complications can be treated with revision surgery or non-revision surgery [41, 42]. Non-revision surgery includes debridement, arthroscopic surgery, and ligament reconstruction. The revision surgery includes simple bearing replacement, UKA prosthesis revision, or total knee prosthesis revision, depending on the type of complications. The overall incidence of complications is not high with appropriate selection of patients and skillful surgical procedure.

For advanced-age patients, especially those > 75-year-old, the OUKA has the apparent advantages of small trauma, fast postoperative recovery, reliable clinical efficacy, and high long-term survival rate of the prosthesis, as compared with TKA [43]. Although the postoperative range of motion of the knee in the advanced-age patients was marginally lower than that of the other two groups, the clinical efficacy and long-term survival rate of the prosthesis were essentially identical. Nonetheless, the use of OUKA in younger and physically-active patients remains controversial. According to the records of joint registration systems in some countries [24, 26], patients < 65-year-old often have poor postoperative outcomes and high revision rates. Nevertheless, some single-center studies showed that younger and more



active patients who had undergone UKA surgery attained satisfactory clinical efficacy, and they were able to return to normal activity, could engage in sports, and presented a high long-term survival rate [44, 45]. In this study, the 10-year survival rate of the prosthesis in the middle-age group was only 89.8%, which was lower than that of the other two groups. However, the postoperative clinical efficacy was satisfactory, and the clinical score was significantly improved, but no difference was found as compared to the other groups. Thus, accurate prosthesis placement is essential for stable and adequate postoperative clinical efficacy.

Patellofemoral joint degeneration in the past has been regarded as a contraindication of UKA [27]. However, a number of recent studies demonstrated that it had no influence on the postoperative effect. Therefore, some investigators began to abandon the previous indication. As the asymptomatic patients with patellofemoral joint degeneration are indicated for OUKA, some scholars ignored the patellofemoral joint degeneration [7, 46, 47]. In this study, patellofemoral joint degeneration did not affect the survival rate of OUKA. Iwano classification makes it simple and feasible to assess the degree of patellofemoral joint degeneration. In the patients with grade 4 degeneration, the layer of the cartilage of the lateral patellofemoral joint completely wore off, with bone-on-bone contact. The postoperative effect in such patients is poor. Hence, the patients' condition should be carefully evaluated to achieve optimal results.

## Conclusions

In conclusion, OUKA is one of the treatments for medial compartmental osteoarthritis and has reliable clinical efficacy, high long-term survival rate, and low incidence of related complications. Some issues, such as age-related problems and patellofemoral joint degeneration, can be addressed by careful patient selection and skillful operation.

## Abbreviations

ROM: The range of movement; KSS: The Knee Society score; OKS: The Oxford knee score; UKA: Unicompartamental knee arthroplasty; OA: Osteoarthritis; OUKA: The Oxford Unicompartamental Knee Arthroplasty; KO: Knee osteoarthritis; BMI: The body mass index; SONK: The spontaneous osteonecrosis of the knee

## Acknowledgements

Not applicable.

## Authors' contributions

BW (writing of the manuscript, methodology, data analysis and interpretation), HS (designing of the study, methodology, data analysis and interpretation, supervision), ZF (methodology, analysis and interpretation of the data), JK (data collection and acquisition), XY (methodology, supervision). All authors reviewed the final version of the manuscript. All authors read and approved the final manuscript.

## Funding

Not applicable.

## Availability of data and materials

The datasets used during the current study are available from the corresponding author upon reasonable request.

## Ethics approval and consent to participate

Not applicable.

## Consent for publication

The patients provided consent to the publication of their data in this study.

## Competing interests

The authors declare that they have no competing interests.

Received: 19 February 2020 Accepted: 14 December 2020

Published online: 15 February 2021

## References

- White SH, Ludkowski PF, Goodfellow JW. Anteromedial osteoarthritis of the knee. *J Bone Joint Surg Br*. 1991; 73(4):582–6.
- McKeever DC. The choice of prosthetic materials and evaluation of results. *Clin Orthop*. 1955;6:17–21.
- Barrett WP, Scott RD. Revision of failed unicompartmental knee arthroplasty. *J Bone Joint Surg Am*. 1987;69(9):1328–35.
- Bae DK, Guhl JF, Keane SP. Unicompartamental knee arthroplasty for single compartment disease. Clinical experience with an average four-year follow-up study. *Clin Orthop Relat Res*. 1983; (176):233–8.
- Goodfellow J, O'Connor J. The mechanics of the knee and prosthesis design. *J Bone Joint Surg Br*. 1978;60-B(3):358–69.
- Goodfellow JW, Kershaw CJ, Benson MK, et al. The Oxford Knee for unicompartamental osteoarthritis. The first 103 cases. *J Bone Joint Surg Br*. 1988;70(5):692–701.
- Murray DW, Goodfellow JW, O'Connor JJ. The Oxford medial unicompartamental arthroplasty: a ten-year survival study. *J Bone Joint Surg Br*. 1998;80(6):983.
- Riddle DL, Jiranek WA, McGlynn FJ. Yearly incidence of unicompartamental knee arthroplasty in the United States. *J Arthroplasty*. 2008;23(3):408–12.
- Newman J, Pydisetty RV, Ackroyd C. Unicompartamental or total knee replacement: the 15-year results of a prospective randomized controlled trial. *J Bone Joint Surg Br*. 2009;91-B(1):52–7.
- Berger RA, Della Valle CJ. Unicompartamental knee arthroplasty: indications, techniques, and results. *Instr Course Lect*. 2010;59:47–56.
- Lisowski LA, Meijer LI, Bekerom M, et al. Ten- to 15-year results of the Oxford Phase III mobile unicompartamental knee arthroplasty: a prospective study from a non-designer group. *Bone Joint J*. 2016; 98-B(10 Suppl B):41–7.
- Price AJ, Webb J, Topf H, et al. Rapid recovery after oxford unicompartamental arthroplasty through a short incision. *J Arthroplasty*. 2001;16(8):970–6.
- Panni AS, Vasso M, Cerciello S, et al. Unicompartamental knee replacement provides early clinical and functional improvement stabilizing over time. *Knee Surg Sports Traumatol Arthrosc*. 2012;20(3):579–85.
- Dervin GF, Carruthers C, Feibel RJ, et al. Initial experience with the oxford unicompartamental knee arthroplasty. *J Arthroplasty*. 2011;26(2):192–7.
- Svärd UC, Price AJ. Oxford medial unicompartamental knee arthroplasty. A survival analysis of an independent series. *J Bone Joint Surg Br*. 2001;83(2): 191–4.
- Price AJ, Waite JC, Svärd U. Long-term clinical results of the medial Oxford unicompartamental knee arthroplasty. *Clin Orthop Relat Res*. 2005; (435):171–80.
- Price AJ, Svärd U. A second decade lifetable survival analysis of the Oxford unicompartamental knee arthroplasty[J]. *Clin Orthop Relat Res*. 2011; 469(1): 174–9.
- Pandit H, Jenkins C, Gill HS, et al. Minimally invasive Oxford phase 3 unicompartamental knee replacement: results of 1000 cases[J]. *J Bone Joint Surg Br*. 2011;93(2):198–204.
- Pandit H, Hamilton TW, Jenkins C, et al. The clinical outcome of minimally invasive Phase 3 Oxford unicompartamental knee arthroplasty: a 15-year follow-up of 1000 UKAs[J]. *Bone Joint J*. 2015; 97-B(11):1493–500.
- Epinette JA, Brunschweiler B, Mertl P, et al. French Society for Hip and Knee. Unicompartamental knee arthroplasty modes of failure: wear is not the main reason for failure: a multicentre study of 418 failed knees[J]. *Orthop Traumatol Surg Res*. 2012;98(6 Suppl):124–30.

21. Lombardi AV, Berend KR, Berend ME, et al. Current controversies in partial knee arthroplasty[J]. *Instr Course Lect.* 2012;61:347–81.
22. Lyons MC, MacDonald SJ, Somerville LE, et al. Unicompartamental versus total knee arthroplasty database analysis: is there a winner[J]? *Clin Orthop Relat Res.* 2012;470(1):84–90.
23. Morris MJ, Molli RG, Berend KR, et al. Mortality and perioperative complications after unicompartamental knee arthroplasty. *Knee*, 2013, 20(3): 218–20.
24. Robertsson O, Dunbar MJ, Knutson K, et al. The Swedish Knee Arthroplasty Register. 25 years experience [J]. *Bone Joint Research.* 2014;3(7):217–22.
25. Baker PN, Petheram T, Avery PJ, et al. Revision for unexplained pain following unicompartamental and total knee replacement [J]. *Journal of Bone Joint Surgery.* 2012;94(17):313–8.
26. Pearse AJ, Hooper GJ, Rothwell A, et al. Survival and functional outcome after revision of a unicompartamental to a total knee replacement: the New Zealand National Joint Registry [J]. *Journal of Bone & Joint Surgery-british Volume*, 2010, 92(4): 508–512.
27. Kozinn SC, Scott R. Unicompilar knee arthroplasty [J]. *Journal of Bone Joint Surgery American Volume.* 1989;71(1):145–50.
28. Ahlba'ck S. Osteoarthritis of the knee: a radiographic investigation[J]. *Acta Radiol.* 1968;Suppl 277:7–72.
29. Iwano T, Kurosawa H, Tokuyama H, et al. Roentgenographic and clinical findings of patellofemoral osteoarthritis. With special reference to its relationship to femorotibial osteoarthritis and etiologic factors[J]. *Clin Orthop Relat Res* 1990;(252):190.
30. Ewald FC. The Knee Society total knee arthroplasty roentgenographic evaluation and scoring system[J]. *Clin Orthop Relat Res*, 1989(248):9–12.
31. Dawson J, Fitzpatrick R, Murray D, et al. Questionnaire on the perceptions of patients about total knee replacement[J]. *J Bone Joint Surg Br.* 1998;80(1):63–9.
32. Kim KT, Lee S, Kim JH, et al. The Survivorship and Clinical Results of Minimally Invasive Unicompartamental Knee Arthroplasty at 10-Year Follow-up[J]. *Clin Orthop Surg.* 2015;7(2):199–206.
33. Lisowski LA, Meijer LI, Bekerom M, et al. Ten- to 15-year results of the Oxford Phase III mobile unicompartamental knee arthroplasty: a prospective study from a non-designer group[J]. *Bone Joint J*, 2016, 98-B(10 Supple B): 41–7.
34. Murray DW, Parkinson RW. Usage of unicompartamental knee arthroplasty. *Bone Joint J.* 2018;100-B(4):432–5.
35. Vardi G, Strover AE. Early complications of unicompartamental knee replacement: the Droitwich experience[J]. *Knee.* 2004;11(5):389–94.
36. Kim KT, Lee S, Lee J, et al. Analysis and Treatment of Complications after Unicompartamental Knee Arthroplasty[J]. *Knee Surg Relat Res.* 2016;28(1):46–54.
37. Lim HC, Bae JH, Song SH, et al. Oxford phase 3 unicompartamental knee replacement in Korean patients[J]. *J Bone Joint Surg Br.* 2012, 94(8):1071–6.
38. Emerson RH, Alnachoukati O, Barrington J, et al. The results of Oxford unicompartamental knee arthroplasty in the United States: a mean ten-year survival analysis[J]. *Bone Joint J*, 2016, 98-B(10 Supple B):34–40.
39. Fukuoka S, Fukunaga K, Taniura K, et al. Medium-term clinical results of unicompartamental knee arthroplasty for the treatment for spontaneous osteonecrosis of the knee with four to 15 years of follow-up[J]. *Knee.* 2019; 26(5):1111–6.
40. Guo W, Zhang Q, Liu Z, et al. Minimally invasive unicompartamental knee arthroplasty for spontaneous osteonecrosis of the knee[J]. *Orthop Surg.* 2015;7(2):119–24.
41. Crawford DA, Berend KR, Lombardi AV. Management of the Failed Medial Unicompartamental Knee Arthroplasty[J]. *J Am Acad Orthop Surg.* 2018; 26(20):e426–33.
42. Clark M, Campbell DG, Kiss G, et al. Reintervention after mobile-bearing Oxford unicompartamental knee arthroplasty[J]. *Clin Orthop Relat Res.* 2010, 468(2):576–80.
43. Siman H, Kamath AF, Carrillo N, et al. Unicompartamental Knee Arthroplasty vs Total Knee Arthroplasty for Medial Compartment Arthritis in Patients Older Than 75 Years: Comparable Reoperation, Revision, and Complication Rates[J]. *J Arthroplasty.* 2017 Jun;32(6):1792–7.
44. Wang F, Xue H, Ma T, et al. Short-term effectiveness of medial unicompartamental knee arthroplasty in young patients aged less than or equal to 60 years[J]. *J Orthop Surg (Hong Kong).* 2020;28(3): 2309499020945118.
45. Walker T, Streit J, et al. Sports, Physical Activity and Patient-Reported Outcomes After Medial Unicompartamental Knee Arthroplasty in Young Patients[J]. *J Arthroplasty.* 2015 Nov;30(11):1911–6.
46. Beard DJ, Pandit H, Gill HS, et al. The influence of the presence and severity of pre-existing patellofemoral degenerative changes on the outcome of the Oxford medial unicompartamental knee replacement[J]. *J Bone Joint Surg Br.* 2007;89(12):1597–601.
47. Pandit Hamilton T, Maurer H, D, et al. Anterior knee pain and evidence of osteoarthritis of the patellofemoral joint should not be considered contraindications to mobile-bearing unicompartamental knee arthroplasty. A 15-year follow-up[J]. *Bone Joint J.* 2017;99-B:632–9.

## Publisher's Note

Springer Nature remains neutral with regard to jurisdictional claims in published maps and institutional affiliations.

**Ready to submit your research? Choose BMC and benefit from:**

- fast, convenient online submission
- thorough peer review by experienced researchers in your field
- rapid publication on acceptance
- support for research data, including large and complex data types
- gold Open Access which fosters wider collaboration and increased citations
- maximum visibility for your research: over 100M website views per year

**At BMC, research is always in progress.**

Learn more [biomedcentral.com/submissions](https://biomedcentral.com/submissions)

