

Improving SIEA Perfusion through the Delay Phenomenon

Robert J. Allen Jr, MD*; Rachel A. Anolik, MD*; Yasmina Zoghbi, MD†; Jonas A. Nelson, MD*; Robert J. Allen Sr, MD‡

Despite advances in microsurgery and increasing autologous options for breast reconstruction, the abdomen remains the ideal donor site owing to its similar quality and pliability relative to normal breast tissue. Use of the lower abdomen has evolved in an effort to reduce donor site morbidity—from the transverse rectus abdominis myocutaneous flap to the superficial inferior epigastric artery (SIEA) flap. The SIEA flap avoids violation of the abdominal wall and decreases operative time; however, its use is limited in most patients secondary to the small caliber of the pedicle¹ and variable anatomy.² Additionally, the SIEA flap has been associated with increased rates of flap failure and fat necrosis.²

The delay phenomenon is a well-studied technique to improve perfusion by creating relative ischemia to surrounding tissues.³ There is a paucity of literature regarding vascular delay of SIEA flaps, though this technique is feasible in the appropriate patient.^{4,5} We present a successful, planned delay procedure of the SIEA flap to improve perfusion of donor tissue without ligating the deep inferior epigastric artery and violating the abdominal wall fascia.

The patient in this case is a 52-year-old, nonsmoking woman who presented with infiltrating ductal carcinoma (T1N0M0, ER+/PR+/HER2neu-), for which a unilateral mastectomy was recommended. She was seen to discuss reconstructive options and opted to use autologous abdominal tissue; however, given her active lifestyle, she wanted to avoid the risk of bulging, hernias, laxity, or other functional deficits that can be encountered with deep inferior epigastric perforator (DIEP) or transverse rectus abdominis myocutaneous flaps.

The delay procedure was performed at the time of mastectomy and tissue expander placement. The DIEP system was preserved on the opposite side as a lifeboat. The SIEA was identified using Doppler ultrasound, and its course marked. The superior and midline incisions

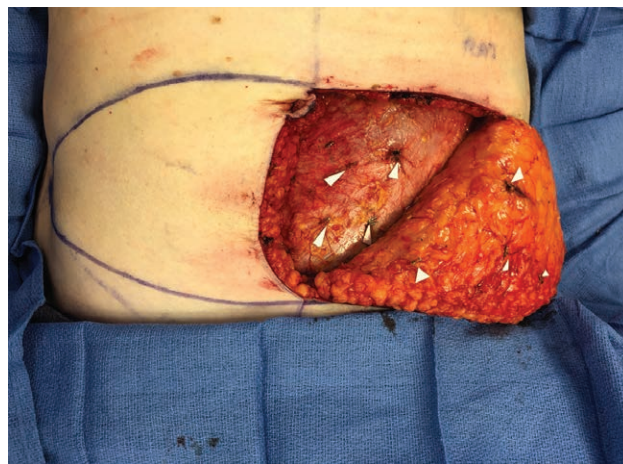


Fig. 1. DIEP perforators ligated in the suprafascial plane at the time of mastectomy.

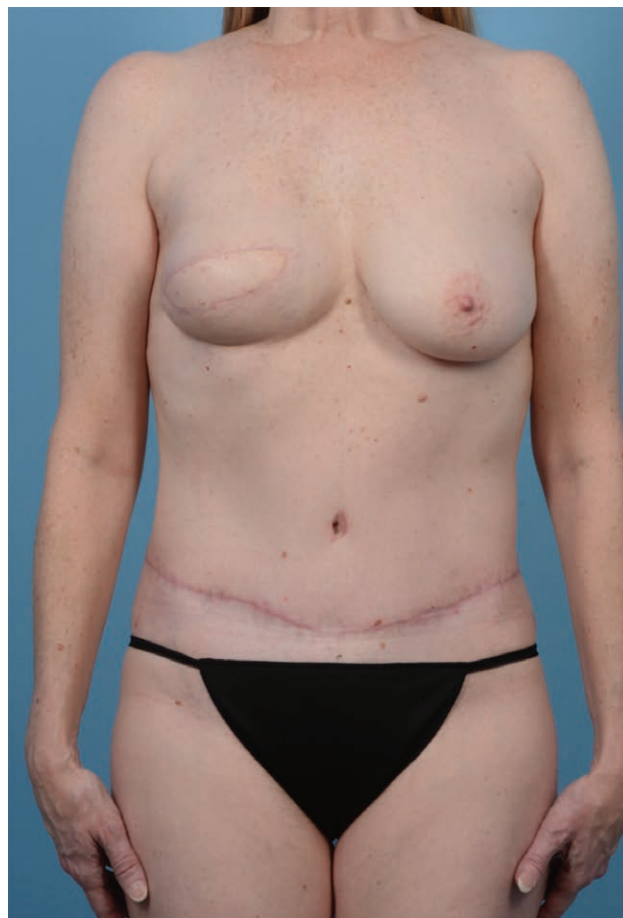

Fig. 2. Postoperative result at 2 months follow-up.

From the *Division of Plastic Surgery, Department of Surgery, Memorial Sloan Kettering Cancer Center, New York, N.Y.; †Division of Plastic Surgery, Department of Surgery, Icahn School of Medicine at Mount Sinai, New York, N.Y.; and ‡Ochsner Medical Center, New Orleans, La.

Received for publication December 14, 2021; accepted March 14, 2022.

Copyright © 2022 The Authors. Published by Wolters Kluwer Health, Inc. on behalf of The American Society of Plastic Surgeons. This is an open-access article distributed under the terms of the [Creative Commons Attribution-Non Commercial-No Derivatives License 4.0 \(CCBY-NC-ND\)](https://creativecommons.org/licenses/by-nc-nd/4.0/), where it is permissible to download and share the work provided it is properly cited. The work cannot be changed in any way or used commercially without permission from the journal.

Plast Reconstr Surg Glob Open 2022;10:e4297; doi: 10.1097/GOX.0000000000004297; Published online 11 May 2022.

of the flap were made and carried down to the anterior rectus fascia; dissection was then carried in a suprafascial plane to identify the DIEP perforators which were ligated (Fig. 1), and the flap was then re-inset.

Six months later, she underwent right breast reconstruction with the delayed left SIEA flap, including two zones, weighing 550 g. SPY angiography (NOVADAQ Technologies, Inc, Mississauga, Ontario, Canada) showed robust perfusion of both zones. She was seen for follow-up at 2 months, with an excellent result and no evidence of fat necrosis, healing issues, or abdominal wall complaints (Fig. 2).

In select patients, the planned delay at the time of mastectomy is a feasible technique that can facilitate harvest and improve perfusion of the flap by augmenting the flow through and increasing the caliber of the SIEA. This in turn decreases the risk of fat necrosis and flap failure. This technique can broaden the indications for the SIEA flap and allow an increased number of patients to undergo a procedure that achieves aesthetically pleasing results, with no abdominal wall morbidity. This can ultimately lead to decreased length of stay and earlier return to activities. Further studies are warranted to better define the appropriate patient population and confirm the reliability of this technique.

Robert J. Allen, Jr, MD

Division of Plastic Surgery
Memorial Sloan Kettering Cancer Center

DISCLOSURE

The authors have no financial interest to declare in relation to the content of this article. This study was funded in part through the NIH/NCI Cancer Center Support Grant P30 CA008748.

REFERENCES

1. Fukaya E, Kuwatsuru R, Iimura H, et al. Imaging of the superficial inferior epigastric vascular anatomy and preoperative planning for the SIEA flap using MDCTA. *J Plast Reconstr Aesthet Surg.* 2011;64:63–68.
2. Spiegel AJ, Khan FN. An Intraoperative algorithm for use of the SIEA flap for breast reconstruction. *Plast Reconstr Surg.* 2007;120:1450–1459.
3. Christiano JG, Rosson GD. Clinical experience with the delay phenomenon in autologous breast reconstruction with the deep inferior epigastric artery perforator flap. *Microsurgery.* 2010;30:526–531.
4. Hadad I, Ibrahim AM, Lin SJ, et al. Augmented SIEA flap for microvascular breast reconstruction after prior ligation of bilateral deep inferior epigastric arteries. *J Plast Reconstr Aesthet Surg.* 2013;66:845–847.
5. Gregoric M, Flis V, Miličić F, et al. Delaying the superficial inferior epigastric artery flap: a solution to the problem of the small caliber of the donor artery. *J Plast Reconstr Aesthet Surg.* 2011;64:1181–1186.