

Diagnosing *Rhodococcus equi* Infections in a Setting Where Tuberculosis Is Highly Endemic: a Double Challenge

Thuy Le,^{a,b,f} Shama Cash-Goldwasser,^c Phan Vinh Tho,^d Nguyen Phu Huong Lan,^d James I. Campbell,^{a,b} H. Rogier van Doorn,^{a,b} Nguyen Tien Lam,^e Nguyen Vu Trung,^e Dao Tuyet Trinh,^e Nguyen Van Kinh,^e Heiman F. L. Wertheim^{a,b}

Oxford University Clinical Research Unit, Wellcome Trust Major Overseas Program, Ho Chi Minh City, Vietnam^a; Centre for Tropical Medicine, Nuffield Department of Clinical Medicine, University of Oxford, Oxford, United Kingdom^b; McGill University Faculty of Medicine, Montreal, Quebec, Canada^c; Hospital for Tropical Diseases, Ho Chi Minh City, Vietnam^d; National Hospital for Tropical Diseases, Hanoi, Vietnam^e; Hawaii Center for AIDS, University of Hawaii at Manoa, Honolulu, Hawaii, USA^f

***Rhodococcus equi* infection is increasing in regions with high HIV prevalence worldwide. The microbiological features and clinical mimicry of tuberculosis infection pose diagnostic challenges in high-tuberculosis-incidence settings. We present two HIV-associated cases of *R. equi* infection from Vietnam and discuss the unique diagnostic challenges in such settings.**

CASE REPORTS

Case 1. A 27-year-old male was referred to the National Hospital for Tropical Diseases in Hanoi, Vietnam, in 2011 with 2 months of fever, productive cough, and trouble breathing. He was diagnosed with HIV in 2006 but had not started antiretroviral therapy (ART). He worked as a nurse and had not had contact with a farming environment or animals. The physical examination revealed a temperature of 39°C, labored breathing, and lung crackles. Laboratory testing showed normal electrolytes, transaminases, and creatinine but low hemoglobin (9.4 g/dl) (reference range, 14.5 to 15.7 g/dl) and elevated lactate dehydrogenase (452 IU/liter) (reference range, 140 to 280 IU/liter). The CD4 count was 36 cells/ μ l (reference range, 500 to 1,200 cells/ μ l). Sputum stains revealed Gram-positive bacilli and were negative for acid-fast bacilli (AFB) and fungi. A chest X-ray showed a left upper lobe consolidation with cavitory lesions (Fig. 1a) and a small pleural effusion. A thoracentesis was performed, and the pleural fluid showed inflammatory exudates and Gram-positive coccobacilli but no AFB or fungi. Blood culture on the day of admission showed no growth. The patient did not improve after 1 week of intravenous piperacillin-tazobactam at 3.375 g every 6 h and oral metronidazole at 500 mg three times daily. On hospitalization day 10, the smooth mucoid salmon-pink appearance of the pleural fluid culture raised suspicion for *Rhodococcus equi* (Fig. 1b). The organism was identified by using API identification strips (bioMérieux, Marcy l'Etoile, France) and was confirmed by 16S rRNA sequencing. Subsequent blood culture (hospitalization day 21) also grew *R. equi*. Susceptibility testing was performed by disk diffusion method using Oxoid (Oxoid, Cheshire, United Kingdom) pills on sheep blood agar (Merck) using CLSI cutoffs for *Staphylococcus aureus*. The isolate was susceptible to vancomycin, ampicillin-clavulanate, rifampin, cefoxitin, cotrimoxazole, erythromycin, gentamicin, levofloxacin, and ciprofloxacin and was resistant to oxacillin, clindamycin, penicillin, and ampicillin. The patient was started on oral rifampin at 450 mg daily, levofloxacin at 750 mg daily, and erythromycin at 500 mg twice daily based on susceptibility testing. His fever and respiratory symptoms gradually improved over 4 weeks of inpatient treatment. He was started on ART and was discharged home after 6 weeks of hospitalization; the patient was subsequently lost to follow-up.

Case 2. A 28-year-old male was admitted to the Hospital for

Tropical Diseases in Ho Chi Minh City, Vietnam, in 2012 with 2 months of fever, weight loss, and nonproductive cough. The patient had been working for 5 years in a greenhouse with frequent manure exposure. The physical examination showed a temperature of 38°C, oral thrush, and enlarged cervical lymph nodes of 2 to 3 cm. Laboratory testing showed electrolytes, transaminases, and creatinine levels within reference ranges but low hemoglobin (7.3 g/dl). The results of three different enzyme-linked immunosorbent assays (ELISAs) for HIV were positive, and the CD4 count was 61 cells/ μ l. Multiple sputum stains for bacteria and AFB were negative. A chest X-ray showed interstitial changes with a small right pleural effusion. The patient was treated with intravenous ceftriaxone at 2 g daily and oral cotrimoxazole at 160 mg (trimethoprim)/800 mg (sulfamethoxazole) four times daily for presumed bacteria and *Pneumocystis jirovecii* pneumonia for 1 week without clinical improvement. Blood culture on the day of admission showed no growth. A chest computed tomography showed mediastinal lymphadenopathy, numerous parenchymal nodules, and a right pleural effusion (Fig. 2). A thoracentesis was performed, and the pleural fluid showed inflammatory exudates but was negative for Gram and Ziehl-Neelsen stains. Tuberculosis was the leading diagnosis, and the patient was empirically started on antituberculosis therapy with isoniazid at 300 mg daily, rifampin at 450 mg daily, pyrazinamide at 1 g daily, and ethambutol at 800 mg daily. Pleural fluid culture on hospitalization day 7 grew mucoid colonies of weakly acid-fast coccobacilli. The colonies were identified as *R. equi* by using API identification strips. Despite the identification of *R. equi*, the treating clinicians refused to

Received 14 August 2014 Returned for modification 15 September 2014

Accepted 20 January 2015

Accepted manuscript posted online 28 January 2015

Citation Le T, Cash-Goldwasser S, Tho PV, Lan NPH, Campbell JI, van Doorn HR, Lam NT, Trung NV, Trinh DT, Kinh NV, Wertheim HFL. 2015. Diagnosing *Rhodococcus equi* infections in a setting where tuberculosis is highly endemic: a double challenge. J Clin Microbiol 53:1431–1433. doi:10.1128/JCM.02284-14.

Editor: Y.-W. Tang

Address correspondence to Thuy Le, thuy@oucr.uo.ox.ac.uk.

Copyright © 2015, Le et al. This is an open-access article distributed under the terms of the Creative Commons Attribution 3.0 Unported license.

doi:10.1128/JCM.02284-14

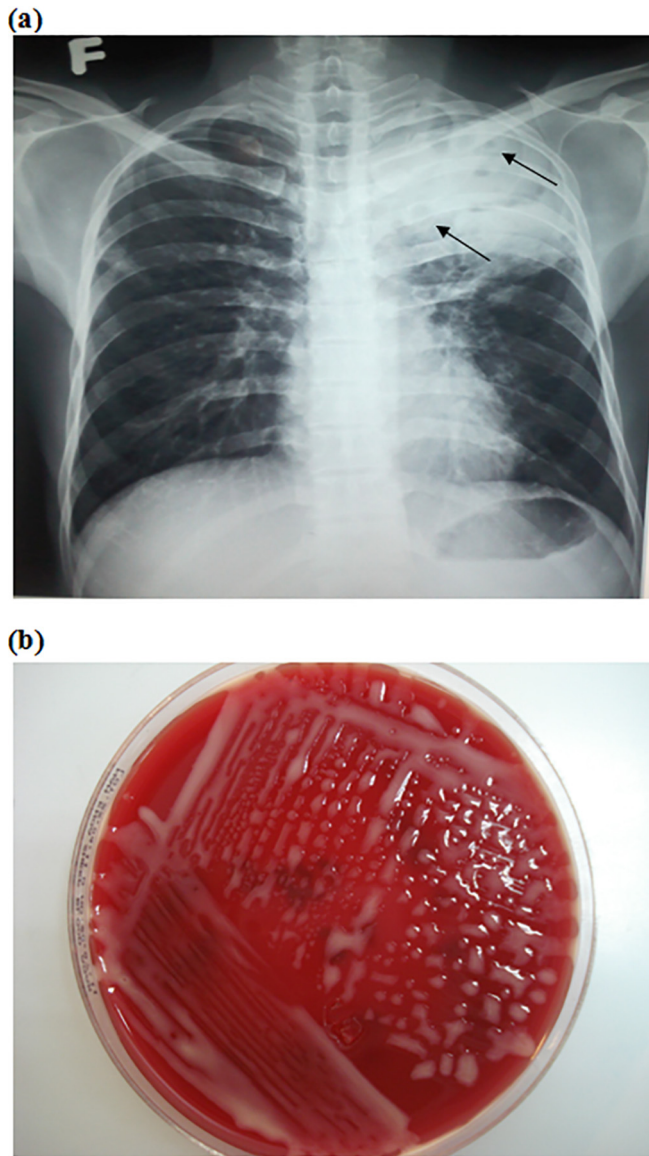


FIG 1 (a) Chest X-ray of patient 1 with arrows indicating several cavitary lesions within the left upper lobe consolidation; (b) salmon-pink colonies after 7-day incubation of the pleural fluid, plated on Columbia blood agar.

stop antituberculosis therapy. Upon discussions with infectious disease specialists, levofloxacin at 750 mg daily was added to provide dual coverage for tuberculosis and *R. equi*. Fever and cough resolved after 1 week. The patient completed a 6-month course of therapy and remained well at month 18 of follow-up. His CD4 count rose to 465 cells/ μ l on ART.

R. equi is increasingly recognized as a human pathogen, with approximately 200 cases described in the literature (1). Eighty-five percent of *R. equi* infections in humans occur in immunocompromised patients, with patients with HIV accounting for two-thirds of cases (2). Approximately 50% of patients have some contact with herbivores or their manure (3, 4). Mortality is 50% in HIV-infected patients and is more than twice the mortality in HIV-

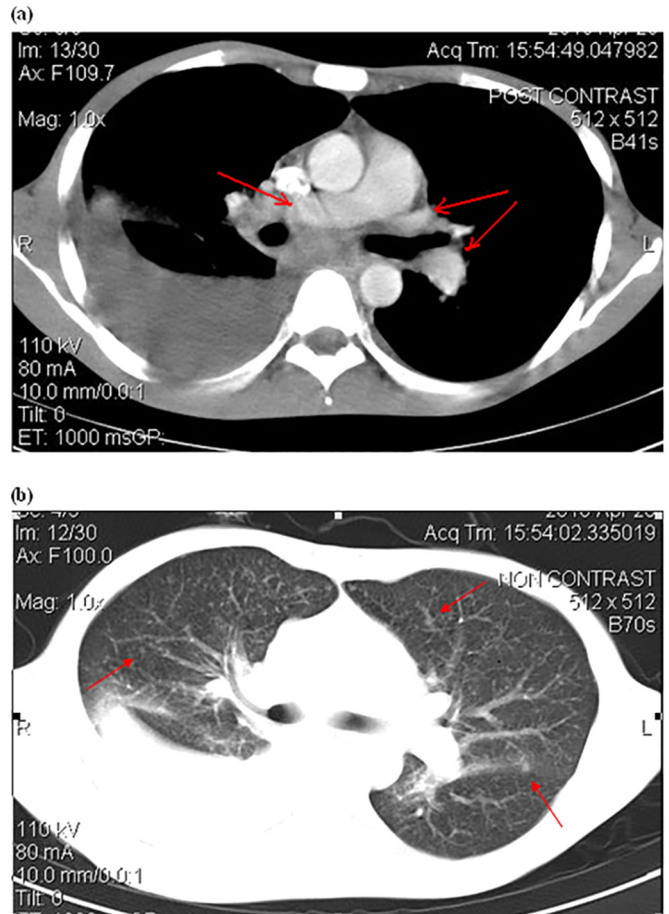


FIG 2 Chest computed tomography of patient 2 showing a large pleural effusion in the right lung. (a) Arrows indicate enlarged mediastinal lymph nodes; (b) arrows indicate parenchymal nodules.

uninfected patients (3, 5). Most patients present with subacute onset of pulmonary disease, chest radiographic abnormality, and constitutional symptoms (1, 3). The majority of HIV-infected patients have concurrent bacteremia and may develop disease at multiple distant sites (1, 5). Chest radiographs are abnormal in 95% of patients, and the most common radiographic findings are cavitary lung lesions (75%) and pleural effusion (20%) (4, 11). Diagnosis can be made via culture of biopsy specimens and all bodily fluids (1).

On the basis of morphology, several microbiological features of *R. equi* allow it to escape identification in a microbiology laboratory. First, *R. equi* grows readily on nonselective medium; however its variable rod-to-coccus appearance can be mislabeled as “mixed flora” on Gram-stained sputum. Early colonies have a pleomorphic diphtheroid appearance, which can easily be dismissed as a contaminant. Further, the organism can be acid fast on a Ziehl-Neelsen smear and be mistaken for a mycobacterium (1, 3, 5). *R. equi* was found to have the highest sequence homology with *Mycobacterium tuberculosis* in a comparison with other bacterial genera or species based on partial genome sequencing (6). The close genetic distance may explain similarities in disease pathogenesis, in particular the ability of *R. equi* to persist and multiply inside macrophages (7) and to cause pyogranulomatous pneumo-

nia in humans. On clinical grounds, human *R. equi* infection is indistinguishable from tuberculosis and hence may be misdiagnosed in settings of high tuberculosis prevalence. Vietnam is among those countries with the highest tuberculosis burden in the world (8), with tuberculosis being the most common HIV-associated diagnosis (9). Our patients presented with clinical features characteristic of tuberculosis, and one patient was started on antituberculosis treatment based on clinical suspicion. First-line tuberculosis therapy exposes *R. equi*-infected patients to rifampin monotherapy, which promotes development of resistance and treatment failure (10). *R. equi* is inherently resistant to multiple antibiotics (3, 12, 13), and long-term therapy with two to three drugs is recommended particularly for immunocompromised patients (1). The duration of therapy depends upon the extent of infection, clinical and radiographical resolution, and immune status (1). Most experts recommend at least 6 months of therapy for immunocompromised patients (1). Adding a fluoroquinolone to the standard four-drug antituberculosis regimen provided antimicrobial coverage for both *R. equi* and *M. tuberculosis*, which was more acceptable to the clinicians caring for the patient, and in this case resulted in good therapeutic outcome. In both patients, immune reconstitution on ART was likely important to disease resolution.

Our case report highlights the challenge in diagnosing *R. equi* infections in resource-limited settings with high tuberculosis and HIV prevalence. Increased awareness of the disease and its diagnostic challenges may prevent misdiagnoses and may improve the management of *R. equi* infections in these settings.

ACKNOWLEDGMENTS

We thank the patients for giving permission to discuss their cases and the hospitals and laboratory staff for making the diagnosis and taking care of the patients.

Sources of funding included the Wellcome Trust Major Overseas Program Vietnam (T.L., H.R.V.D., J.I.C., H.F.L.W.), the VIZIONS program (J.I.C., H.F.L.W.), the South East Asia Infectious Disease Clinical Research Network (SEAICRN) (H.F.L.W.), and the Hawaii Center for AIDS (T.L.). The sponsors had no role in the design of this work or the decision to submit for publication.

We declare that we have no competing interests.

Authors' contributions included the following: drafting the paper,

T.L., S.C.-G., H.F.L.W.; data collection/interpretation, T.L., S.C.-G., H.F.L.W.; patient diagnosis and follow up, T.L., P.V.T., N.P.H.L., J.I.C., H.R.V.D., N.T.L., N.V.T., D.T.T., N.V.K., H.F.L.W. All authors reviewed and approved the final version of the paper.

REFERENCES

- Weinstock DM, Brown AE. 2002. *Rhodococcus equi*: an emerging pathogen. *Clin Infect Dis* 34:1379–1385. <http://dx.doi.org/10.1086/340259>.
- Harvey RL, Sunstrum JC. 1991. *Rhodococcus equi* infection in patients with and without human immunodeficiency virus infection. *Rev Infect Dis* 13:139–145. <http://dx.doi.org/10.1093/clinids/13.1.139>.
- Verville TD, Huycke MM, Greenfield RA, Fine DP, Kuhls TL, Slater LN. 1994. *Rhodococcus equi* infections of humans. 12 cases and a review of the literature. *Medicine (Baltimore, MD)* 73:119–132.
- Arlotti M, Zoboli G, Moscatelli GL, Magnani G, Maserati R, Borghi V, Andreoni M, Libanore M, Bonazzi L, Piscina A, Ciannarughi R. 1996. *Rhodococcus equi* infection in HIV-positive subjects: a retrospective analysis of 24 cases. *Scand J Infect Dis* 28:463–467.
- Donisi A, Suardi MG, Casari S, Longo M, Cadeo GP, Carosi G. 1996. *Rhodococcus equi* infection in HIV-infected patients. *AIDS* 10:359–362. <http://dx.doi.org/10.1097/00002030-199604000-00002>.
- Rahman MT, Herron LL, Kapur V, Meijer WG, Byrne BA, Ren J, Nicholson VM, Prescott JF. 2003. Partial genome sequencing of *Rhodococcus equi* ATCC 33701. *Vet Microbiol* 94:143–158. [http://dx.doi.org/10.1016/S0378-1135\(03\)00100-7](http://dx.doi.org/10.1016/S0378-1135(03)00100-7).
- Hondalus MK, Mosser DM. 1994. Survival and replication of *Rhodococcus equi* in macrophages. *Infect Immun* 62:4167–4175.
- Dye C, Maher D, Weil D, Espinal M, Ravignone M. 2006. Targets for global tuberculosis control. *Int J Tuberc Lung Dis* 10:460–462.
- Louie JK, Chi NH, Thao le TT, Quang VM, Campbell J, Chau NV, Rutherford GW, Farrar JJ, Parry CM. 2004. Opportunistic infections in hospitalized HIV-infected adults in Ho Chi Minh City, Vietnam: a cross-sectional study. *Int J STD AIDS* 15:758–761. <http://dx.doi.org/10.1258/0956462042395159>.
- Nordmann P, Chavanet P, Caillon J, Duez JM, Portier H. 1992. Recurrent pneumonia due to rifampicin-resistant *Rhodococcus equi* in a patient infected with HIV. *J Infect* 24:104–107. [http://dx.doi.org/10.1016/0163-4453\(92\)91234-3](http://dx.doi.org/10.1016/0163-4453(92)91234-3).
- Muntaner L, Leyes M, Payeras A, Herrera M, Gutierrez A. 1997. Radiologic features of *Rhodococcus equi* pneumonia in AIDS. *Eur J Radiol* 24:66–70. [http://dx.doi.org/10.1016/S0720-048X\(96\)01022-4](http://dx.doi.org/10.1016/S0720-048X(96)01022-4).
- Prescott JF. 1981. The susceptibility of isolates of *Corynebacterium equi* to antimicrobial drugs. *J Vet Pharmacol Ther* 4:27–31. <http://dx.doi.org/10.1111/j.1365-2885.1981.tb00706.x>.
- Hsueh PR, Hung CC, Teng LJ, Yu MC, Chen YC, Wang HK, Luh KT. 1998. Report of invasive *Rhodococcus equi* infections in Taiwan, with an emphasis on the emergence of multidrug-resistant strains. *Clin Infect Dis* 27:370–375. <http://dx.doi.org/10.1086/514667>.