



## ORIGINAL ARTICLE

# Variability in phenotype induced by the podocin variant R229Q plus a single pathogenic mutation

Paul J. Phelan<sup>1,2,3</sup>, Gentzon Hall<sup>1,2</sup>, Delbert Wigfall<sup>3</sup>, John Foreman<sup>3</sup>, Shashi Nagaraj<sup>3</sup>, Andrew F. Malone<sup>1,2</sup>, Michelle P. Winn<sup>1,2,†</sup>, David N. Howell<sup>4</sup>, and Rasheed Gbadegesin<sup>1,5</sup>

<sup>1</sup>Duke Molecular Physiology Institute, Duke University, Durham, NC, USA, <sup>2</sup>Division of Nephrology, Department of Medicine, Duke University Medical Center, Durham, NC, USA, <sup>3</sup>Department of Nephrology, Royal Infirmary of Edinburgh, NHS Lothian, Edinburgh, UK, <sup>4</sup>Department of Pathology, Duke University Medical Center, Durham, NC, USA, and <sup>5</sup>Department of Pediatrics, Duke University Medical Center, Durham, NC, USA

Correspondence to: Paul J Phelan; E-mail: paulphel@gmail.com

## Abstract

**Background:** Mutations in podocin (*NPHS2*) are the most common cause of childhood onset autosomal recessive steroid-resistant nephrotic syndrome (SRNS). The disease is characterized by early-onset proteinuria, resistance to immunosuppressive therapy and rapid progression to end-stage renal disease. Compound heterozygous changes involving the podocin variant R229Q combined with another pathogenic mutation have been associated with a mild phenotype with disease onset often in adulthood.

**Methods:** We screened 19 families with early-onset SRNS for mutations in *NPHS2* and *WT1* and identified four disease-causing mutations (three in *NPHS2* and one in *WT1*) prior to planned whole-exome sequencing.

**Results:** We describe two families with three individuals presenting in childhood who are compound heterozygous for R229Q and one other pathogenic *NPHS2* mutation, either L327F or A297V. One child presented at age 4 years (A297V plus R229Q) and the other two at age 13 (L327F plus R229Q), one with steadily deteriorating renal function.

**Conclusions:** These cases highlight the phenotypic variability associated with the *NPHS2* R229Q variant plus pathogenic mutation. Individuals may present with early aggressive disease.

**Key words:** familial, FSGS, hereditary, nephrotic syndrome, *NPHS2*, proteinuria

## Introduction

Idiopathic nephrotic syndrome in early life is usually steroid sensitive and carries an excellent prognosis. A minority of cases demonstrate steroid resistance, often with a focal segmental

glomerulosclerosis (FSGS) pattern of injury, and evidence of heritability [1]. In many individuals with inherited nephrotic syndrome, the mutation is in the *NPHS2* gene which codes for podocin. Podocin is a protein located solely in the podocyte

<sup>†</sup> Deceased.

Received: March 26, 2015. Accepted: June 29, 2015

© The Author 2015. Published by Oxford University Press on behalf of ERA-EDTA.

This is an Open Access article distributed under the terms of the Creative Commons Attribution Non-Commercial License (<http://creativecommons.org/licenses/by-nc/4.0/>), which permits non-commercial re-use, distribution, and reproduction in any medium, provided the original work is properly cited. For commercial re-use, please contact [journals.permissions@oup.com](mailto:journals.permissions@oup.com)

slit diaphragm [2], which plays an important role in maintaining the filtration barrier. Familial steroid-resistant nephrotic syndrome (SRNS) caused by autosomal recessive *NPHS2* mutations is characterized by early-onset proteinuria in childhood and resistance to immunosuppressive therapy [3]. Depending on when in the course of the disease a biopsy is performed, the histological lesion present may be minimal change disease (MCD) or FSGS. A number of *NPHS2* mutations have been described in both children and adults with familial and sporadic nephrotic syndrome and FSGS [4, 5].

The R229Q polymorphism (c.686G>A; rs61747728) is a podocin variant resulting in an amino acid substitution from arginine to glutamine. It has also been associated with glomerular disease and is considered a non-neutral polymorphism [6]. The R229Q variant is relatively common, being present in ~1–2% of European populations, and is associated with the development of microalbuminuria in the general population [7]. Cases of adult-onset FSGS have been described due to compound heterozygosity of the R229Q variant with a pathogenic podocin mutation [8]. Clinical assessment of patients carrying R229Q has demonstrated that individuals who are compound heterozygotes for the variant plus a pathogenic *NPHS2* mutation have a less severe phenotype with later disease onset, compared with individuals with two pathogenic mutations [9, 10]. Based on this, the current recommendation is that older children and adults should be screened for this variant of *NPHS2* [1, 10].

As part of our ongoing genetic study of childhood-onset nephrotic syndrome, we screened 19 families with early-onset SRNS for mutations in *NPHS2* and *WT1* as a prelude to whole exome sequencing. We identified three patients with disease-causing mutations in *NPHS2* and one in *WT1*. Two of the three mutations in *NPHS2* were R229Q plus a known pathogenic mutation. The three children from the two families with R229Q plus pathogenic mutations presented with SRNS and pathologic findings of MCD and FSGS between the ages of 4–14 years. Our findings illustrate the phenotypic variability associated with the *NPHS2* R229Q variant plus a pathogenic mutation, highlighting the potential for early presentation.

## Materials and methods

### Clinical data

We selected all individuals with early disease onset (<21 years) and a diagnosis of FSGS and/or SRNS referred to us for inclusion in our genetics of kidney disease research program. Approval for

the study was granted by the Institutional Review Board (IRB) of Duke University, Durham, NC and the local IRB from the referring institutions. The clinical records of all the subjects were reviewed for age at onset, gender, family history, treatment modalities and response to therapy.

### Mutation analysis

Genomic DNA was extracted from whole blood samples or saliva using standard methods. Mutation analysis was performed by direct sequencing of all eight exons of *NPHS2*, and the mutation bearing exons 8 and 9 of *WT1* using exon-flanking primers. All mutations were confirmed with sequencing of the complementary strands. All sequences were analyzed using the Sequencher software package (Gene Codes Corp, Ann Arbor, MI).

## Results

A total of 19 families with 31 children (14 males, 17 females) met the eligibility criteria for this study with all children presenting before 21 years of age with nephrotic-range proteinuria. Biopsy data were available in 23 children and showed an FSGS pattern of injury in 21/23 (91.3%). The other two children were reported to have MCD and diffuse mesangial sclerosis.

### Mutation analysis for *NPHS2* and *WT1*

We found pathogenic mutations in 4/19 (21.1%) of the families studied, comprising an autosomal dominant *WT1* mutation (c.1432+5G>A) in one family and *NPHS2* mutations in three families. One of the mutations in *NPHS2* is a homozygous frameshift mutation while the other two are compound heterozygous R229Q plus known pathogenic mutations. The phenotype of the four families with disease-causing mutations is shown in Table 1. The pedigrees in the two families with R229Q plus known pathogenic mutations are shown in Figure 1, while a detailed phenotypic description of these two families follows.

### Case 1 (Duke Family 34443)

A boy and his sister both presented at the age of 13 years with proteinuria. The boy was first noted to be hypertensive and edematous after a dental procedure. He had overt nephrotic syndrome and a serum creatinine of 0.9 mg/dL at presentation. Renal biopsy demonstrated an FSGS pattern of injury with mild-to-moderate interstitial fibrosis and tubular atrophy.

**Table 1.** Clinical phenotype of four families with SRNS and mutations in *NPHS2* and *WT1*

Family	Race/Country	Gene	Mutation	Age onset (years)	Histology	Age at ESKD
6647	Caucasian/USA	<i>NPHS2</i>	c.890C>T (A297V); c.386G>A (R229Q); compound heterozygous	4.0	MCD	NA
34443 <sup>a</sup>	Caucasian/USA	<i>NPHS2</i>	c.979C>T (L327F); c.386G>A (R229Q); compound heterozygous	13.0	FSGS	NA
6517	Caucasian/USA	<i>NPHS2</i>	c.467–468insA (L156fsX166); homozygous	4.0	FSGS	6
6659	Caucasian/USA	<i>WT1</i>	c.1432+5G>A (IVS9+5G>A); autosomal dominant	1.5	FSGS	NA

ESKD, end stage kidney disease; FSGS, focal segmental glomerulosclerosis; MCD, minimal change disease; NA, not applicable.

<sup>a</sup>Both siblings in this family had an identical mutation profile and age of onset. The affected families 6647 and 34443 were compound heterozygotes for R229Q plus the stated pathogenic mutation.

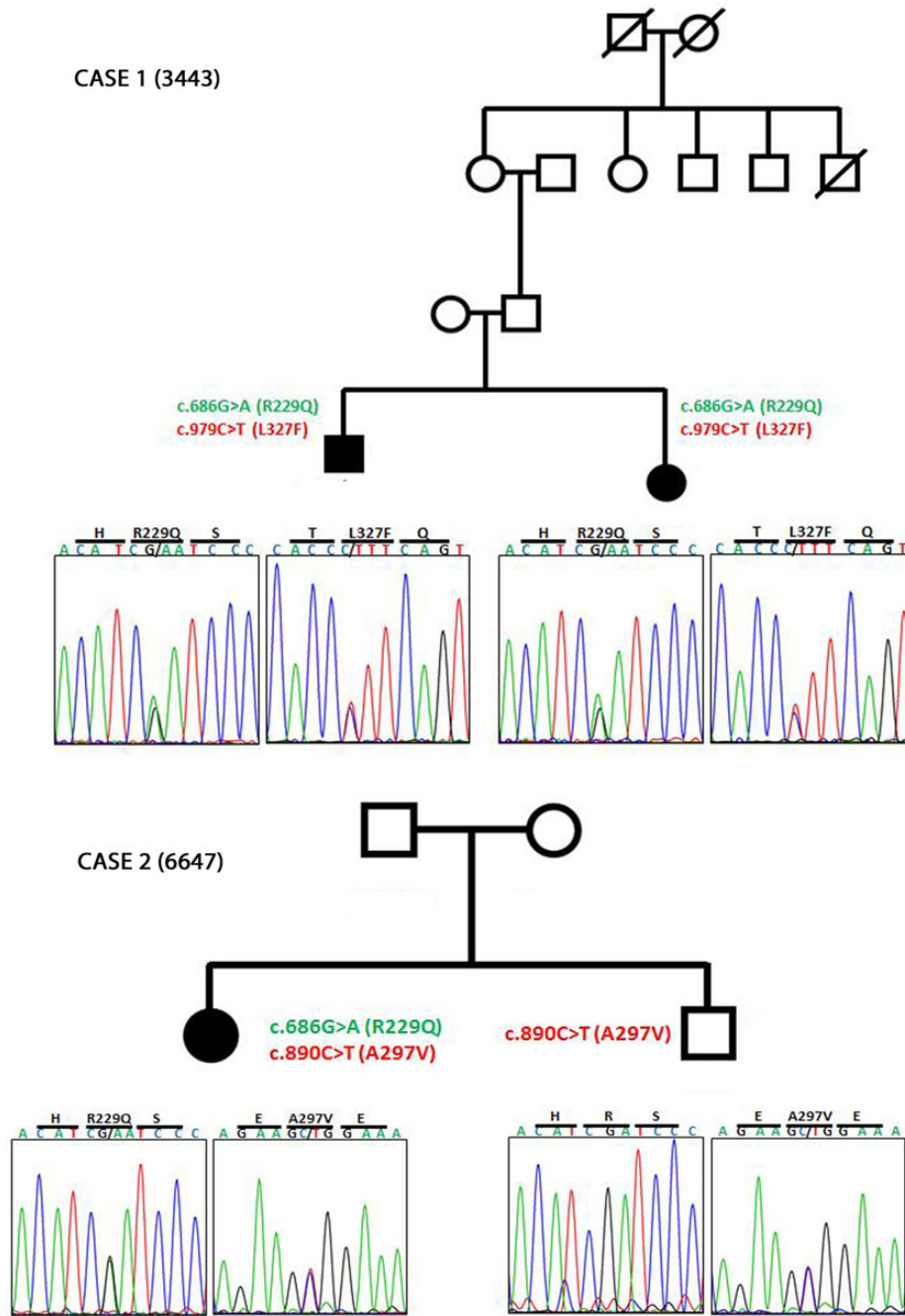


Fig. 1. Family pedigrees with mutation chromatograms for the described families bearing variant R229Q plus pathogenic mutations in *NPHS2*. Squares represent males; circles represent females; solid shapes are affected individuals; crossed out shapes represent deceased family members.

He was unresponsive to corticosteroids, tacrolimus and rituximab therapy. One year later, he had developed significant chronic kidney disease (CKD) with an estimated glomerular filtration rate of 30 mL/min/1.73 m<sup>2</sup>. Following the diagnosis of her brother's renal disease, the sister was found on routine testing to have asymptomatic nephrotic-range proteinuria with a serum creatinine of 0.2 mg/dL. Renal biopsy also demonstrated FSGS with mild-to-moderate chronic interstitial changes. Mutation analysis in both siblings revealed compound heterozygous changes for the pathogenic *NPHS2* mutation L327F and the R229Q variant. Their parents were not available for genetic testing.

#### Case 2 (Duke Family 6647)

A 4-year-old girl presented with urinary frequency and urinalysis showed 2+ proteinuria. Further testing confirmed nephrotic-range proteinuria, low serum albumin and normal renal function. She was empirically treated with corticosteroids and angiotensin-converting-enzyme inhibitors but was unresponsive to therapy. She proceeded to kidney biopsy, which revealed normal light microscopic findings and diffuse podocyte foot process effacement on electron microscopy, consistent with MCD. Mutation analysis of the proband revealed a heterozygous

pathogenic *NPHS2* mutation A297V and the R229Q variant. Her unaffected brother was heterozygous for the A297V mutation as was her father. Her mother was heterozygous for the R229Q variant. Neither parent nor her brother manifested disease clinically. At the last follow-up 5 years after presentation, she had normal renal function and overt proteinuria with a urine protein/creatinine ratio of 2230 mg/g.

## Discussion

Mutations in *NPHS2* are a common cause of SRNS and usually present very early in life [1, 3]. Our understanding of the R229Q polymorphism in *NPHS2* continues to develop. Compound heterozygosity of R229Q, *in trans*, with a pathogenic *NPHS2* mutation is well described causing SRNS [5, 7, 10–12]. However, it is generally associated with a milder phenotype and a disease onset in late childhood or adulthood [6, 13–15]. Our cases confirm that this variant may be associated with disease onset in early childhood, with one individual diagnosed at age 4 years. Furthermore, the boy from Case 2 has severe disease with progressive CKD at age 14. This is consistent with a recent study by Sadowski *et al.* who investigated 1783 families with SRNS in which they identified 208 individuals with *NPHS2* mutations including 11 families (32 individuals) who were compound heterozygous for R229Q plus a pathogenic mutation [16]. Three of the 11 families had an early presentation, defined as <4 years of age. Where a biopsy was performed, the histology of 148 patients with *NPHS2* mutations revealed an FSGS lesion in ~75% of cases and in 68% of cases in the R229Q plus 1 pathogenic mutation cohort. This series contained three individuals with identical genotypes to our patients. There were two cases of R229Q plus L327F (similar to our siblings in Case 1) who presented aged 4 and 6 years and had biopsies at 16 and 19 years of age, respectively, which both showed MCD. There was one case of R229Q plus A297V podocin mutation (similar to Case 2) who presented at 4 years and had a biopsy at 6 years of age demonstrating FSGS. These findings of similar ages of onset with similar mutations are consistent with a genotype–phenotype correlation within combinations of variant R229Q plus pathogenic podocin mutations.

The influence of the R229Q variant on the development of nephrotic syndrome is complex. Genotype–phenotype correlations have demonstrated that R229Q heterozygotes generally do not manifest disease, as demonstrated in family 6647. Homozygosity for R229Q is relatively common, estimated to occur at a frequency of 1/1000 in European populations at a minor allele frequency of 2.6% in this study [11], yet inherited SRNS/FSGS is a rare disease. It may be present in unaffected control individuals, and most R229Q homozygotes do not have clinical disease. However, it is enriched in patients with SRNS, suggesting that it may have a modifier effect on another pathogenic gene [10, 17]. Machuca *et al.* sequenced all exons of *NPHS1*, *PLCE1*, *TRPC6* and *CD2AP* in eight individuals with SRNS who were R229Q homozygous but did not find an additional mutation [10]. However, there are many other risk genes, some likely undiscovered, which may harbor potentially modifiable variants. This is reflected by another report of SRNS where the proband had a *PAX2* mutation, known to cause renal coloboma syndrome [18], with R229Q homozygosity, but other family members without disease manifestations were homozygous for R229Q alone [17].

A recent study provided insight into the mechanisms by which the R229Q variant plus a pathogenic mutation may cause disease. In a study by Tory *et al.*, it was shown that the R229Q variant only leads to a SRNS/FSGS phenotype when associated with certain *NPHS2* mutations, specifically in exons 7 and 8

of the gene causing substitutions in C-terminal podocin [9]. Their series of experiments demonstrated that the pathogenicity of the R229Q plus a *NPHS2* mutation is probably due to dominant negative effect of the mutation on R229Q variant podocin through altered heterodimerization and mislocalization of the protein. Clinical assessment of patients carrying R229Q has demonstrated that individuals who are compound heterozygotes for the variant plus a pathogenic *NPHS2* mutation have a less severe phenotype with later disease onset, compared with individuals with two pathogenic mutations [10].

The study by Tory *et al.* also adds to the complexity associated with compound heterozygosity of R229Q variant plus 1 pathogenic mutation by showing incomplete penetrance in parents of affected offspring [9]. In total, six of these adults (representing 4.7% of the parents; aged 42–62 years) were found to also be compound heterozygotes for R229Q plus 1 pathogenic mutation but did not manifest a disease phenotype. This study also confirmed the crucial role of the *trans*-associated mutation in determining the pathogenicity of variant R229Q. Mutations in exons 7 and 8 were over-represented in individuals carrying the R229Q plus pathogenic mutations that manifested disease. The authors demonstrated in human podocyte cell lines that R229Q podocin localized correctly to the plasma membrane when co-expressed with wild-type podocin but was retained in the cytoplasm when co-expressed with podocin harboring a pathogenic exon 7 or 8 mutation. This led to altered heterodimerization of the podocin protein. Moreover, Tsukaguchi *et al.* has demonstrated *in vitro*, decreased nephrin binding to R229Q variant podocin [8]. In our patients, the pathogenic mutations present with R229Q were L327F in Case 1 and A297V in Case 2, both in exon 8. Both variants were found to be pathogenic in the study by Tory *et al.* [9]. Additional evidence that these variants are the cause of the disease in these three individuals are as follows: (i) the variants segregate perfectly with the disease in the first family and (ii) both siblings in the second family carried the same variants.

The cases we report highlight the variability of the phenotype seen with the *NPHS2* R229Q variant plus known pathogenic mutations. Individuals may present early and with aggressive disease.

## Acknowledgements

These data were presented as part of an oral poster session at the American Society of Nephrology Kidney Week 2014 (FR-PO237). R.G. is supported by NIH/NIDDK DK098135-01A1, DK094987. R.G. is the recipient of a Doris Duke Clinical Scientist Development Award and acknowledges that part of this work was supported by the Doris Duke Charitable Foundation, Grant #: 2009033. G.H. receives salary support from the NIH/NIDDK Duke Training Grant in Nephrology, 5T32DK0007731. We would like to dedicate this study to Dr Michelle P. Winn, our mentor and friend who we all miss greatly.

## Conflicts of interest statement

The authors declare that they have no conflict of interest.

## References

1. Benoit G, Machuca E, Antignac C. Hereditary nephrotic syndrome: a systematic approach for genetic testing and a review of associated podocyte gene mutations. *Pediatr Nephrol* 2010; 25: 1621–1632
2. Roselli S, Gribouval O, Boute N *et al.* Podocin localizes in the kidney to the slit diaphragm area. *Am J Pathol* 2002; 160: 131–139

3. Boute N, Gribouval O, Roselli S et al. NPHS2, encoding the glomerular protein podocin, is mutated in autosomal recessive steroid-resistant nephrotic syndrome. *Nat Genet* 2000; 24: 349–354
4. Karle SM, Uetz B, Ronner V et al. Novel mutations in NPHS2 detected in both familial and sporadic steroid-resistant nephrotic syndrome. *J Am Soc Nephrol* 2002; 13: 388–393
5. Caridi G, Bertelli R, Scolari F et al. Podocin mutations in sporadic focal-segmental glomerulosclerosis occurring in adulthood. *Kidney Int* 2003; 64: 365
6. Bouchireb K, Boyer O, Gribouval O et al. NPHS2 mutations in steroid-resistant nephrotic syndrome: a mutation update and the associated phenotypic spectrum. *Hum Mutat* 2014; 35: 178–186
7. Pereira AC, Pereira AB, Mota GF et al. NPHS2 R229Q functional variant is associated with microalbuminuria in the general population. *Kidney Int* 2004; 65: 1026–1030
8. Tsukaguchi H, Sudhakar A, Le TC et al. NPHS2 mutations in late-onset focal segmental glomerulosclerosis: R229Q is a common disease associated allele. *J Clin Invest* 2002; 110: 1659–1666
9. Tory K, Menyhárd DK, Woerner S et al. Mutation-dependent recessive inheritance of NPHS2-associated steroid-resistant nephrotic syndrome. *Nat Genet* 2014; 46: 299–304
10. Machuca E, Hummel A, Nevo F et al. Clinical and epidemiological assessment of steroid-resistant nephrotic syndrome associated with the NPHS2 R229Q variant. *Kidney Int* 2009; 75: 727–735
11. Laurin LP, Lu M, Mottl AK et al. Podocyte-associated gene mutation screening in a heterogeneous cohort of patients with sporadic focal segmental glomerulosclerosis. *Nephrol Dial Transplant* 2014; 29: 2062–2069
12. Lipska BS, Iatropoulos P, Maranta R et al. Genetic screening in adolescents with steroid-resistant nephrotic syndrome. *Kidney Int* 2013; 84: 206–213
13. Santín S, Tazón-Vega B, Silva I et al. Clinical value of NPHS2 analysis in early- and adult-onset steroid-resistant nephrotic syndrome. *Clin J Am Soc Nephrol* 2011; 6: 344–354
14. Caridi G, Gigante M, Ravani P et al. Clinical features and long-term outcome of nephrotic syndrome associated with heterozygous NPHS1 and NPHS2 mutations. *Clin J Am Soc Nephrol* 2009; 4: 1065–1072
15. Lu L, Wan H, Yin Y et al. The p.R229Q variant of the NPHS2 (podocin) gene in focal segmental glomerulosclerosis and steroid-resistant nephrotic syndrome: a meta-analysis. *Int Urol Nephrol* 2014; 46: 1383–1393
16. Sadowski CE, Lovric S, Ashraf S et al. A single-gene cause in 29.5% of cases of steroid-resistant nephrotic syndrome. *J Am Soc Nephrol* 2015; 26: 1279–1289
17. Kerti A, Csohany R, Wagner L et al. NPHS2 homozygous p.R229Q variant: potential modifier instead of causal effect in focal segmental glomerulosclerosis. *Pediatr Nephrol* 2013; 28: 2061–2064
18. Sanyanusin P, Schimmenti LA, McNoe LA et al. Mutation of the PAX2 gene in a family with optic nerve colobomas, renal anomalies and vesicoureteral reflux. *Nat Genet* 1995; 9: 358–364