



## Radiopharmaceutical supply disruptions and the use of $^{99m}\text{Tc}$ -hydroxymethylene diphosphonate as an alternative to $^{99m}\text{Tc}$ -pyrophosphate for the diagnosis of transthyretin cardiac amyloidosis: An ASNC Information Statement

Edward J. Miller, MD, PhD, FASNC,<sup>a</sup> Roxana Campisi, MD, FASNC,<sup>b</sup> Nishant R. Shah, MD, MPH, FASNC,<sup>c</sup> Sean McMahan, MD,<sup>d</sup> Sarah Cuddy, MBBCH,<sup>e</sup> Cesia Gallegos-Kattan, MD, MHS,<sup>a</sup> Mathew S. Maurer, MD,<sup>f</sup> Thibaud Damy, MD, PhD,<sup>g</sup> Riemer H. J. A. Slart, MD, PhD,<sup>h</sup> Ketan Bhatia, CNMT,<sup>f</sup> and Andrew J. Einstein, MD, PhD, MASNC<sup>i,j</sup>

<sup>a</sup> Section of Cardiovascular Medicine, Yale School of Medicine, New Haven, CT

<sup>b</sup> Diagnóstico Maipú and Instituto Argentino de Diagnóstico y Tratamiento S.A, Buenos Aires, Argentina

<sup>c</sup> Division of Cardiology, Department of Medicine, Brown University Alpert Medical School, Providence, RI

<sup>d</sup> Hartford HealthCare Heart & Vascular Institute, Hartford Hospital, Hartford, CT

<sup>e</sup> Department of Medicine, Brigham and Women's Hospital, Harvard Medical School, Boston, MA

<sup>f</sup> Seymour, Paul, and Gloria Milstein Division of Cardiology, Department of Medicine, Columbia University Irving Medical Center and NewYork-Presbyterian Hospital, New York, NY

<sup>g</sup> Department of Cardiology, Université Paris-Est Créteil Val de Marne, Université Paris, Paris, France

<sup>h</sup> Department of Nuclear Medicine and Molecular Imaging, Medical Imaging Centre, University Medical Center Groningen, Groningen, The Netherlands

<sup>i</sup> Seymour, Paul, and Gloria Milstein Division of Cardiology, Columbia University Irving Medical Center and NewYork-Presbyterian Hospital, New York, NY

<sup>j</sup> Department of Radiology, Columbia University Irving Medical Center and NewYork-Presbyterian Hospital, New York, NY

Received Jun 23, 2022; accepted Jun 23, 2022

doi:10.1007/s12350-022-03059-5

**Key Words:**  $^{99m}\text{Tc}$ -hydroxymethylene diphosphonate • radiopharmaceutical supply • transthyretin cardiac amyloidosis

Reprint requests: Andrew J. Einstein, MD, PhD, MASNC, Seymour, Paul, and Gloria Milstein Division of Cardiology, Columbia University Irving Medical Center and NewYork-Presbyterian Hospital, 622 West 168th Street PH 10-203, New York, NY 10032; [ae2214@cumc.columbia.edu](mailto:ae2214@cumc.columbia.edu)

J Nucl Cardiol 2022;29:2748–60.  
1071-3581/\$34.00

Copyright © 2022 The Author(s) under exclusive licence to American Society of Nuclear Cardiology

### Abbreviations

ATTR	Amyloid transthyretin
DPD	3,3-Diphosphono-1,2-propanodicarboxylic acid
HMDP	Hydroxymethylene diphosphonate
MDP	Methylene diphosphate
PYP	Pyrophosphate
SPECT	Single photon emission computed tomography
<sup>99m</sup> Tc	Technetium-99m

## INTRODUCTION

There has been a transformation over the past decade in the diagnosis and management of patients with amyloid transthyretin (ATTR) cardiac amyloidosis which has been driven by the development of noninvasive approaches leveraging nuclear scintigraphy and the emergence of effective therapies that significantly improve outcomes of affected patients.<sup>1–3</sup> Based on an international multicenter collaboration,<sup>2</sup> three <sup>99m</sup>technetium-labeled radiotracers, <sup>99m</sup>Tc-3,3-diphosphono-1,2-propanodicarboxylic acid (DPD), <sup>99m</sup>Tc-pyrophosphate (PYP), and <sup>99m</sup>Tc-hydroxymethylene diphosphonate (HMDP), termed “bone avid” and traditionally used for bone scintigraphy, have been shown to have high diagnostic accuracy for the identification of patients with ATTR cardiac amyloidosis when coupled with an assessment for monoclonal proteins to exclude the substrate for AL amyloidosis.<sup>4</sup> The use of these three tracers for ATTR cardiac amyloidosis imaging has been described in recent multi-societal guidelines.<sup>5</sup> Such testing avoids the need for invasive endomyocardial biopsy in the vast majority of affected individuals. Additionally, as nuclear scintigraphy is widely available in most cardiovascular providers’ practices, its use has led to a realization that ATTR cardiac amyloidosis is more prevalent than previously recognized.<sup>6</sup> Accordingly, patients with ATTR cardiac amyloidosis who were previously diagnosed in the later stages of the disease with limited life expectancy are less frequently encountered. This advancement in diagnostic efficacy, which allows effective disease-modifying therapy to be initiated to reduce new amyloid formation but does not address pre-existing amyloid deposits, has been jeopardized by the recent unexpected lack of availability of <sup>99m</sup>Tc-PYP, heretofore virtually the only radiotracer used in the USA for the evaluation of suspected cardiac amyloidosis. To continue to facilitate an early diagnosis

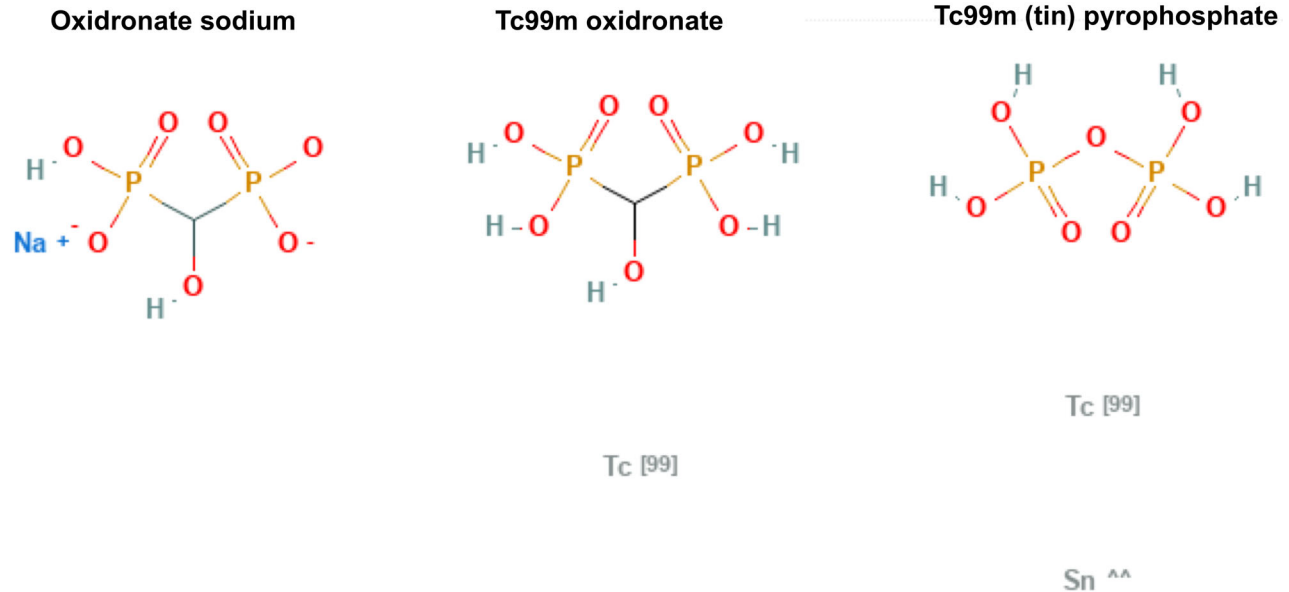
and advance the care of affected patients, the American Society of Nuclear Cardiology (ASNC) is providing this Information Statement to encourage practitioners in the USA to leverage use of <sup>99m</sup>Tc-HMDP, an FDA-approved radiotracer that can diagnose ATTR cardiac amyloidosis and be used in place of <sup>99m</sup>Tc-PYP. This document serves to review the use of <sup>99m</sup>Tc-HMDP in this context.

## DESCRIPTION OF THE SHORTAGE

Prior to 2020, supply chain interruptions only intermittently impacted US healthcare facilities. However, the COVID-19 pandemic has caused unprecedented disruption in industrial supply chains across the globe, which has only been exacerbated in 2022. In particular, workforce shortages due to COVID-19 surges and associated societal lockdowns slowed raw material procurement, manufacturing lines, and shipment processing. Resulting shortages in semiconductors, metals, chemicals, and other raw materials have impaired supply and increased the price of key medical supplies, devices, and pharmaceuticals. Along with other medical specialties, nuclear medicine has been impacted as well. In November 2021, two major US suppliers of radiopharmaceutical agents, Curium Pharma and Sun Radiopharma, who are the sole US providers of the lyophilized kits used to prepare <sup>99m</sup>Tc-PYP in a hot lab at a hospital or radiopharmacy, reported supply interruptions for several nuclear imaging products, including sulfur colloid, mebrofenin, mertiatide, sestamibi, medronate, and PYP. Several chemicals and metals (e.g., tin) are used to create these products, and it is important to note that the supply chain disruptions causing the shortage of PYP are different and appear unrelated to the previous shortages of nuclear cardiology radioisotopes, such as rubidium-82 or technetium-99m. Curium has provided recent updates stating they expect the PYP shortage to continue as long as Sun Radiopharma is unable to provide a supply of PYP. Despite multiple attempts, Sun Radiopharma has not responded by June 22, 2022 to ASNC’s request for comment on when expected supply will return. In the interim, cardiac <sup>99m</sup>Tc-PYP imaging studies to diagnose ATTR cardiac amyloidosis may only be available to patients on an intermittent basis.

## NOMENCLATURE

The nomenclature for <sup>99m</sup>Tc-hydroxymethylene diphosphonate (HMDP) can be a source of confusion. HMDP is also sometimes abbreviated HDP and is also referred to as <sup>99m</sup>Tc-oxidronate. All three terms refer to the same compound. The chemical structure of



**Figure 1.** Chemical structure of oxidronate sodium (left),  $^{99m}\text{Tc}$  oxidronate (center), and  $^{99m}\text{Tc}$  pyrophosphate (note: with stannous conjugate) (right) Source <https://pubchem.ncbi.nlm.nih.gov/compound/123801> and <https://pubchem.ncbi.nlm.nih.gov/compound/6335898>.

oxidronate sodium ( $\text{CH}_4\text{Na}_2\text{O}_7\text{P}_2$ ) is shown in Figure 1. As per the package insert,<sup>7</sup> the reconstitution of oxidronate sodium with  $^{99m}\text{Tc}$ -sodium pertechnetate forms a complex of  $^{99m}\text{Tc}$ -oxidronate ( $\text{CH}_6\text{O}_7\text{P}_2\text{Tc}$ ). HMDP is FDA-approved as a radiopharmaceutical in the USA for use as a skeletal imaging agent to demonstrate areas of altered osteogenesis in adult and pediatric patients and is marketed under the trade name Technescan® HDP. Similar to PYP, it is not FDA-approved specifically for the indication of imaging ATTR cardiac amyloidosis. It is important to note that HMDP/HDP is distinct from another common bone tracer,  $^{99m}\text{Tc}$ -methylene diphosphate ( $^{99m}\text{Tc}$ -MDP), and MDP is not recommended for the diagnosis of ATTR cardiac amyloidosis based on reported reduced sensitivity.<sup>7</sup> HMDP and PYP are reported to have similar rates of blood pool clearance (blood levels 10% at 1 hour), though data directly comparing cardiac blood pool clearance rates between these tracers is lacking in populations at risk for cardiac amyloidosis.

#### **DIFFERENCES IN ACQUISITION BETWEEN $^{99m}\text{Tc}$ -HMDP AND $^{99m}\text{Tc}$ -PYP**

The acquisition protocols for  $^{99m}\text{Tc}$ -HMDP as compared to  $^{99m}\text{Tc}$ -PYP are very similar. Shifting from PYP to HMDP for ATTR cardiac amyloidosis imaging does not require nuclear laboratories to purchase new equipment or software.

Imaging procedures for  $^{99m}\text{Tc}$ -HMDP imaging are shown in Table 1. For  $^{99m}\text{Tc}$ -PYP, cardiac or chest single-photon emitted computed tomography (SPECT) and planar images is recommended two to three hours after PYP injection.<sup>8</sup> Although one-hour imaging has been used in many  $^{99m}\text{Tc}$ -PYP studies<sup>9</sup> and is used by experienced centers with similar results,<sup>10</sup> two- to three-hour imaging is now recommended.<sup>8</sup> Similarly, for  $^{99m}\text{Tc}$ -HMDP, whole-body planar and chest/cardiac SPECT images are obtained two to three hours after HMDP injection using the parameters listed in Table 1. For  $^{99m}\text{Tc}$ -HMDP and  $^{99m}\text{Tc}$ -PYP, SPECT imaging is necessary in all cases.<sup>5</sup>

Whole-body planar imaging may be helpful to identify uptake of HMDP in the shoulder and hip girdles (a specific sign of systemic ATTR amyloidosis) and to identify soft tissue uptake in the extremities, which is a sign of systemic ATTR amyloidosis.<sup>5</sup> Whole-body imaging for HMDP is commonly employed in European practice but is less common in other regions such as Latin America.

Imaging with bone-avid agents (including  $^{99m}\text{Tc}$ -HMDP) for amyloid has already been performed using cadmium zinc telluride (CZT) cameras.<sup>11</sup> The value of  $^{99m}\text{Tc}$ -HMDP imaging with dedicated cardiac CZT cameras needs further validation due to the inability to accurately display bone and lung  $^{99m}\text{Tc}$ -HMDP uptake with these systems.

**Table 1.** Recommendations for standardized acquisition of <sup>99m</sup>Tc-HMDP for cardiac amyloidosis

Imaging procedures	Parameters	Recommendation
Preparation	No specific preparation. No fasting required.	N/A
Scan	Rest scan	Required
Dose	<sup>99m</sup> Tc-HMDP: 10-20 mCi (370-740 MBq) intravenously	Recommended
Time between injection and acquisition: <sup>99m</sup> Tc-HMDP	2 or 3 hours	Recommended
General imaging parameters		
Field of view	Heart or chest	Required
	Whole-body planar	Optional
Image type	Planar	Recommended
	SPECT if planar is positive	Required
Position	Supine	Required
	Upright	Optional
Energy window	140keV, 15-20%	Required
Collimators	Low energy, high resolution	Recommended
Matrix-Planar	256 × 256	Recommended
Matrix-SPECT	128 × 128 (at least 64 by 64 is required)	Recommended
Pixel size	3.5-6.5 mm	Recommended
Planar imaging specific parameters		
Number of views	Chest: Anterior and lateral	Required
	Whole-body: From head to toe	Optional
Detector configuration	90°	Recommended
Image duration (count based)	750,000 or 20 cm per minute	Recommended
Magnification	1.46	Recommended
SPECT imaging specific parameters		
Angular range	180°	Required
	360°	Optional
Detector configuration	90°	Recommended
	180°	Optional
Angular range	360°	Optional
Detector configuration	180°	Optional
ECG gating	Off; Non-gated imaging	Recommended
Number of views/detector	40/32	Recommended
Time per stop	20 seconds/25 seconds	Recommended
Magnification	1.46 (180° angular range)	Recommended
	1.0 (360° angular range)	

2-3-hour imaging is recommended for HMDP, heart or chest imaging is required, and whole-body imaging is optional. Adapted from Dorbala et al.<sup>5</sup>

### DIFFERENCES IN INTERPRETATION BETWEEN <sup>99m</sup>Tc-HMDP AND <sup>99m</sup>Tc-PYP

Interpretation of <sup>99m</sup>Tc-HMDP scans for ATTR cardiac amyloidosis is very analogous to PYP with some minor differences. As with interpretation of <sup>99m</sup>Tc-PYP, a stepwise approach for interpretation of <sup>99m</sup>Tc-HMDP scintigraphy is recommended (see Table 2). The first step is to visually confirm diffuse myocardial radiotracer

uptake and differentiate this uptake from residual blood pool activity or overlapping bone using SPECT and planar images. Interpretation and reporting should comment on focal versus diffuse radiotracer uptake. Diffuse uptake is typically consistent with cardiac amyloidosis, whereas focal uptake may represent early cardiac amyloidosis but has also been described in acute or subacute myocardial infarction.<sup>12</sup> Both planar and

SPECT imaging should be reviewed and interpreted irrespective of the timing of acquisition. SPECT/CT fusion images from attenuation correction CT images are recommended if available and are helpful to localize tracer uptake to the myocardium. The CT images should also be reviewed for potentially clinically meaningful incidental findings.

If myocardial uptake is confirmed visually, the next step is to proceed to semiquantitative grading using the Perugini visual grading scale. This scale is validated for whole-body  $^{99m}\text{Tc}$ -HMDP scintigraphy<sup>13</sup> comparing cardiac uptake to bony uptake in the adjacent ribs. This scale ranges from Grades 0 to 3 (see Table 2). Grade 2 or Grade 3 myocardial uptake of HMDP in the absence of a plasma cell dyscrasia, is diagnostic of ATTR cardiac amyloidosis (see Figure 2). Grade 0 and Grade 1 uptake may be observed in early ATTR cardiac amyloidosis

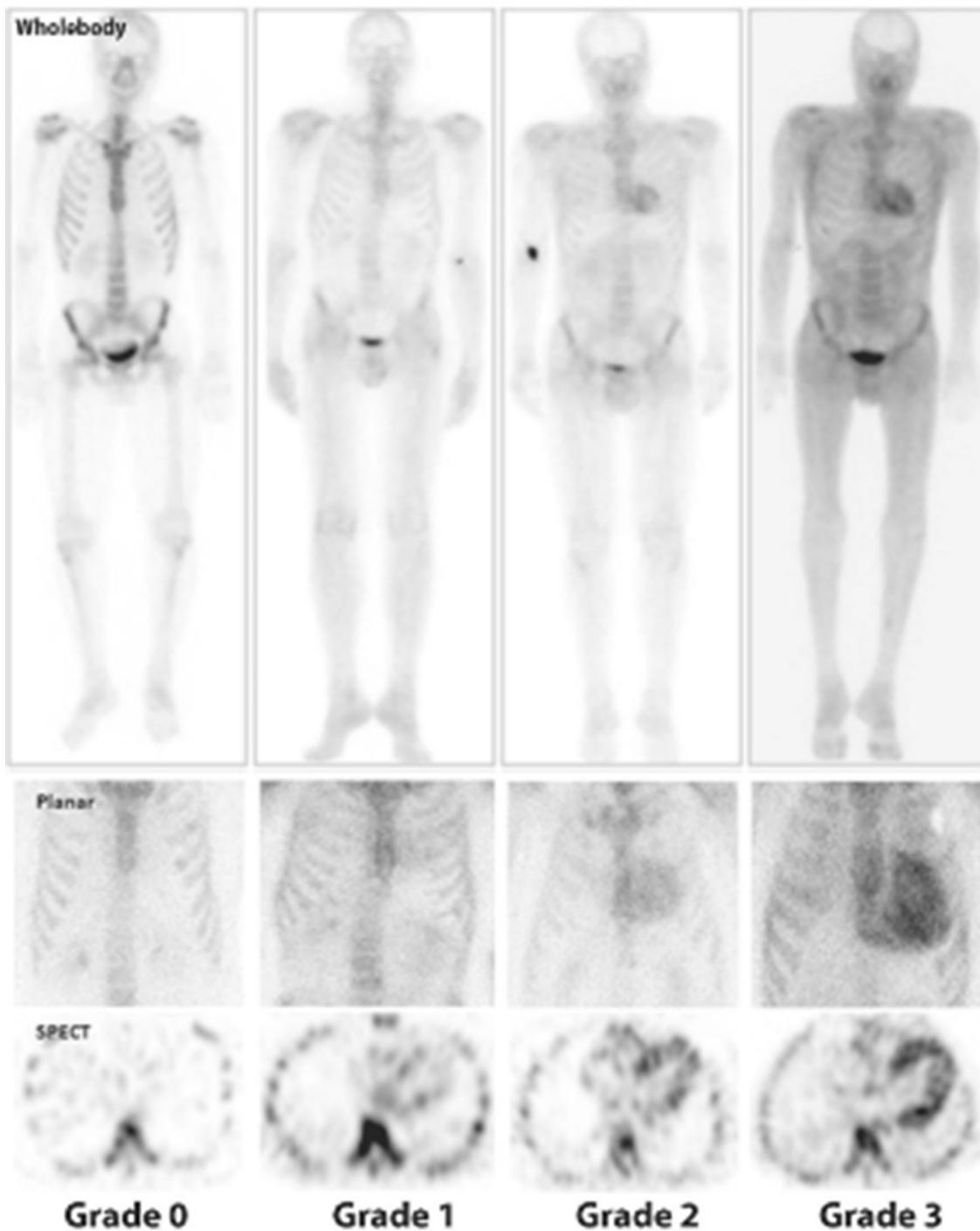
and/or AL cardiac amyloidosis and warrants further evaluation to exclude AL amyloidosis.

As opposed to  $^{99m}\text{Tc}$ -PYP, studies have shown that the H/CL ratio in  $^{99m}\text{Tc}$ -HMDP imaging may be confounded by background noise with increased  $^{99m}\text{Tc}$ -HMDP described in soft tissue, predominantly muscles, in gluteal, shoulder, chest, abdominal wall, liver, skeletal muscle, and lung tissues.<sup>14–16</sup> As such, use of the H/CL ratio is not recommended for HMDP. In addition, there may be differences between  $^{99m}\text{Tc}$ -HMDP and  $^{99m}\text{Tc}$ -PYP in the ability to image extra-cardiac amyloidosis.<sup>17</sup> Compared to other bone-avid tracers,  $^{99m}\text{Tc}$ -HMDP in particular had been shown to have an ability to identify systemic amyloidosis, and therefore it is recommended to report extra-cardiac uptake as well. In a relatively large study from the French Referral Center for Cardiac Amyloidosis,<sup>16</sup> all patients who underwent  $^{99m}\text{Tc}$ -HMDP for suspicion of

**Table 2.** Recommendations for interpretation of  $^{99m}\text{Tc}$ -HMDP for cardiac amyloidosis.

<b>Step 1</b>	<b>Visual interpretation</b>
Evaluate planar and SPECT images to confirm diffuse radiotracer uptake in the myocardium	
Differentiate myocardial radiotracer uptake from residual blood pool activity, focal myocardial infarct, pericarditis, myocarditis, and overlapping bone (e.g., from rib hot spots from fractures) on SPECT images. Certain hereditary subtypes can be false positive and false negative on bone scintigraphy <sup>26</sup> . If excess blood pool activity is noted, recommend repeat SPECT imaging at 3 h	
If myocardial tracer uptake is visually present on SPECT, proceed to step 2, semi-quantitative visual grading. If no myocardial tracer uptake is present on SPECT, the visual grade is 0.	
<b>Step 2</b>	<b>Semi-quantitative grading to distinguish light chain (AL) from ATTR cardiac amyloidosis (2-3-hour approach)</b>
Examine planar and SPECT images for relative tracer uptake in the myocardium relative to ribs and grade using the following scale:	
Grade 0	No myocardial uptake and normal bone uptake
Grade 1	Myocardial uptake less than rib uptake
Grade 2	Myocardial uptake equal to rib uptake
Grade 3	Myocardial uptake greater than rib uptake with mild/absent rib uptake
Grade 2 or Grade 3 uptake is consistent with ATTR cardiac amyloidosis if a monoclonal plasma cell dyscrasia is excluded, as this degree of uptake can be seen in >20% of patients with AL cardiac amyloidosis. Grade 0 and Grade 1 uptake may be observed in AL cardiac amyloidosis and warrants further evaluation to exclude AL amyloidosis. It needs to be emphasized the importance of excluding a monoclonal process with serum/urine immunofixation and a serum-free light chains assay in all patients with suspected amyloidosis <sup>5, 26</sup>	
<b>Step 3</b>	<b>Heart/whole-body uptake ratio assessment (optional for <math>^{99m}\text{Tc}</math>-HMDP)</b>
A circular region of interest (ROI) should be drawn over the heart on the anterior planar images with care to avoid sternal overlap and with size adjusted to maximize coverage of the heart without inclusion of adjacent lung. A heart to whole-body (H/WB) ratio is calculated as the fraction of heart ROI mean counts to the WB mean counts <sup>20</sup>	

H/CL ratio is not recommended for HMDP.  
Adapted from Dorbala et al.<sup>5</sup>



**Figure 2.** Examples of Grade 0-3 images. Visual grading scale for cardiac uptake on whole-body (top) and chest (middle) planar imaging, and chest SPECT (bottom) imaging (from left to right: grade 0, 1, 2, and 3) <sup>5</sup>.

cardiac amyloidosis between 2010 and 2017 were reviewed using a protocol that included a whole-body scan including the thyroid, lungs and pleura,

myocardium, liver, spleen, gastrointestinal tract, and kidneys. Extra-cardiac uptake was found in 74 patients, including 72 with cardiac amyloidosis and 2 controls.

Extra-cardiac uptake was found predominantly in the lungs and pleura in ATTR and in AL, followed by the digestive track and subcutaneous tissues in hereditary ATTR and AL cardiac amyloidosis. Another study by Monfort et al,<sup>18</sup> specifically looked at lung retention in hereditary ATTR, showing that pulmonary retention of HMDP was higher in hereditary ATTR amyloidosis patients compared with age and sex matched control subjects. Another study from Cappelli et al<sup>19</sup> found  $^{99m}\text{Tc}$ -HMDP scintigraphy showed lung uptake in almost 60% of subjects with ATTR amyloidosis, and that the incidence of lung uptake was significantly correlated to the grade of heart retention according to Perugini visual score.

Heart/whole-body (H/WB) ratio and standardized uptake value (SUV) measurements are not commonly used but are emerging concepts in HMDP SPECT imaging. H/WB and its cutoff values have also been described in the literature as a robust and effective way of diagnosing cardiac amyloidosis; however, further research is necessary to incorporate it into practice.<sup>20-22</sup> Heart-to-skull (H/S) ratio has also been used but more recently was found by Gallini et al<sup>23</sup> in a small series, to have worse performance than other indices. With recent developments in imaging technology, quantitative SPECT using either kBq/cc or SUVs is feasible using the new solid-state (CZT) SPECT/CT cameras. The feasibility of this technique using  $^{99m}\text{Tc}$ -HMDP was shown by Bellevre et al.<sup>22</sup> They evaluated 15 patients with suspected cardiac ATTR amyloidosis (Perugini  $\geq 2$ ) with a DNM 670CZT camera and a control group consisted of 15 patients with negative scintigraphy (Perugini  $< 2$ ). All ATTR amyloidosis patients demonstrated an increased cardiac HMDP SUV<sub>max</sub> ( $12.2 \pm 3.7$  mg·L) vs controls ( $3.5 \pm 1.2$ ,  $P < .0001$ ). Despite these preliminary data on quantification, qualitative interpretation of  $^{99m}\text{Tc}$ -HMDP uptake remains standard and recommended.

While rare, it is recognized that there is reduced sensitivity of cardiac scintigraphy with  $^{99m}\text{Tc}$ -biphosphonate derived radiopharmaceuticals such as HMDP and DPD in patients with certain TTR mutations. Some reports suggest that patients with ATTR cardiac amyloidosis and mutations, such as Phe64Leu, have low or absent myocardial bone-tracer uptake, suggesting that heightened sensitivity for ATTR cardiac amyloidosis may be necessary in these patients, and diagnostic modalities beyond cardiac bone scintigraphy may be needed.<sup>23</sup>

Detailed recommendations for standardized reporting are provided in Table 3.

## BILLING FOR $^{99m}\text{Tc}$ -HMDP IN THE USA

Several Current Procedural Terminology (CPT)© billing codes can be used for reimbursement for  $^{99m}\text{Tc}$ -HMDP scans. These include one of three Category I CPT codes selected for imaging, and a separate level II Healthcare common Procedure Coding System (HCPCS) code Level II used for the radiopharmaceutical. The selection of which CPT code depends on whether the study is performed with planar imaging alone (78800), with SPECT imaging with or without planar imaging (78803), and with SPECT/CT imaging (78830) with or without planar imaging. Use of planar imaging alone for cardiac amyloidosis is only recommended if these planar images are reviewed by a physician and determined to be Perugini Grade 0 before discharging the patient from the nuclear cardiology laboratory; otherwise, it is important to note that all patients should receive SPECT or SPECT/CT imaging. This recommendation is codified in a revision to the recent multi-societal cardiac amyloidosis imaging guidelines.<sup>5</sup> In general, reimbursement is highest for SPECT/CT and lowest for planar imaging alone.

In more detail, the American Medical Association's CPT description for 78800 is for "Radiopharmaceutical localization of tumor, inflammatory process or distribution of radiopharmaceutical agent(s) (includes vascular flow and blood pool imaging, when performed); planar, single area (e.g., head, neck, chest, pelvis), single day imaging," 78803 for "Radiopharmaceutical localization of tumor, inflammatory process or distribution of radiopharmaceutical agent(s) (includes vascular flow and blood pool imaging, when performed); tomographic (SPECT), single area (e.g., head, neck, chest, pelvis), single day imaging," and 78830 for "Radiopharmaceutical localization of tumor, inflammatory process or distribution of radiopharmaceutical agent(s) (includes vascular flow and blood pool imaging, when performed); tomographic (SPECT) with concurrently acquired computed tomography (CT) transmission scan for anatomical review, localization and determination/detection of pathology, single area (e.g., head, neck, chest, pelvis), single day imaging."<sup>24</sup> As described above,  $^{99m}\text{Tc}$ -HMDP is equivalent to  $^{99m}\text{Tc}$ -oxidronate, and thus the Category II code A9561 for "Technetium tc-99m [*sic*] oxidronate, diagnostic, per study dose, up to 30 millicuries" should be used to bill for the HMDP.

## COMPARISONS BETWEEN HMDP AND PYP

Direct comparison data between the bisphosphonate derivatives  $^{99m}\text{Tc}$ -DPD, -PYP, and -HMDP for ATTR cardiac amyloidosis are limited. Nonetheless, in aggregate the cardiac uptake of these radioisotopes is

**Table 3.** Recommendations for standardized reporting of <sup>99m</sup>Tc-HMDP imaging for cardiac amyloidosis

Parameter	Items
Demographics	Patient name, age, sex, reason for the test, date of study, prior imaging procedures, biopsy results if available (Required)
Methods	Imaging technique, radiotracer dose and mode of administration, interval between injection and scan, scan technique (planar and SPECT) (Required)
Findings	Image quality Visual scan interpretation (Required) Semi-quantitative interpretation in relation to rib uptake
Ancillary findings	Whole-body imaging if planar whole-body images are acquired (Optional) Interpret CT for attenuation correction if SPECT/CT scanners are used (Recommended) Include extra-cardiac/soft tissue uptake (Recommended)
Conclusions	1. An overall interpretation of the findings into categories of (1) not suggestive of ATTR cardiac amyloidosis; (2) strongly suggestive of ATTR cardiac amyloidosis; or (3) equivocal for ATTR cardiac amyloidosis after exclusion of a systemic plasma cell dyscrasia (Required) a. Not suggestive: A semi-quantitative visual grade of 0. b. Equivocal: If diffuse myocardial uptake of <sup>99m</sup> Tc-HMDP is visually confirmed and the semi-quantitative visual grade is 1 or there is interpretive uncertainty of grade 1 versus grade 2 on visual grading. c. Strongly suggestive: If diffuse myocardial uptake of <sup>99m</sup> Tc-HMDP is visually confirmed, a semi-quantitative visual grade of 2 or 3. 2. Statement that evaluation for light chain (AL) amyloidosis by serum-free light chain assay, and serum and urine immunofixation is recommended in all patients undergoing <sup>99m</sup> Tc-HMDP scans for cardiac amyloidosis. (Required) 3. Statement that results should be interpreted in the context of prior evaluation and referral to a hematologist or amyloidosis expert is recommended if either: a. Recommended echo/cardiac magnetic resonance is strongly suggestive of cardiac amyloidosis and <sup>99m</sup> Tc-HMDP is not suggestive or equivocal and/or b. Free light chains are abnormal or equivocal. (Recommended)

Adapted from Dorbala et al. <sup>5</sup>

sensitive and highly specific for ATTR cardiac amyloidosis when AL amyloidosis is excluded.<sup>2</sup> Meta-analyses of published data suggest <sup>99m</sup>Tc-HMDP may be slightly more accurate than <sup>99m</sup>Tc-PYP and/or similar to <sup>99m</sup>Tc-DPD.<sup>21,28</sup>

The largest report that includes all three radiotracers is a retrospective multicenter referral population experience that included 1498 patients. This study showed a positive predictive value of all bone scintigraphy agents for ATTR cardiac amyloidosis of 100% (95% confidence interval 98.0-100) in patients with an echocardiogram or CMR consistent with or suggestive of cardiac amyloidosis and absence of monoclonal protein.<sup>2</sup> Of the 1217 subjects included in the analysis, 877 were imaged with <sup>99m</sup>Tc-DPD, 199 <sup>99m</sup>Tc-PYP, and 141 <sup>99m</sup>Tc-HMDP. The findings for all 141 subjects who underwent <sup>99m</sup>Tc-HMDP imaging are shown in Table 4.

There was just one subject with any HMPD uptake that did not have ATTR cardiac amyloidosis, and this patient had Grade 1 uptake and had AL amyloidosis. Compared to endomyocardial biopsy, the specificity of <sup>99m</sup>Tc-HMDP was 100%, as summarized in Table 5; these data are limited by the relative paucity of EMBs performed in the <sup>99m</sup>Tc-HMDP cohort in that report. The sensitivity decreased for myocardial uptake of ≥ grade 2 to 79% for those who had an endomyocardial biopsy and 80% for all subjects; this dropped further when presence of a monoclonal gammopathy was also included in diagnostic criteria. There have been several other small, predominantly single center studies evaluating the diagnostic accuracy of <sup>99m</sup>Tc-HMDP, with similar findings in Table 6.

There is no prospective direct comparison between all three bone scintigraphy tracers for ATTR cardiac



**Table 4.** <sup>99m</sup>Tc-HMDP scans in amyloidosis

Diagnosis	<sup>99m</sup> Tc-HMDP scan findings				
	Grade 0 N = 90	Grade 1 N = 11	Grade 2 N = 28	Grade 3 N = 12	All N = 141
<b>No cardiac amyloid</b>	<b>77</b>	<b>0</b>	<b>0</b>	<b>0</b>	<b>77</b>
Amyloidosis without cardiac amyloid infiltration	11	0	0	0	11
AL, no cardiac amyloid	0	0	0	0	0
ATTR, no cardiac amyloid	10	0	0	0	10
AApoAI, no cardiac amyloid	0	0	0	0	0
ALys, no cardiac amyloid	0	0	0	0	0
AFib, no cardiac amyloid	1	0	0	0	1
AA, no cardiac amyloid	0	0	0	0	0
AGel, no cardiac amyloid	0	0	0	0	0
<i>Unknown amyloidosis type, no cardiac amyloid</i>	0	0	0	0	0
Localized AL, no cardiac amyloid	0	0	0	0	0
No amyloidosis	66	0	0	0	66
<i>Anderson-Fabry</i>	0	0	0	0	0
Heart failure with preserved ejection fraction (HFPEF)	0	0	0	0	0
Hypertrophic cardiomyopathy (HCM)	0	0	0	0	0
Hypertensive cardiomyopathy	0	0	0	0	0
<i>TTR mutation carriers, no amyloid</i>	14	0	0	0	14
Cardiac light chain deposition disease	0	0	0	0	0
Undefined cardiomyopathy	52	0	0	0	52
<b>Cardiac amyloid</b>	<b>13</b>	<b>11</b>	<b>28</b>	<b>12</b>	<b>64</b>
Cardiac ATTR amyloid	0	10	28	12	50
Cardiac AL amyloidosis	13	1	0	0	14
Cardiac apoAI amyloidosis	0	0	0	0	0
Cardiac amyloidosis of unknown type	0	0	0	0	0

Adapted from Gillmore et al.<sup>2</sup>**Table 5.** Sensitivity and specificity of <sup>99m</sup>Tc-HMDP scintigraphy vs. endomyocardial biopsy (EMB) histology

<b>Perugini grade 2 or 3 <sup>99m</sup>Tc-HMDP scan vs cardiac ATTR amyloid (N = 21 [141])</b>			
	Grade 2/3 scan	Grade 0/1 scan	
Cardiac ATTR amyloid	11 (40)	3 (10)	79% (80%) sensitive
No cardiac ATTR amyloid	0 (0)	7 (90)	100% (100%) specific
<b>Perugini grade 2 or 3 <sup>99m</sup>Tc-HMDP scan + absence of clone vs ATTR amyloid (N = 21 [141])</b>			
	Grade 2/3 scan + no clone	Grade 0/1 scan OR clone	
Cardiac ATTR amyloid	8 (37)	6 (13)	57% (74%) sensitive
No cardiac ATTR amyloid	0 (0)	7 (90)	100% (100%) specific

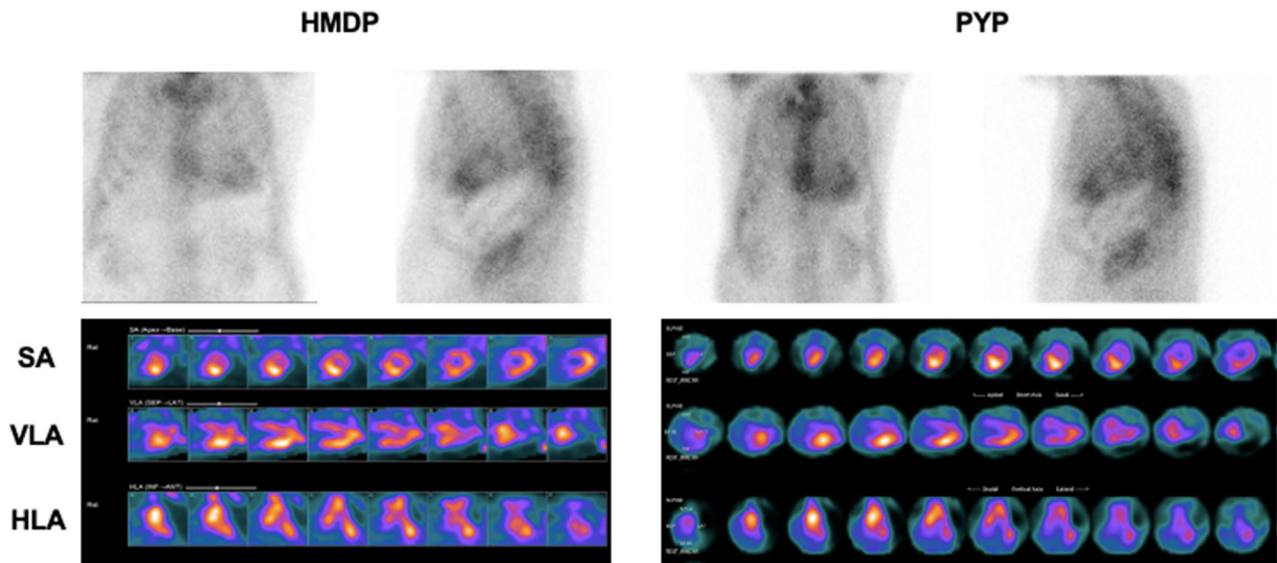
Results for 21 Patients with EMB with Results for All 141 in Parentheses

Adapted from Gillmore et al.<sup>2</sup>

**Table 6.** Key literature summarizing the diagnostic value of <sup>99m</sup>Tc-HMDP radionuclide imaging for cardiac amyloidosis from expert consensus recommendations.<sup>5</sup>

Author	Year	N Amyloidosis	N controls	Patient cohort/diagnostic standard	Criterion	Sensitivity	Specificity	Comments
Galat <sup>27</sup>	2015	69: wtATTR-CA: 21, AL-CA: 14, vATTR-CA: 26, vATTR-N: 4, asymp carriers: 4	52: (other CMP [37 with LVH; 15 no LVH])	Prospective/various organ biopsy with IHC+ genotyping + echo	(a) Visual score $\geq$ 1 (amyloidosis vs control) (b) Visual score $\geq$ 2 (identification of ATTR pts with cardiac amyloidosis)	(a) 75% (b) 83%	(a) 100% (b) 100%	Evaluation of diagnostic accuracy in the etiological diagnosis (in identification of ATTR pts) All ATTRv without cardiac amyloidosis and carriers had no cardiac uptake All controls had no cardiac uptake
Galat <sup>28</sup>	2016	93: wtATTR-CA: 33, AL-CA: 19, vATTR-CA: 33, vATTR-N: 5, asymptomatic carriers: 3	31 pts with LVH	Prospective/various organ biopsy with IHC+ genotyping + echo	H/Mediastinum > 1.11 (early phase) = cardiac fixation. 1.11-1.21 $\approx$ Perugini 1 > 1.21 $\approx$ Perugini 2-3	If H/M > 1.21 : 100% (for detecting ATTR pts vs AL)	If H/M > 1.21 : 100% (for detecting ATTR pts vs AL)	
Cappelli <sup>21</sup>	2017	65: ATTRwt: 23, ATTRm: 16, AL: 26	20	Retrospective/various organ biopsy with IHC + genotyping + echo	Visual score $\geq$ 2	100% (for detecting ATTR pts vs AL)	93%	Evaluation of diagnostic accuracy in the etiological diagnosis (identification of ATTR pts) Evaluation of LV distribution of early phase uptake
Van Der Gucht <sup>29</sup>	2017	61:	-	Prospective/various organ biopsy with IHC + genotyping + echo	Cardiac uptake in the early phase	100%	-	

AL-CA, light chain cardiac amyloidosis; ATTRm, amyloid transthyretin mutation; vATTR-CA, variant (hereditary) amyloid transthyretin cardiac amyloidosis; wtATTR-CA, ATTRwt, wild-type amyloid transthyretin cardiac amyloidosis



**Figure 3.** Example of  $^{99m}\text{Tc}$  HMDP (left) and  $^{99m}\text{Tc}$  PYP (right) images taken from the same patient in early 2022. Both sets of images were taken at 3 hours after injection of tracer. Anterior and lateral planar images (top row) and SPECT images (bottom). SA, short axis, VLA, vertical long axis, HLA, horizontal long axis. Note that this positive study is visualized well using cardiac reformats in the SA, VLA, and HLA planes, however, studies not as clearly positive may be more challenging to interpret using these reformats, and especially benefit from SPECT/CT imaging. Courtesy of Daniel Y. Wang, MD, Daniel B. Sims, MD, and Edward J. Miller, MD, PhD.

amyloidosis. One small study of 6 patients with hereditary ATTR amyloidosis assessed both  $^{99m}\text{Tc}$ -HMDP and  $^{99m}\text{Tc}$ -DPD and found no statistical difference between heart to mediastinal (H/M) ratios.<sup>25</sup>

Anecdotally, initial experience of using  $^{99m}\text{Tc}$ -HMDP at US centers familiar with  $^{99m}\text{Tc}$ -PYP suggest that a 3-hour HMDP imaging protocol is associated with image quality that is at least equivalent to  $^{99m}\text{Tc}$ -PYP and potentially with lower blood pool activity. These findings need empiric confirmation. Figure 3 shows  $^{99m}\text{Tc}$ -PYP images followed 2 months later by  $^{99m}\text{Tc}$ -HMDP images from the same patient in early 2022 in the USA, demonstrating excellent correlation of imaging findings between the tracers with no interval treatment. This example is particularly illustrative as the grade of myocardial uptake (Grade 2) on planar images and contours on SPECT (including an apical hot spot) are similar between both  $^{99m}\text{Tc}$ -PYP and  $^{99m}\text{Tc}$ -HMDP images.

## SUMMARY AND CONCLUSION

In summary, disruption of the supply of PYP should not lead to delay in the scintigraphic diagnosis of ATTR cardiac amyloidosis. Rather, HMDP is a reasonable alternative given its comparable image quality and diagnostic performance, and its use in the US and

internationally, as detailed above, is endorsed by ASNC. At the same time, more data are needed comparing the existing bone-avid radiotracers in the context of amyloidosis diagnosis, including comparative human studies in which patients are imaged using more than one of these radiopharmaceuticals.

## Disclosures

*Dr. Campisi has received a consultant fee from Roivant. Dr. Cuddy has received grant support from Pfizer; she has received speaker fees from BridgeBio, Ionis, and the Lynx Group. Dr. Damy serves on the advisory board of Alnylam, Akcea, Astra Zeneca, Neurimmune, Pfizer, Vifor; has received grant support from Akcea, Neurimmune, Pfizer, Vifor; has received speaker fees from Alnylam, Pfizer, and Vifor. Dr. Einstein has received speaker fees from Ionetix; has received consulting fees from W. L. Gore & Associates; has received authorship fees from Wolters Kluwer Healthcare – UpToDate; and has received grants or grants pending to his institution from Attralus, Canon Medical Systems, Eidos Therapeutics, GE Healthcare, Pfizer, Roche Medical Systems, W. L. Gore & Associates, and XyloCor Therapeutics. Dr. Gallegos-Kattan serves on the advisory board of Alnylam. Dr. Maurer has received grant support from Akcea/Ionis, Alnylam Pharmaceuticals Inc., Eidos Therapeutics, GlaxoSmithKline Pharmaceutical, Pfizer, Prothena Corp., and the National Institute of Health/National Institute on Aging/National Heart, Lung, and Blood Institute. Dr. McMahon has served as a consultant to Lantheus and Pfizer. Dr. Edward J. Miller has*

served as a consultant to Bracco, Pfizer, GE Healthcare, and Alnylam; he has received grant support from Bracco, Eidos, Alnylam, and Pfizer. Dr. Shah has received grant support from Pfizer and holds stock ownership in General Electric. Dr. Slart has received independent research grants from Pfizer and Siemens Healthineers. Mr. Bhatia has nothing relevant to disclose.

## References

1. Ruberg FL, Grogan M, Hanna M, Kelly JW, Maurer MS. Transthyretin amyloid cardiomyopathy. *J Am Coll Cardiol* 2019;73:2872-91.
2. Gillmore JD, Maurer MS, Falk RH, Merlini G, Damy T, Dispenzieri A. Nonbiopsy diagnosis of cardiac transthyretin amyloidosis. *Circulation* 2016;133:2404-12.
3. Maurer MS, Schwartz JH, Gundapaneni B, Elliott PM, Merlini G, Waddington Cruz M, et al. Tafamidis treatment for patients with transthyretin amyloid cardiomyopathy. *N Engl J Med* 2018;379:1007-16.
4. Hanna M, Ruberg FL, Maurer MS, Dispenzieri A, Dorbala S, Falk RH, et al. Cardiac scintigraphy with technetium-99m-labeled bone-seeking tracers for suspected amyloidosis: JACC review topic of the week. *J Am Coll Cardiol* 2020;75:2851-62.
5. Dorbala S, Ando Y, Bokhari S, Dispenzieri A, Falk RH, Ferrari VA, et al. ASNC/AHA/ASE/EANM/HFSA/ISA/SCMR/SNMMI expert consensus recommendations for multimodality imaging in cardiac amyloidosis: Part 1 of 2-evidence base and standardized methods of imaging. *J Nucl Cardiol* 2019;26:2065-123.
6. Maurer MS. Noninvasive identification of ATTRwt cardiac amyloid: The re-emergence of nuclear cardiology. *Am J Med* 2015;128:1275-80.
7. Cuscaden C, Ramsay SC, Prasad S, Goodwin B, Smith J. Estimation of prevalence of transthyretin (ATTR) cardiac amyloidosis in an Australian subpopulation using bone scans with echocardiography and clinical correlation. *J Nucl Cardiol* 2021;28:2845-56.
8. Dorbala S, Ando Y, Bokhari S, Dispenzieri A, Falk RH, Ferrari VA, et al. Addendum to ASNC/AHA/ASE/EANM/HFSA/ISA/SCMR/SNMMI expert consensus recommendations for multimodality imaging in cardiac amyloidosis: Part 1 of 2-evidence base and standardized methods of imaging. *J Nucl Cardiol* 2020;27:659-673. Erratum in: *J Nucl Cardiol* 2021;28:1763-67.
9. Bokhari S, Castaño A, Pozniakoff T, Deslisle S, Latif F, Maurer MS. (99m)Tc-pyrophosphate scintigraphy for differentiating light-chain cardiac amyloidosis from the transthyretin-related familial and senile cardiac amyloidoses. *Circ Cardiovasc Imaging* 2013;6:195-201.
10. Sperry BW, Burgett E, Bybee KA, McGhie AI, O'Keefe JH, Saeed IM, et al. Technetium pyrophosphate nuclear scintigraphy for cardiac amyloidosis: Imaging at 1 vs 3 hours and planar vs SPECT/CT. *J Nucl Cardiol* 2020;27:1802-7.
11. Flaherty KR, Morgenstern R, Pozniakoff T, DeLuca A, Castano A, Maurer MS, et al. 99m Technetium pyrophosphate scintigraphy with cadmium zinc telluride cameras is a highly sensitive and specific imaging modality to diagnose transthyretin cardiac amyloidosis. *J Nucl Cardiol* 2020;27:371-80.
12. Parkey RW, Bonte FJ, Meyer SL, Atkins JM, Curry GL, Stokely EM, et al. A new method for radionuclide imaging of acute myocardial infarction in humans. *Circulation* 1974;50:540-6.
13. Perugini E, Guidalotti PL, Salvi F, Cooke RMT, Pettinato C, Riva L, et al. Noninvasive etiologic diagnosis of cardiac amyloidosis using <sup>99m</sup>Tc-3,3-diphosphono-1,2-propanodicarboxylic acid scintigraphy. *J Am Coll Cardiol* 2005;46:1076-84.
14. Hutt DF, Quigley A-MM, Page J, Hall ML, Burniston M, Gopaul D, et al. Utility and limitations of 3,3-diphosphono-1,2-propanodicarboxylic acid scintigraphy in systemic amyloidosis. *Eur Heart J Cardiovasc Imaging* 2014;15:1289-98.
15. Bach-Gansmo T, Wien TN, Løndalen A, Halvorsen E. Myocardial uptake of bone scintigraphic agents associated with increased pulmonary uptake. *Clin Physiol Funct Imaging* 2016;36:237-41.
16. Malka N, Abulizi M, Kharoubi M, Oghina S, Galat A, Le Bras F, et al. Extracardiac soft tissue uptake, evidenced on early <sup>99m</sup>Tc-HMDP SPECT/CT, helps typing cardiac amyloidosis and demonstrates high prognostic value. *Eur J Nucl Med Mol Imaging* 2020;47:2396-406.
17. Rapezzi C, Gagliardi C, Milandri A. Analogies and disparities among scintigraphic bone tracers in the diagnosis of cardiac and non-cardiac ATTR amyloidosis. *J Nucl Cardiol* 2019;26:1638-41.
18. Monfort A, Rivas A, Banydeen R, Inamo J, Farid K, Neviere R. Pulmonary <sup>99m</sup>Tc-HMDP uptake correlates with restrictive ventilatory defects and abnormal lung reactivity in transthyretin cardiac amyloidosis patients. *Respir Res* 2022;23:72.
19. Cappelli F, Gallini C, Costanzo EN, Tutino F, Ciaccio A, Vaggelli L, et al. Lung uptake during <sup>99m</sup>Tc-hydroxymethylene diphosphonate scintigraphy in patient with TTR cardiac amyloidosis: An underestimated phenomenon. *Int J Cardiol* 2018;254:346-50.
20. Gallini C, Tutino F, Martone R, Ciaccio A, Costanzo EN, Taborchi G, et al. Semi-quantitative indices of cardiac uptake in patients with suspected cardiac amyloidosis undergoing <sup>99m</sup>Tc-HMDP scintigraphy. *J Nucl Cardiol* 2021;28:90-9.
21. Cappelli F, Gallini C, Di Mario C, Costanzo EN, Vaggelli L, Tutino F, et al. Accuracy of <sup>99m</sup>Tc-Hydroxymethylene diphosphonate scintigraphy for diagnosis of transthyretin cardiac amyloidosis. *J Nucl Cardiol* 2019;26:497-504.
22. Bellevre D, Bailliez A, Delelis F, Blaie T, Agostini D, Mouquet F, et al. Quantitation of myocardial <sup>99m</sup>Tc-HMDP uptake with new SPECT/CT cadmium zinc telluride (CZT) camera in patients with transthyretin-related cardiac amyloidosis: Ready for clinical use? *J Nucl Cardiol* 2022;29:506-14.
23. Musumeci MB, Cappelli F, Russo D, Tini G, Canepa M, Milandri A, et al. Low sensitivity of bone scintigraphy in detecting Phe64Leu mutation-related transthyretin cardiac amyloidosis. *JACC Cardiovasc Imaging* 2020;13:1314-21.
24. Graves SA, Bageac A, Crowley JR, Merlino DAM. Reimbursement approaches for radiopharmaceutical dosimetry: Current status and future opportunities. *J Nucl Med* 2021;62:48S-59S.
25. Abulizi M, Cottureau AS, Guellich A, Vandeventer S, Galat A, Van Der Gucht A, et al. Early-phase myocardial uptake intensity of <sup>99m</sup>Tc-HMDP vs <sup>99m</sup>Tc-DPD in patients with hereditary transthyretin-related cardiac amyloidosis. *J Nucl Cardiol* 2018;25:217-22.
26. Garcia-Pavia P, Rapezzi C, Adler Y, Arad M, Basso C, Brucato A, et al. Diagnosis and treatment of cardiac amyloidosis. A position statement of the European Society of Cardiology Working Group on Myocardial and Pericardial Diseases. *Eur J Heart Fail* 2021;23:512-26.
27. Galat A, Rosso J, Guellich A, Van Der Gucht A, Rappeneau S, Bodez D, et al. Usefulness of <sup>99m</sup>Tc-HMDP scintigraphy for the etiologic diagnosis and prognosis of cardiac amyloidosis. *Amyloid* 2015;22:210-20.
28. Galat A, Van der Gucht A, Guellich A, Bodez D, Cottureau AS, Guendouz S, et al. Early phase <sup>99m</sup>Tc-HMDP scintigraphy for the diagnosis and typing of cardiac amyloidosis. *JACC Cardiovasc Imaging* 2017;10:601-3.

29. Van Der Gucht A, Cottureau AS, Abulizi M, Guellich A, Blanc-Durand P, Israel JM, et al. Apical sparing pattern of left ventricular myocardial  $^{99m}\text{Tc}$ -HMDP uptake in patients with transthyretin cardiac amyloidosis. *J Nucl Cardiol* 2018;25:2072-9.

**Publisher's Note** Springer Nature remains neutral with regard to jurisdictional claims in published maps and institutional affiliations.