

## EDITORIAL

# Iatrogenic myocarditis—biomarkers, cardiovascular MRI and the need for early diagnosis

Amrit S. Lota<sup>1</sup>, Brian P. Halliday<sup>1</sup> and Vassilios S Vassiliou<sup>1,2,\*</sup>

<sup>1</sup>National Heart & Lung Institute, Imperial College London, Royal Brompton Hospital, Sydney Street, London SW3 6NP, UK, and <sup>2</sup>Norwich Medical School, University of East Anglia Norfolk, Norfolk and Norwich University Hospital, Norwich, UK

\*Correspondence address. National Heart & Lung Institute, Imperial College London, Royal Brompton Hospital, Sydney Street, London SW3 6NP, UK.  
Tel: +020-73-52-8121, Ext. 2920; Fax: +020-73-51-8146; E-mail: v.vassiliou@rbht.nhs.uk

Myocarditis remains a challenging diagnosis that arises from a range of potential insults that can result in cardiac inflammation, immune activation and functional impairment [1]. Acute viral infection represents the leading aetiology followed by drug-induced hypersensitivity, giant cell myocarditis and cardiac involvement in systemic autoimmune disease [2]. Due to heterogeneity in clinical presentation and disease severity, accurate epidemiological assessment is limited but overall prevalence is estimated at 22 cases per 100 000 patients annually [3]. Clozapine is the cornerstone of therapy in refractory schizophrenia and significantly reduces suicide rates further than other antipsychotic agents [4]. However, cardiotoxicity resulting in myocarditis can occur in 1–3% of patients and can result in complications including sudden cardiac death and heart failure [5, 6].

The case report by Datta and Solomon [7] describes a young patient presenting acutely with chest pain, ST segment elevation and mild troponin level elevation. Following the demonstration of unobstructed coronary arteries on invasive angiography and impaired left ventricular function on transthoracic echocardiography, a diagnosis of myocarditis likely secondary to clozapine was reached. This report emphasizes the need for prompt recognition of myocarditis and immediate withdrawal of therapy where clozapine-induced myocarditis is suspected. These features appeared 2 days after starting clozapine therapy. However, it should be noted that symptoms are often non-specific with chest pain occurring in only half of all cases and clinical presentation varying between Days 14 and 21 after therapy initiation [8, 9]. In some cases, presentations may indeed be delayed by several months requiring a high degree of clinical suspicion for diagnosis [10].

At present, the gold standard for diagnosis of myocarditis remains an endomyocardial biopsy [11]. Histopathological analysis with immunostaining confirms the presence and characterizes the nature of acute inflammatory infiltrates. However, the limitations of endomyocardial biopsy are many and include high rates of sampling error, interobserver variability and periprocedural risks of cardiac tamponade and death. For these reasons, endomyocardial biopsy is rarely a practical first step in the diagnosis of myocarditis in the majority of centres.

Cardiovascular magnetic resonance imaging (CMR) has emerged as an important diagnostic tool for the non-invasive assessment of acute myocarditis. Standard myocardial tissue characterization techniques can detect myocardial oedema, reactive hyperaemia and replacement fibrosis from myocyte cell death [12]. Diagnostic accuracy is further enhanced with novel T1 and T2 mapping approaches as shown in Fig. 1 [13]. CMR also plays an equally important role in the exclusion of other causes of troponin-positive chest pain and unobstructed coronary arteries, such as infarction due to recanalisation, spasm or embolism [14]. However, access to CMR is often limited and may be impractical as a screening test in all patients. Circulating biomarkers of myocardial injury, such as troponin, represent a more feasible initial investigation and possible approach for routine interval screening, which is relevant given that clinical presentation can be non-specific [9].

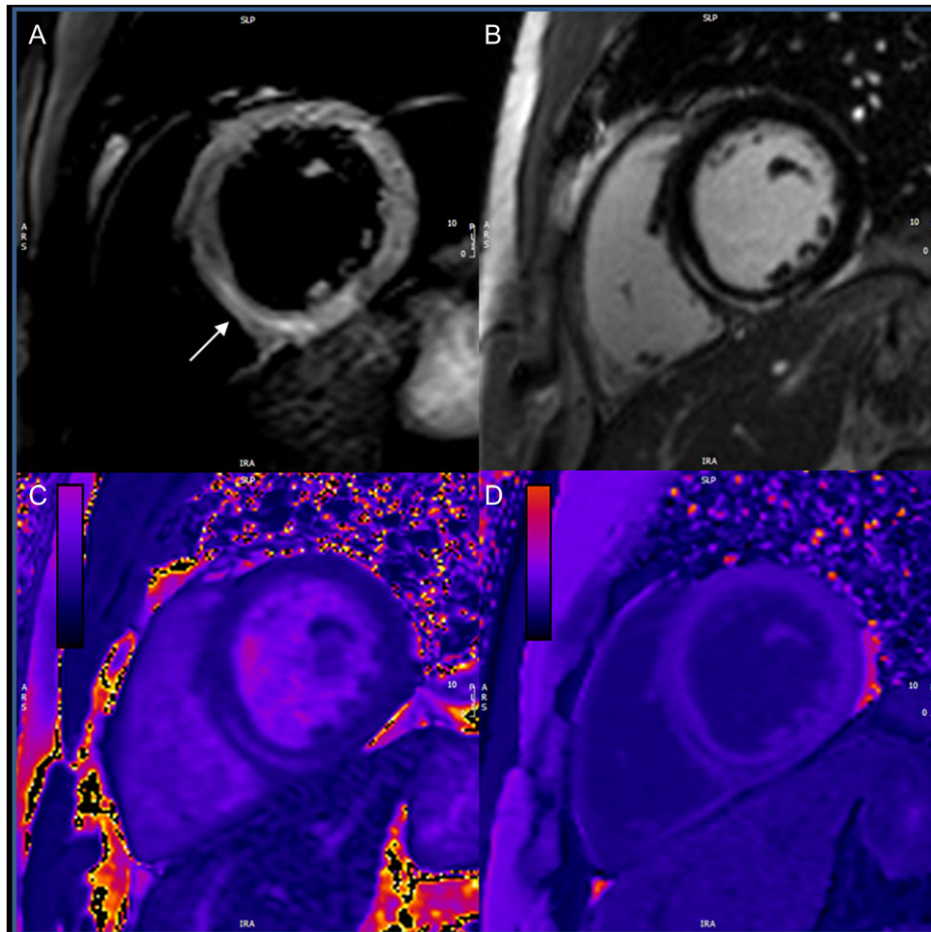
Multiple potential mechanisms have been proposed for clozapine-induced myocarditis [5]. Hypersensitivity eosinophilic myocarditis is well documented with antibiotics (37%), central nervous system agents (21%, primarily clozapine followed by carbamazepine), vaccines (8%) and a range of other

Received: November 13, 2017. Accepted: November 17, 2017

© The Author 2018. Published by Oxford University Press. All rights reserved. For permissions, please e-mail: journals.permissions@oup.com

This is an Open Access article distributed under the terms of the Creative Commons Attribution Non-Commercial License (<http://creativecommons.org/licenses/by-nc/4.0/>), which permits non-commercial re-use, distribution, and reproduction in any medium, provided the original work is properly cited.

For commercial re-use, please contact journals.permissions@oup.com



**Figure 1:** Short axis image of the left ventricle for a patient with acute myocarditis using four different imaging sequences for detailed myocardial tissue characterization. (A) T2-STIR showing myocardial oedema in the mid-wall region of the inferoseptum (area of high signal intensity indicated by white arrow). (B) Late gadolinium enhancement showing replacement fibrosis in the same region, importantly, with absence of sub-endocardial enhancement that would suggest myocardial infarction. (C) T2 map for accurate quantification of myocardial oedema. (D) Post-contrast T1 map for diffuse interstitial fibrosis assessment.

agents in 33% [15]. An alternative mechanism may be linked to increased circulating noradrenaline levels, which may result in cardiac dysfunction [16]. This form of acute ‘catecholaminergic’ myocarditis is difficult to distinguish from Takotsubo cardiomyopathy but are still considered distinct entities [17]. However, it should be remembered that aetiology may be confounded by concomitant illicit drug use, and that both external insults may act synergistically to cause myocarditis.

Clozapine re-challenge after an episode of acute myocarditis remains an unanswered question. Given the limited alternative therapeutic options in this group of patients, further investigation may be helpful alongside approaches at more intensive monitoring when initiating clozapine therapy that may include high-sensitivity troponin assays and CMR, although understandably many physicians and psychiatrists are hesitant.

In summary, clozapine-induced myocarditis remains a rare but potentially fatal complication and this case emphasizes the need for pharmaco-vigilance, early recognition of myocarditis and the need for definitive diagnosis by endomyocardial biopsy or CMR.

## CONFLICT OF INTEREST STATEMENT

No conflicts of interest.

## FUNDING

Dr Lota is supported by BHF CRTF (FS/17/21/32712) and the Alexander Jansons Foundation; Dr Halliday is supported by BHF CRTF (FS/15/29/31492).

## REFERENCES

1. Sagar S, Liu PP, Cooper LT Jr. Myocarditis. *Lancet* 2012;**379**: 738–47.
2. Heymans S, Eriksson U, Lehtonen J, Cooper LT Jr. The quest for new approaches in myocarditis and inflammatory cardiomyopathy. *J Am Coll Cardiol* 2016;**68**:2348–64.
3. Vos T, Barber RM, Bell B, Bertozzi-Villa A, Biryukov S, Bolliger I, et al. Global, regional, and national incidence, prevalence, and years lived with disability for 301 acute and chronic diseases and injuries in 188 countries, 1990–2013: a systematic analysis for the Global Burden of Disease Study 2013. *Lancet* 2015;**386**:743–800.
4. Hennen J, Baldessarini RJ. Suicidal risk during treatment with clozapine: a meta-analysis. *Schizophr Res* 2005;**73**:139–45.
5. Khan AA, Ashraf A, Baker D, Al-Omary MS, Savage L, Ekmejian A, et al. Clozapine and incidence of myocarditis and sudden death—long term Australian experience. *Int J Cardiol* 2017;**238**:136–9.

6. Haas SJ, Hill R, Krum H, Liew D, Tonkin A, Demos L, et al. Clozapine-associated myocarditis: a review of 116 cases of suspected myocarditis associated with the use of clozapine in Australia during 1993-2003. *Drug Safety* 2007;**30**: 47-57.
7. Datta T, Solomon A. Clozapine induced myocarditis. *Oxf Med Case Rep* 2017. (in press).
8. Pieroni M, Cavallaro R, Chimenti C, Smeraldi E, Frustaci A. Clozapine-induced hypersensitivity myocarditis. *Chest* 2004;**126**:1703-5.
9. Ronaldson KJ, Fitzgerald PB, Taylor AJ, Topliss DJ, McNeil JJ. A new monitoring protocol for clozapine-induced myocarditis based on an analysis of 75 cases and 94 controls. *Aust N Z J Psychiatry* 2011;**45**:458-65.
10. Lang UE, Willbring M, von Golitschek R, Schmeisser A, Matschke K, Malte Tugtekin S. Clozapine-induced myocarditis after long-term treatment: case presentation and clinical perspectives. *J Psychopharmacol* 2008;**22**:576-80.
11. Caforio AL, Pankuweit S, Arbustini E, Basso C, Gimeno-Blanes J, Felix SB, et al. Current state of knowledge on aetiology, diagnosis, management, and therapy of myocarditis: a position statement of the European Society of Cardiology Working Group on Myocardial and Pericardial Diseases. *Eur Heart J* 2013;**34**:2636-48. 2648a-2648d.
12. Friedrich MG, Sechtem U, Schulz-Menger J, Holmvang G, Alakija P, Cooper LT, et al. Cardiovascular magnetic resonance in myocarditis: a JACC White Paper. *J Am Coll Cardiol* 2009;**53**:1475-87.
13. Lurz P, Luecke C, Eitel I, Föhrenbach F, Frank C, Grothoff M, et al. Comprehensive cardiac magnetic resonance imaging in patients with suspected myocarditis: the MyoRacer-Trial. *J Am Coll Cardiol* 2016;**67**:1800-11.
14. Assomull RG, Lyne JC, Keenan N, Gulati A, Bunce NH, Davies SW, et al. The role of cardiovascular magnetic resonance in patients presenting with chest pain, raised troponin, and unobstructed coronary arteries. *Eur Heart J* 2007;**28**:1242-9.
15. Brambatti M, Matassini MV, Adler ED, Klingel K, Camici PG, Ammirati E. Eosinophilic myocarditis: characteristics, treatment, and outcomes. *J Am Coll Cardiol* 2017;**70**:2363-75.
16. Elman I, Goldstein DS, Eisenhofer G, Folio J, Malhotra AK, Adler CM, et al. Mechanism of peripheral noradrenergic stimulation by clozapine. *Neuropsychopharmacology* 1999;**20**:29-34.
17. Lyon AR, Bossone E, Schneider B, Sechtem U, Citro R, Underwood SR, et al. Current state of knowledge on Takotsubo syndrome: a position statement from the task-force on Takotsubo Syndrome of the Heart Failure Association of the European Society of Cardiology. *Eur J Heart Fail* 2016;**18**:8-27.