


## CASE REPORT

# Primary pulmonary meningioma presenting as a micro solid nodule: A rare case report

Kai-kai Xu , Feng Tian & Yong Cui

Department of Thoracic Surgery, Beijing Friendship Hospital Affiliated to Capital Medical University, Beijing, China

**Keywords**

Immunohistochemistry; lung micro nodule; primary pulmonary meningioma.

**Correspondence**

Feng Tian, Department of Thoracic Surgery, Beijing Friendship Hospital Affiliated to Capital Medical University, 95 Yong'an Road, Beijing 100050, China.

Tel: +86 138 0102 7948

Fax: +86 10 6302 3261

Email: tianfeng62@aliyun.com

Received: 8 March 2018;

Accepted: 15 March 2018.

doi: 10.1111/1759-7714.12639

Thoracic Cancer 9 (2018) 874–876

**Abstract**

An ectopic meningioma, such as a primary pulmonary meningioma (PPM), is a rare type of tumor that primarily originates outside of the central nervous system. A 65-year-old female patient underwent a thoracoscopic lung wedge resection of the right lower lobe for a micro solid nodule detected via computed tomography. The histologic result revealed a PPM. PPMs manifested with micro solid nodules are a very rare occurrence in clinical practice. Increased awareness of the clinical and pathological characteristics of this rare disease can assist thoracic surgical teams to apply adequate management.

**Introduction**

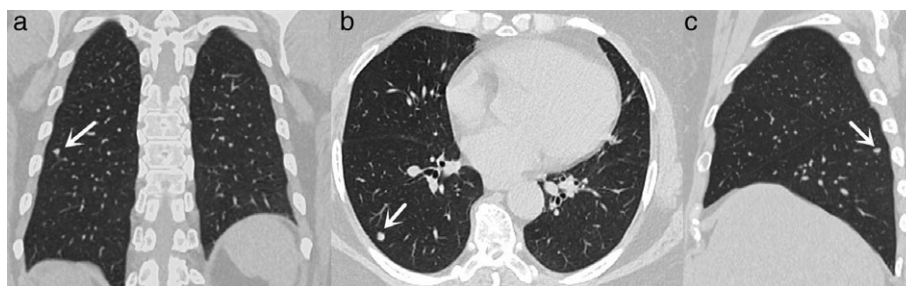
Meningioma is the most common primary intracranial tumor worldwide, accounting for approximately 15–20% of all primary central nervous system (CNS) tumors. An ectopic meningioma, such as a primary pulmonary meningioma (PPM), is a rare type of tumor that primarily originates outside of the CNS, that is, in the head and neck, skin, and peripheral nerves, and accounts for approximately 2% of all meningiomas.<sup>1</sup> Kemnitz *et al.* first identified the PPM in 1982, at which time only a few cases had been reported worldwide.<sup>2</sup> Few previous studies have reported the clinical features of PPM, which has led to the low diagnostic rate of early PPM. Rates of misdiagnosis and missed diagnosis are relatively high in clinical practice. PPM manifested with micro solid nodules is a very rare occurrence in clinical practice. Recently, a patient with PPM and micro solid nodules was diagnosed and treated at our medical center. This paper describes this rare form of PPM through a case report and literature review.

**Case report**

A 65-year-old female patient presented at our medical center complaining of right chest pain and tightness for more than a month. Thoracic computed tomography (CT) examination revealed a small nodule with high density and clear boundaries in the right lower lobe of the basal segment near the subpleural region. The diameter of the nodule was approximately 0.6 cm (Fig 1), and the boundaries with the adjacent pleura were clear. The patient had no history of chronic disease, malignant tumor, smoking, tuberculosis, or cancer in the family. Furthermore, no intraparenchymal abnormalities were detected on enhanced cranial magnetic resonance imaging (MRI). After excluding the surgical contraindications and perfecting the preoperative preparation, thoracoscopic wedge resection was performed. The patient recovered fully after surgery.

One piece of lung tissue (approx. 6 × 3 × 3 cm) was excised from the lower lobe of the right lung. A black, carbon, sediment-like nodule with a diameter of approximately

**Figure 1** Computed tomography images of micro nodule in the right lower lobe: (a) coronal plane, (b) cross plane, and (c) sagittal plane.



0.7 cm was found on the section. The texture of the nodule was firm and without boundaries.

Inflammatory cell infiltration, hyperplasia of the fibrous tissue with carbon deposition, and nodular hyperplasia (approximately 1 mm in diameter) of small oval or spindle cells were observed within the lesion. The cell atypia was not obvious, and the nodules had nest-shape distribution. Morphological and immunohistochemical data confirmed a pulmonary ectopic meningioma. The immunohistochemistry results were: epithelial membrane antigen (EMA) (+), vimentin (+), CD56 (weak +), progesterone receptor (+), Syn (-), CgA (-), Ki67 (+) 5%, actin (-), TTF-1 (-), CK (-), CK7 (-), CD31 (-), CD34 (-), CD68 (-), desmin (-), and S-100 (-) (Fig 2).

## Discussion

Reports of meningiomas that primarily originate outside the CNS are very rare. Thus far these meningiomas have been detected in following sites: intra-orbital, scalp and subcutaneous tissue, skull, nasal sinus, intraparenchymal, epidural, parotid, thorax, adrenal, and fingers.<sup>3</sup> Meningiomas that primarily originate from the lung are even more rare. Since the first report by Kemnitz in 1982 only 40 such cases have been reported worldwide.<sup>4</sup>

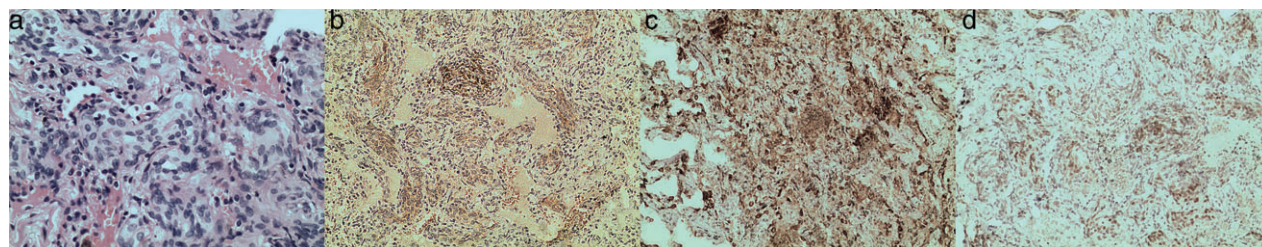
The origin of PPM remains unclear. It has been reported to originate from ectopic embryonic residual arachnoid or multifunctional mesenchymal cells.<sup>5</sup> Some authors have suggested that PPM may originate from minute meningotheial-like nodules in the lungs.<sup>6</sup> This lesion has been listed in the World Health Organization histological classification of lung and pleural tumors since 1999; however, its precise origin remains unknown. Spinelli *et al.*

reported a case in which a pulmonary ectopic meningioma coexisted with micro meningeal epithelial nodules, which suggested that pulmonary meningiomas occur in pulmonary micro membranous epithelial nodules.<sup>7</sup>

Gomezaracil *et al.* supported this corollary with histopathological, immunohistochemical, and ultrastructural analysis.<sup>8</sup> However, other authors have argued that this was inconsistent with the incidence of meningeal epithelial nodules and meningioma in autopsy results.<sup>9,10</sup> Thus, the origin of PPM remains unclear.

Primary pulmonary meningioma is a rare disease that is usually asymptomatic and primarily occurs in 40–60 year old patients. Nevertheless, patients with larger tumors may experience chest pain and other symptoms.<sup>4</sup> In the vast majority of patients, pulmonary masses and nodules are detected during physical examination. X-rays and CT scans usually reveal round or oval solitary nodules or mass shadows of different size, uniform density, smooth boundaries, and a clear outline.<sup>11</sup> Lobulation, spiculation and pleural indentation are not symptoms of PPM. In many cases, an enhanced CT scan shows a mass with different degrees of non-uniform enhancement, distinguished from uniform and apparent enhancement in an intracranial meningioma.<sup>11</sup> Pathological identification is necessary for a final diagnosis of PPM.

Pathologically, PPMs are divided into epithelial, transitional, and fibrous types, most of which are transitional. The fibrous type rarely occurs, but the epithelial type is most rare. In our case, histological morphology showed a typical CNS meningioma-like structure with fusiform cells in nest or whirlpool-like arrangements. Also, a gravel-like structure was visible, consistent with a previous report.<sup>4</sup>



**Figure 2** Hematoxylin and eosin (H&E) and immunohistochemical staining images: (a) H&E staining, (b) CD56 (+), (c) epithelial membrane antigen (+), and (d) progesterone receptor (+).

Vimentin and EMA are simultaneously expressed in the majority of patients. CD34 foci are positive in individual cases, while keratin, CK, and S-100 proteins are negative.<sup>12</sup>

Because PPM boundaries tend to be well defined, this significantly facilitates resection, thus surgical resection is the main strategy used to treat PPM. Lung wedge resection is generally selected for benign PPM, while pulmonary lobectomy should be performed with caution. With progress in thoracoscopy, thoracoscopic lung wedge resection has become the first-line surgical treatment for PPM.

The prognosis of benign PPM resection is good, with almost no recurrence or metastasis. There have been many reported cases with follow-up longer than 20 years.<sup>13</sup> However, there are also reports of malignant PPMs. Prayson *et al.* reported a rare, very aggressive case of PPM.<sup>14</sup> Ipsilateral lobe metastases were detected in a patient six months after surgery. Recurrence was observed again in the liver and chest wall four months after a second resection, suggesting a relatively high degree of malignancy.

Overall, PPM is a clinically rare disease that is benign in most cases. Nonetheless, cases of malignant PPM have also been reported. In clinical work, PPM should be considered in the differential diagnosis of pulmonary lesions. Particular attention should be paid during diagnosis and treatment to micro solid nodules, which are commonly observed in clinical practice but often ignored.

## Disclosure

No authors report any conflict of interest.

## References

- Muzumdar DP, Vengsarkar US, Bhatjiwale MG, Goel A. Diffuse calvarial meningioma: A case report. *J Postgrad Med* 2001; **47**: 116–8.
- Kemnitz P, Spormann H, Heinrich P. Meningioma of lung: First report with light and electron microscopic findings. *Ultrastruct Pathol* 1982; **3**: 359–65.
- Liu YG, Mao YQ, Zhu SG *et al.* [Clinical characteristics and treatment of ectopic meningioma.]. *Chin J Surg* 2010; **48**: 235–6 (In Chinese).
- Huang S, Chen L, Mao Y, Tong H. Primary pulmonary meningioma: A case report. *Medicine (Baltimore)* 2017; **96**: e6474.
- Chumas JC, Lorelle CA. Pulmonary meningioma. A light- and electron-microscopic study. *Am J Surg Pathol* 1982; **6**: 795–801.
- Masago K, Hosada W, Sasaki E *et al.* Is primary pulmonary meningioma a giant form of a meningothelial-like nodule? A case report and review of the literature. *Case Rep Oncol* 2012; **5**: 471–8.
- Spinelli M, Claren R, Colombi R, Sironi M. Primary pulmonary meningioma may arise from meningothelial-like nodules. *Adv Clin Path* 2000; **4**: 35–9.
- Gomez-Aracil V, Mayayo E, Alvira R, Arraiza A, Ramón y Cajal S. Fine needle aspiration cytology of primary pulmonary meningioma associated with minute meningotheliallike nodules. Report of a case with histologic, immunohistochemical and ultrastructural studies. *Acta Cytol* 2002; **46**: 899–903.
- Drlicek M, Grisold W, Lorber J, Hackl H, Wuketich S, Jellinger K. Pulmonary meningioma. Immunohistochemical and ultrastructural features. *Am J Surg Pathol* 1991; **15**: 455–9.
- Marchevsky AM. Lung tumors derived from ectopic tissues. *Semin Diagn Pathol* 1995; **12**: 172–84.
- Oide T, Hiroshima K, Shibuya K, Nakatani Y. Primary pulmonary meningioma presenting as a coin lesion. *Intern Med* 2017; **56**: 2073–4.
- Zhang WQ, Chen P, Kong X, Yang LK, Li FK, Huang ZS. [A case report of double pulmonary multiple primary meningioma and literature review.]. *J Zhengzhou Univ* 2016; **51**: 433–6 (In Chinese).
- Satoh Y, Ishikawa Y. Multiple primary pulmonary meningiomas: 20-year follow-up findings for a first reported case confirming a benign biological nature. *Int J Surg Case Rep* 2017; **31**: 58–60.
- Prayson RA, Farver CF. Primary pulmonary malignant meningioma. *Am J Surg Pathol* 1999; **23**: 722–6.