

Analysis of calpain-3 protein in muscle biopsies of different muscular dystrophies from India

R. Renjini, N. Gayathri*, A. Nalini** & M.M. Srinivas Bharath

*Departments of Neurochemistry, *Neuropathology & **Neurology, National Institute of Mental Health & Neuro Sciences, Bangalore, India*

Received October 13, 2010

Background & objectives: Calpain-3, a Ca²⁺-dependent protease has been implicated in the pathology of neuromuscular disorders (NMDs). The current study aimed to analyze calpain-3 expression in cases diagnosed as muscular dystrophy from the Indian population.

Methods: Calpain-3 Western blot analysis in muscle biopsies of immunohistochemically confirmed cases of Duchenne muscular dystrophy (DMD) (n=10), dysferlinopathy (n=30) and sarcoglycanopathy (n=8) was carried out. Calpain-3 Western blotting was also used in a blinded study to identify cases of calpain-3 deficiency in 28 NMD patients with potential muscular dystrophy.

Results: Calpain-3 appeared as a full length 94 kDa band with an autolytic product (~60 kDa) on Western blots with antibody NCL-CALP-12A2 (Ab-2). Eight of the 10 DMD samples showed absence of 94 kDa band but presence of 60 kDa band while one case of sarcoglycanopathy showed absence of both. Twenty one of the 30 dysferlinopathy samples showed both bands while six showed only the 60 kDa band and three showed absence of both. In the blinded study, five NMD cases with potential muscular dystrophy that showed complete absence of both bands in retrospect exhibited clinical features of limb girdle muscular dystrophy 2A (LGMD2A).

Interpretation & conclusions: While the study revealed a consistent pattern of calpain-3 in DMD, one sarcoglycanopathy and three dysferlinopathy samples exhibited secondary reduction in calpain-3. It was recognized that both calpain-3 bands should be considered to confirm calpain deficiency. Further, western blot offers an economical and fast preliminary screening method for LGMD2A especially in cases of complete absence of calpain-3 prior to conclusive diagnosis by genetic testing.

Key words Calpain - limb girdle muscular dystrophy - muscular dystrophy - neuromuscular disorders - western blot

Calpains are Ca²⁺-dependent cysteine proteases that modulate the activities of various intracellular proteins and enzymes¹. Among the various isoforms, calpain-3 (p94) isoform is specifically expressed in the skeletal muscle². It has been established that a functional calpain-3 is mandatory for the structural organization,

maintenance and turnover of sarcomere³. Calpain-3 interacts with several cytoskeletal proteins, regulates intracellular signal transduction and is critical for the functioning of skeletal muscle^{4,5}. Loss of calpain-3 is linked to pathological conditions such as muscular atrophy and dystrophy^{6,7}. Recessive mutations in

calpain-3 causing defective protease activity results in limb girdle muscular dystrophy-2A (LGMD2A) or calpainopathy⁸. Interestingly, secondary calpain-3 deficiency is seen in other muscular dystrophies independent of genetic mutations^{9,10}. Conversely, a normal calpain-3 profile is observed in a few genetically confirmed LGMD2A cases^{11,12}. Hence, the role of calpain-3 in muscular dystrophy is not fully understood.

Due to the absence of defined mutational hot spots and presence of mutations in more than one gene, genetic analysis of calpain-3 is not straightforward^{8,13}. Although histology and immunohistochemistry are dependable^{13,14}, Western blot is considered as the easiest method for calpain-3 analysis¹⁵. Although autolytic activity of calpain-3 could also be used to analyze its status, the absence or reduction of the autocatalytic product on Western blots is the main indicator of calpain-3 deficiency^{11,13,16}.

In this study, calpain-3 profile was compared in muscle biopsies from immunohistochemically confirmed cases of Duchenne muscular dystrophy (DMD), sarcoglycanopathy and dysferlinopathy from a tertiary referral centre for neuromuscular disorders in India. Calpain-3 profile was also analyzed in a blinded study to screen for potential LGMD2A samples from cases of neuromuscular disorders (NMDs) with potential muscular dystrophy.

Material & Methods

Bulk chemicals were obtained from Merck & Co. Inc (Whitehouse Station, NJ, USA); anti-calpain-3 antibodies from Novocastra Laboratories (Newcastle upon Tyne, UK); nitrocellulose membrane from Millipore (Billerica, MA, USA); secondary antibodies from Bangalore Genei (Bangalore, Karnataka, India) were obtained.

Patients (n=82; M: F= 55: 27; age ranging from 13 months to 63 yr) with muscle diseases were evaluated at the Neuromuscular Disorders clinic of the National Institute of Mental Health and Neurosciences, Bangalore, India, during 2006-2009 and selected non-consecutively, subject to availability following preliminary diagnostic procedures. Skeletal muscle biopsies performed after obtaining informed consent were submitted for routine diagnosis to the department of Neuropathology, NIMHANS. Eighty three muscle samples including spinal muscular atrophy (SMA) (n=2), mitochondrial myopathy (n=2), suspected

progressive myoclonic epilepsy (PME) (n=1), vasculitis (n=1), normal human autopsy sample (n=1) and immunohistochemically confirmed cases of DMD (n=10), dysferlinopathy (n=30), sarcoglycanopathies (n=8) were analyzed. The remaining 28 were blinded NMD samples with potential muscular dystrophy, which were found to be positive for the muscle proteins dystrophin, dysferlin, merosin, β dystroglycan and sarcoglycans (α , β , γ and δ) as confirmed by routine immunohistochemistry (IHC). The study protocol was approved by the Institutional Scientific Ethics Committee. Detailed clinical histories of all patients were recorded. The biopsy was conducted by a neurologist, under local anaesthesia for adults and under general anaesthesia for infants/young children. A moderately weak muscle (biceps or vastus lateralis) free from previous trauma was selected for uniformity. Fresh biopsy samples thus obtained were snap-frozen in isopentane precooled in liquid nitrogen and stored at -80°C . Autopsy muscle sample of one healthy subject who died due to non-neuromuscular disease was obtained and stored at -80°C until analysis.

The diagnosis of LGMD was based on clinical profile, family history, muscle biopsy studies, elevated serum creatine kinase (CK) levels and electromyography, according to the criteria described earlier¹⁷.

Preparation of protein extracts, SDS PAGE and Western blot: Total muscle proteins were extracted as described earlier¹⁸. Frozen muscle tissue (20 mg) was minced in 20 volumes of extraction buffer (75 mM Tris-HCl, pH 6.8, 15% SDS, 20% glycerol, 5% dithiothreitol and 0.001% bromophenol blue), sonicated for 30 sec (6 X 5 sec), boiled at 95°C for 5 min and centrifuged at 15000 g (5 min); 10 μl of the solubilized proteins in the supernatant was subjected to 10 per cent SDS-PAGE and the gels were subjected to calpain-3 Western blotting using monoclonal antibodies (NCL-CALP-2C4 or Ab-1, NCL-CALP-12A2 or Ab-2 and NCL-CALP-11B3 or Ab-3)¹⁸. For myosin profile (loading control), protein extracts were run on 6 per cent SDS-PAGE and stained with coomassie brilliant blue. To avoid artifactual protein degradation which might reduce calpain-3 signal, precaution was taken to preserve the integrity of the biopsies and to maintain optimal protein loading and gel transfer conditions.

Semi-quantitative analysis of calpain-3 Western blots: Semi-quantitative analysis of calpain-3 expression in

the blinded samples of NMD with potential dystrophy was carried out as described earlier¹³. The calpain-3 bands (94 and 60 kDa) on Western blots were scored as stronger than normal (5), normal (4), slightly reduced (3), reduced (2), markedly reduced (1) or absent (0) compared with positive control as calpain-3/ myosin ratio using the myosin band from the same patient (internal control). Samples with score "0" for both calpain-3 bands were repeated and considered as calpain-3 negative.

Histological and immunohistochemical analysis: A portion of the skeletal muscle biopsy oriented transversely was flash frozen in isopentane pre-cooled in liquid nitrogen; 8 μ thick serial cryosections were subjected to routine staining [haematoxylin-eosin (HE), modified gomori trichrome (MGT), succinic dehydrogenase (SDH), nicotinamide adenine dinucleotide tetrazolium reductase (NADH-TR), adenosine tri phosphate (ATPase) pH 9.5, 4.6 and acid phosphatase]. Immunostaining to monoclonal antibodies against dystrophin (1,2,3), sarcoglycans (α , β , γ , δ), dysferlin, β -dystroglycan and merosin as primary and HRP tagged goat anti-mouse as secondary antibodies were carried out.

Results

Three monoclonal calpain-3 antibodies were used on muscle biopsies from PME (non-dystrophic control). Ab-1 detected only the 94 kDa band (full-length calpain-3) with a faint 30 kDa autocatalytic product (Fig. 1A). Ab-2 detected both the 94 kDa band and the autocatalytic band appearing as a doublet at ~60 kDa (Fig. 1B). Ab-3 detected not only the 94 kDa and the 60 kDa autocatalytic doublet bands but also the μ and m-calpains around 85 kDa (Fig. 1C). Since the presence of autocatalytic 60 kDa band (irrespective of the 94 and 30 kDa bands) is considered as a marker of active calpain-3¹³, Ab-2 was selected to analyze all the biopsies. In the normal sample, only 60 kDa bands were visible possibly due to the long post-mortem interval and consequent artifactual degradation (Fig. 1D).

Calpain-3 pattern in muscular dystrophies: Calpain-3 Western blots using Ab-2 in biopsies of vasculitis, SMA and mitochondrial myopathy displayed both the 94 and 60 kDa bands (Fig. 2A). However, SMA (2 cases; lanes 3 and 5) comparatively showed low levels of 94 kDa band indicating higher autolytic activity of calpain-3.

Eight of the 10 DMD samples showed marked reduction or absence of the 94 kDa band but positive 60 kDa band (Fig. 2B, lanes 1, 4, 5 and 6-10) indicating higher calpain-3 activity. Twenty one of the 30 dysferlinopathy samples showed both calpain-3 bands while six showed only the 60 kDa product and three showed complete absence of both bands. Fig. 2C shows 13 such samples of which 9 samples exhibited both species (lanes 1, 2 and 5-8, 9, 11 and 13), two exhibited only the 60 kDa product (lanes 3 and 4). However, two exhibited absence of both bands (lanes 10 and 12, Fig. 2C) which might represent secondary reduction in calpain-3 downstream of dysferlin loss. Among the sarcoglycanopathies, one case (No. 4) showed complete absence of calpain-3 bands (Fig. 2D, lane 4) while other samples exhibited normal pattern.

Western based detection of calpain-3 deficiency in blinded samples: Calpain-3 Western blotting was carried out on the 28 cases of NMDs with potential muscular dystrophy where the researcher was blinded to the identity of the samples (Fig. 3). Twenty eight cases (Male : Female = 14:14), biopsied at age ranging from 2-63 yr had age at onset ranging from 6 months to 14 yr. Their clinical diagnoses were LGMD (n=18), congenital muscular dystrophy (CMD, n=2), distal myopathy with rimmed vacuoles (DMRV, n=3), DMD (n=1) and spinal muscular atrophy (SMA, n=5). Histologically, majority (n=21) were diagnosed to have LGMD, while CMD (n=4), DMRV (n=2) and SMA (n=1) constituted the rest. Immunohistochemically, preserved labelling to dystrophin, sarcoglycans (α , β , γ , δ), β dystroglycan, merosin and dysferlin was noted in all cases.

The Western data of the 28 cases revealed 23 cases with preserved 60 kDa product and 20 of these 23 cases exhibited the 94 kDa band. We found heterogeneity in the calpain-3 pattern and the relative abundance of 94 and 60 kDa bands suggesting that direct association with the disease condition and severity would be difficult. However, based on the semi-quantitative analysis of the calpain-3/ myosin ratio, complete absence of all calpain-3 bands (score 0,0) was noted in five cases (case nos. 1, 2, 3, 4 and 5 in the Table), which could be potential cases of LGMD2A. There were four samples with score (0,1) with markedly reduced calpain-3 expression. Interestingly, none of the samples showed presence of only 94 kDa with the absence of the 60 kDa band. On the contrary, there were samples (lanes

Table. Salient features of cases (n=9) with calpain-3 deficiency as per the Western blot analysis

Case no.	Age (yr)/sex	Age at onset (yr)	Family members similarly affected	Salient clinical features	CPK IU/l	EMG	Clinical diagnosis	Histopath diagnosis	Western diagnosis
1	25/M	19	NA	Progressive proximal muscle weakness of lower limbs, bilateral calf muscle hypertrophy.	3328	Myo	LGMD	LGMD	Calpainopathy
2	24/M	22	Mother	Difficulty in climbing stairs, getting up from sitting and squatting, exaggerated lumbar lordosis, proximal muscle weakness, extensor digitorum brevis bilateral hypertrophy.	NA	NA	AR-LGMD	LGMD	Calpainopathy
3	14/M	11	Twin	Difficulty in walking and getting up from sitting position, Gower's sign positive, tip-toe walking present.	8392	Myo	LGMD	LGMD	Calpainopathy
4	15/M	12	NA	Difficulty getting up from squatting position, wasting of pectoralis, supra- and infra-spinatis, winging of scapula, bilateral ankle, hip and hamstring contractures, waddling gait, Gower's sign positive, bilateral tip-toe walking present. Born of second degree consanguineous marriage.	5228	Myo	AR-LGMD	LGMD	Calpainopathy
5	31/F	27	First cousin	Difficulty in getting up from floor and squatting, climbing stairs, waddling gait, exaggerated lumbar lordosis. Born of first degree consanguineous marriage.	4100	Myo	LGMD	LGMD	Calpainopathy
6	20/M	11	Elder two sisters	Proximal muscle weakness, bilateral lower limb, contractures of elbow, hip and angle. Hypertrophy of triceps and extensor digitorum brevis. Waddling gait, lumbar lordosis, Gower's sign positive, tip-toe walking present. Born of first degree consanguineous marriage.	2562	Myo	Congenital muscular dystrophy	Muscular dystrophy with beta-sarcoglycan deficiency	Calpain deficiency- Probably secondary
7	36/M	21	2 younger siblings	Progressive proximal muscle weakness, bilateral upper and lower limbs, unable to rise without support, exaggerated lumbar lordosis, waddling gait, foot drop, wasting of proximal > distal muscles, weakness of hand grip. Born of first degree consanguineous marriage.	2856	NA	Dysferlinopathy	LGMD	Calpain deficiency- Probably secondary

Contd....

Case no.	Age (yr)/sex	Age at onset (yr)	Family members similarly affected	Salient clinical features	CPK IU/l	EMG	Clinical diagnosis	Histopath diagnosis	Western diagnosis
8	35/M	32.5	NA	Weakness of lower limbs, proximal muscle weakness, difficulty to stand on toes, marked wasting of bilateral calves, biceps and arm flexors. Born of second degree consanguineous marriage.	10000	Myo	Miyoshi myopathy	LGMD	Calpain deficiency-Probably secondary
9	30/M	28	Elder brother	Difficulty in walking, climbing stairs, weakness of all four limbs, gradually progressive, buckling of knees, frequent falls, scoliosis present, bilateral foot drop, high steppage gait.	9122	Myo	Dysferlinopathy	LGMD	Calpain deficiency-Probably secondary

AR, autosomal recessive; CPK, creatine phospho kinase; EMG, electromyography; F, female; Histopath, histopathology; LGMD, limb girdle muscular dystrophy; M, male; Myo, myopathic; NA, not available

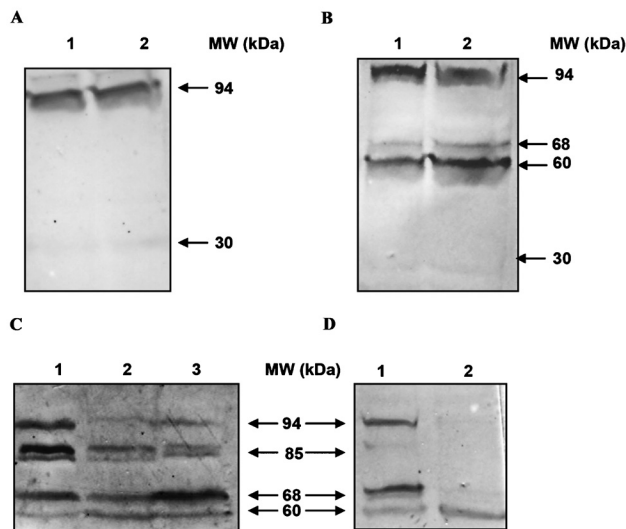


Fig. 1. Characterization of the monoclonal antibodies used in the study. Western blot using 3 monoclonal antibodies against calpain-3 in muscle biopsies are shown. (A) Western blot with Ab-1 [lanes 1 & 2 correspond respectively to 10 & 20 μ l of muscle extract from the positive control (PME)]. (B) western blot with Ab-2 [lanes 1 & 2 correspond respectively to 10 & 20 μ l of muscle extract from PME]. (C) western blot with Ab-3 (Lanes 1-3 correspond 10 μ l each of the total extract from 3 dystrophic muscle samples, respectively). (D) Western blot with Ab-2 (lanes 1 & 2 correspond to 10 μ l each of the total extract from PME and normal autopsy muscle respectively). The protein molecular weights (MW) in kDa in each blot are shown.

1 & 5 in Fig. 3A) which showed marked reduction or absence of the 94 kDa and reduced 60 kDa band.

Histopathology and clinical evaluation of selected calpain-3 deficient cases: Following Western blotting, only the cases with (0,0) score as analysed by semiquantitative analysis of calpain-3 were analyzed further. Accordingly, five cases with primary calpain-3 deficiency were selected from the blinded study (cases 1-5 in the Table) for review of the stained sections of muscle biopsies. Dystrophic features were noted in all cases with presence of atrophic angulated fibers with clumped nuclei and a few muscle giant cells in one of the cases. In addition, inflammatory infiltrates in the interstitium and perivascular region comprising lymphocytes and eosinophils were noted in all (representative Fig. 4A and 4B, case 3 in the Table, corresponding to lane 1 of Fig. 3C). There was no evidence of lobulated fibers on SDH and NADH-Tr. Mosaic pattern was seen on ATPase reaction. Immunostaining with monoclonal antibodies against dystrophin (DYS 1, 2 3), sarcoglycans (α , β , γ , δ), dysferlin, β dystroglycan and merosin showed uniform intense labelling along the membrane in all the fibers suggesting that these five biopsies did not represent DMD/BMD or sarcoglycanopathy or dysferlinopathy (Fig. 4 C-K).

A detailed follow up of the patients confirmed that these cases indeed exhibited all the classical features

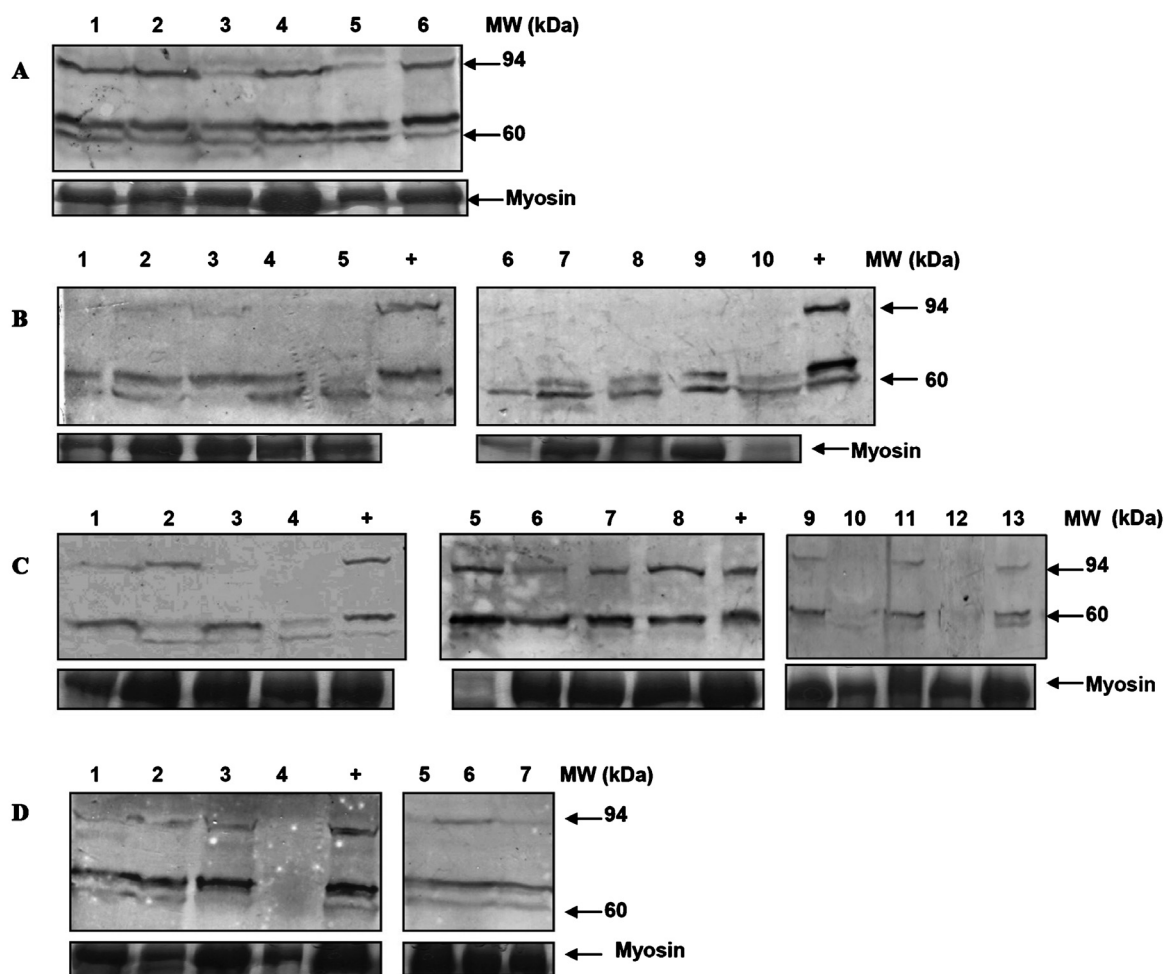


Fig. 2. Western blot analysis with Ab-2 to investigate the status of calpain-3 in different muscle biopsies including muscular dystrophies. **(A)** calpain-3 profile in PME (lane 1), vasculitis (lane 2), SMA (lanes 3 & 5), and mitochondrial myopathy (lanes 4 & 6) are shown. **(B)** calpain-3 profile in DMD muscle biopsies (lanes 1-5 & 6-10) compared with positive control (PME) (+) is shown. **(C)** calpain-3 profile in dysferlinopathy muscle biopsies (lanes 1-4, 5-8 & 9-13) compared with positive control (PME) (+) is shown. **(D)** calpain-3 profile in sarcoglycanopathy muscle biopsies (lanes 1-4 & 5-7) compared with positive control (PME) (+) is shown. The corresponding myosin band in each sample is indicated below the blot.

of LGMD2A. Among the five cases (four men and one woman), the mean age at presentation was 21.5 ± 6.47 yr (range: 14-31 yr), mean age at onset was 16.83 ± 6.68 yr (11-27 yr) and mean duration of illness was 4.5 ± 2.6 yr (2-9 yr). Three patients (with ages at onset 11, 11 and 12 yr, respectively) presented with classical scapulo-humeral phenotype, multiple contractures and tip-toe walking. The remaining three patients presented with pelvo-femoral phenotype with weakness in limb girdle distribution with age at onset as 18, 22 and 27 yr. Contractures were not prominent. This group had a later age at onset as compared to scapulo-humeral form. The mean CK value was 3574.33 ± 2924.1 IU/l (range 511-8392 IU/l).

Discussion

In this study, we compared the calpain-3 protein profile across muscular dystrophy samples from India. In calpain-3 Western blots, all the bands must be considered in the context of other muscle proteins and optimal tissue preservation instead of determining the abnormal levels of the full length protein only¹³. We found a typical pattern for calpain-3 with a full length protein (94 kDa) and an autolytic product (60 kDa). But the identity of the proteolytic product is unknown. We did not find a prominent 30 kDa band in our blots probably due to limited sensitivity or degradation specific to our samples. We considered only the complete absence of the 60 and 94 kDa bands rather

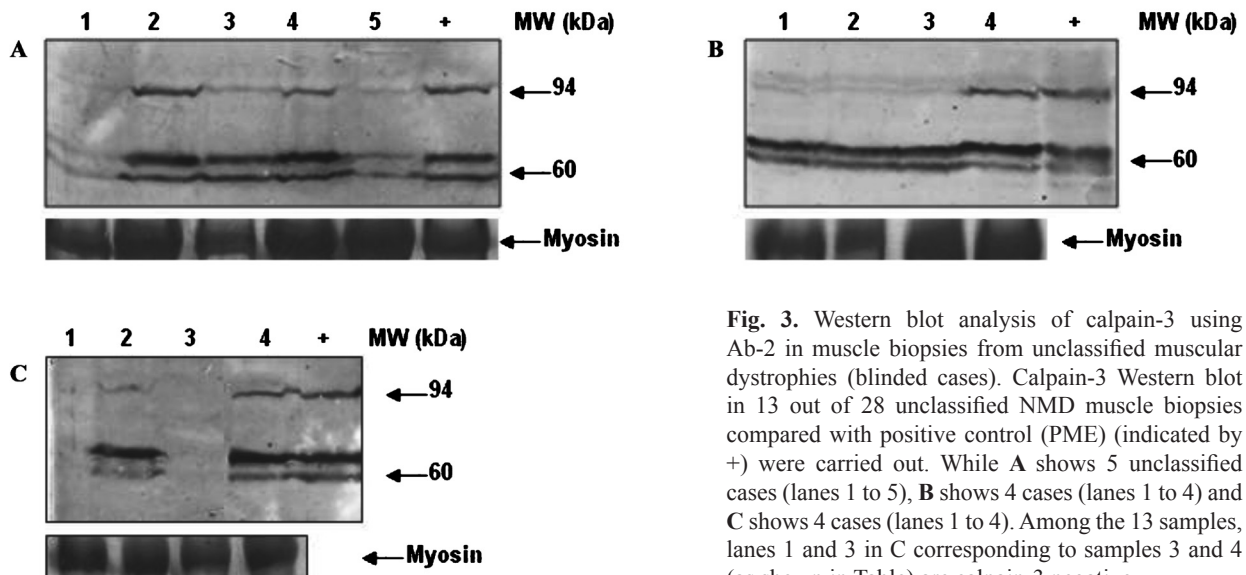


Fig. 3. Western blot analysis of calpain-3 using Ab-2 in muscle biopsies from unclassified muscular dystrophies (blinded cases). Calpain-3 Western blot in 13 out of 28 unclassified NMD muscle biopsies compared with positive control (PME) (indicated by +) were carried out. While **A** shows 5 unclassified cases (lanes 1 to 5), **B** shows 4 cases (lanes 1 to 4) and **C** shows 4 cases (lanes 1 to 4). Among the 13 samples, lanes 1 and 3 in C corresponding to samples 3 and 4 (as shown in Table) are calpain-3 negative.

than reduced expression as an indicator of calpain-3 deficiency (LGMD2A).

In DMD, eight of the 10 biopsies showed absence of the 94 kDa band indicating increased autolytic activity²⁶. Increased calpain activity has been localized to atrophic fibers in DMD and might be important but not specific to DMD^{19,20}. Hence, calpain inhibition could be a therapeutic option in DMD²¹. The intracellular location of calpain is directly associated with its cellular role under normal physiological conditions and in DMD²². Interestingly, dystrophin is an important substrate for calpain-3²³.

The interaction between calpain-3 and dysferlin is not completely defined¹⁷. Calpain-3 probably interacts physically with dysferlin²⁴ which might reduce dysferlin membrane labelling in LGMD2A biopsies¹³. A secondary reduction in calpain-3 expression is observed in dysferlinopathy⁹. In our study, although we did not observe a significant change in calpain-3 bands in 70 per cent dysferlinopathy biopsies, consistent with the gene expression data published earlier²⁵, six cases showed absence of 94 kDa band and three showed complete absence of both bands.

If the clinical evaluation is suggestive of calpainopathy, the first step is to rule out other LGMDs by immunohistochemistry of other muscle proteins that might cause secondary reduction of calpain-3. Although this is an indirect method, it is still the best preliminary option. In this study, samples which were positive for dystrophin, dysferlin, sarcoglycans

and merosin immunolabelling were considered for calpain-3 Western blotting. We found one case of calpain-3 deficiency secondary to deficiency of β -sarcoglycan and three cases secondary to deficiency of dysferlin. However, none of the 28 blinded cases of NMDs showed any significant reduction in other muscle proteins.

Recently Pathak *et al*²⁶ reported a study based on semi-quantitative protein analysis with clinical and histopathological correlation in LGMD2A in India. According to their data based on 171 cases of clinically suspected LGMD, unclassified muscular dystrophy or myopathy, based on histopathology, immunohistochemistry and Western blots, 75 of the biopsies showed complete calpain-3 deficiency of which 45 per cent had complete loss and 39 per cent had partial loss of calpain-3 protein. In that study, the calpain-3 status was based exclusively on the full length calpain-3 band at 94 kDa. However, approaches such as ours and others²⁶ are applicable only in cases showing complete absence of calpain-3. There might be LGMD2A cases in the remaining 23 samples that went undetected due to normal calpain-3 pattern. While some mutations cause calpain-3 reduction, others may not affect protein levels but rather cause functional inactivation^{11,16,27-30}.

Hence, biopsies with normal calpain-3 on Western blot should be confirmed by a functional *in vitro* autolytic assay followed by genetic analysis²⁷⁻³⁰. Although genetic testing provides significant

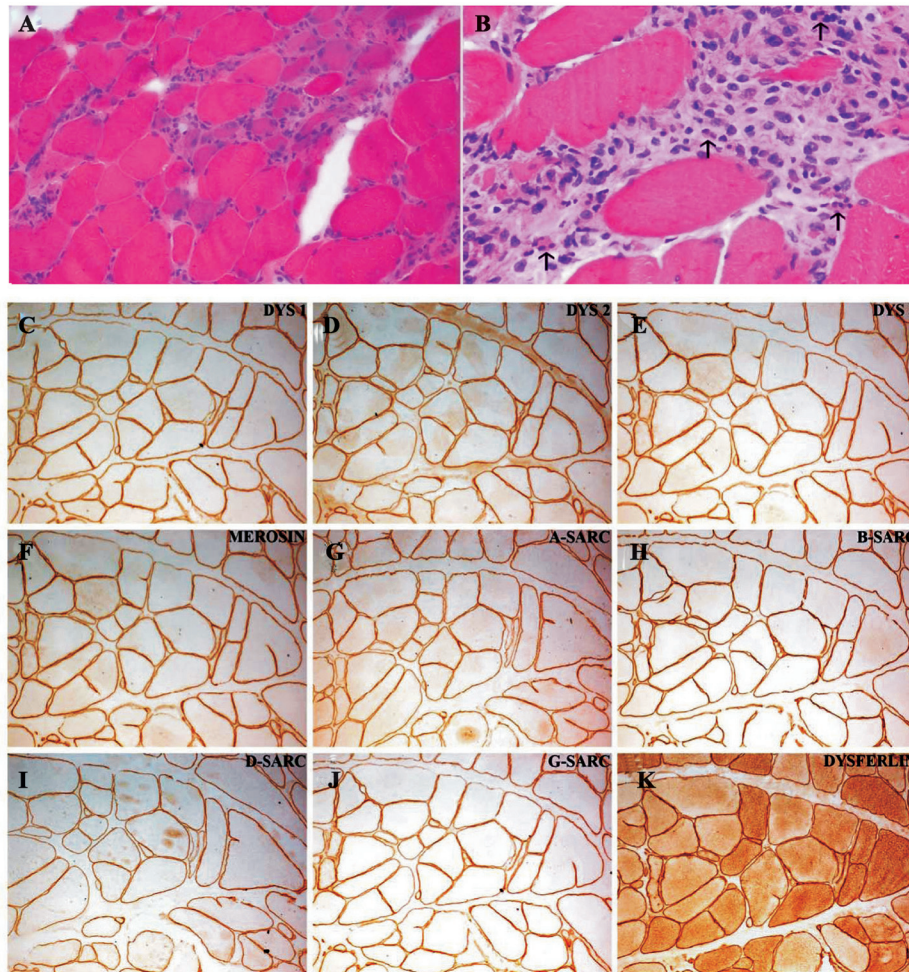


Fig. 4. Histological and immunohistochemical analysis of muscle biopsy from a representative case (case no. 3 in Table) of calpain-3 deficiency. Transverse section of skeletal muscle stained for haematoxylin-eosin shows variation in diameter, myophagocytosis and dense interstitial inflammation (**A**) X200. Note the presence of eosinophils (**↑**) (**B**) X400. Immunohistochemical staining to antibodies against dystrophin (**C**: DYS 1; **D**: DYS 2; **E**: DYS 3), Merosin (**F**), sarcoglycans (**G**: α ; **H**: β ; **I**: δ ; **J**: γ) and dysferlin (**K**) shows uniform labelling along the membrane in all the fibers X200.

information about the disease, it is not the first method of choice for diagnosis of LGMD2A, as it is expensive, labour intensive and might be ambiguous due to lack of definite mutational hotspots⁹. Therefore, Western blot based preliminary screening method can be used as the first step to quickly screen LGMD2A in a high-throughput setting in clinically suggestive cases, before conclusive diagnosis based on immunohistochemistry and molecular genetics.

Acknowledgment

This work was financially supported by the Department of Science and Technology, New Delhi, India. The first author (RR) acknowledges the Council for Scientific and Industrial Research, India, for providing the junior research fellowship. The authors thank all the patients and their families.

References

1. Goll DE, Thompson VF, Li H, Wei W, Cong J. The calpain system. *Physiol Rev* 2003; 83 : 731-801.
2. Suzuki K, Hata S, Kawabata Y, Sorimachi H. Structure, activation, and biology of calpain. *Diabetes* 2004; 53 (Suppl 1): S12-8.
3. Beckmann JS, Spencer M. Calpain 3, the “gatekeeper” of proper sarcomere assembly, turnover and maintenance. *Neuromuscul Disord* 2008; 18 : 913-21.
4. Carafoli E, Molinari M. Calpain: a protease in search of a function? *Biochem Biophys Res Commun* 1998; 247 : 193-203.
5. Kramerova I, Kudryashova E, Tidball JG, Spencer MJ. Null mutation of calpain 3 (p94) in mice causes abnormal sarcomere formation *in vivo* and *in vitro*. *Hum Mol Genet* 2004; 13 : 1373-88.

6. Jackman RW, Kandarian SC. The molecular basis of skeletal muscle atrophy. *Am J Physiol Cell Physiol* 2004; 287 : C834-43.
7. Spencer MJ, Mellgren RL. Overexpression of a calpastatin transgene in mdx muscle reduces dystrophic pathology. *Hum Mol Genet* 2002; 11 : 2645-55.
8. Richard I, Broux O, Allamand V, Fougerousse F, Chiannilkulchai N, Bourg N, *et al.* Mutations in the proteolytic-enzyme calpain-3 cause limb-girdle muscular-dystrophy type-2A. *Cell* 1995; 81 : 27-40.
9. Anderson LV, Harrison RM, Pogue R, Vafiadaki E, Pollitt C, Davison K, *et al.* Secondary reduction in calpain 3 expression in patients with limb girdle muscular dystrophy type 2B and Miyoshi myopathy (primary dysferlinopathies). *Neuromuscul Disord* 2000; 10 : 553-9.
10. Haravuori H, Vihola A, Straub V, Auranen M, Richard I, Marchand S, *et al.* Secondary calpain 3 deficiency in 2q-linked muscular dystrophy: titin is the candidate gene. *Neurology* 2001; 56 : 869-77.
11. Fanin M, Nascimbeni AC, Fulizio L, Trevisan CP, Meznaric-Petrusa M, Angelini C. Loss of calpain-3 autocatalytic activity in LGMD2A patients with normal protein expression. *Am J Pathol* 2003; 163 : 1929-36.
12. Sáenz A, Leturcq F, Cobo AM, Poza JJ, Ferrer X, Otaegui D, *et al.* LGMD2A: genotype-phenotype correlations based on a large mutational survey on the calpain 3 gene. *Brain* 2005; 128 : 732-42.
13. Groen EJ, Charlton R, Barresi R, Anderson LV, Eagle M, Hudson J, *et al.* Analysis of the UK diagnostic strategy for limb girdle muscular dystrophy 2A. *Brain* 2007; 130 : 3237-49.
14. Charlton R, Henderson M, Richards J, Hudson J, Straub V, Bushby K, *et al.* Immunohistochemical analysis of calpain 3: advantages and limitations in diagnosing LGMD2A. *Neuromuscul Disord* 2009; 19 : 449-57.
15. Anderson LV, Davison K. Multiplex western blotting system for the analysis of muscular dystrophy proteins. *Am J Pathol* 1999; 154 : 1017-22.
16. Fanin M, Nascimbeni AC, Angelini C. Screening of calpain-3 autolytic activity in LGMD muscle: a functional map of CAPN-3 gene mutations. *J Med Genet* 2007; 44 : 38-43.
17. Bushby KM, Beckmann JS. The limb-girdle muscular dystrophies - proposal for a new nomenclature. *Neuromuscul Disord* 1995; 5 : 337-43.
18. Zardini E, Franciotta D, Melzi d'Eril GV. Detection of dystrophin with a modified Western blot technique in muscle tissue extracts. *Clin Chem* 1993; 39 : 915.
19. Gailly P, De Backer F, Van Schoor M, Gillis JM. *In situ* measurements of calpain activity in isolated muscle fibres from normal and dystrophin-lacking mdx mice. *J Physiol* 2007; 582 : 1261-75.
20. Kumamoto T, Ueyama H, Watanabe S, Yoshioka K, Miike T, Goll DE, *et al.* Immunohistochemical study of calpain and its endogenous inhibitor in the skeletal muscle of muscular dystrophy. *Acta Neuropathol* 1995; 89 : 399-403.
21. Badalamente MA, Stracher A. Delay in muscle degeneration and necrosis in mdx mice by calpain inhibition. *Muscle Nerve* 2000; 23 : 106-11.
22. Spencer MJ, Tidball JG. Calpain translocation during muscle fiber necrosis and regeneration in dystrophin-deficient mice. *Exp Cell Res* 1996; 226 : 264-72.
23. Cottin P, Poussard S, Mornet D, Brustis JJ, Mohammadpour M, Leger J, *et al.* *In vitro* digestion of dystrophin by calcium-dependent proteases calpains I and II. *Biochimie* 1992; 74 : 565-70.
24. Huang Y, Verheesen P, Roussis A, Frankhuizen W, Ginjaar I, Haldane F, *et al.* Protein studies in dysferlinopathy patients using llama-derived antibody fragments selected by phage display. *Eur J Hum Genet* 2005; 13 : 721-30.
25. Campanaro S, Romualdi C, Fanin M, Celegato B, Pacchioni B, Trevisan S, *et al.* Gene expression profiling in dysferlinopathies using a dedicated muscle microarray. *Hum Mol Genet* 2002; 11 : 3283-98.
26. Pathak P, Sharma MC, Sarkar C, Jha P, Suri V, Mohd H, *et al.* Limb girdle muscular dystrophy type 2A in India: A study based on semi-quantitative protein analysis, with clinical and histopathological correlation. *Neurol India* 2010; 58 : 549-54.
27. Fanin M, Fulizio L, Nascimbeni AC, Spinazzi M, Piluso G, Ventriglia VM, *et al.* Molecular diagnosis in LGMD2A: mutation analysis or protein testing? *Hum Mutat* 2004; 24 : 52-62.
28. Fanin M, Nascimbeni AC, Fulizio L, Angelini C. The frequency of limb girdle muscular dystrophy 2A in northeastern Italy. *Neuromuscul Disord* 2005; 15 : 218-24.
29. Milic A, Daniele N, Lochmuller H, Mora M, Comi GP, Moggio M, *et al.* A third of LGMD2A biopsies have normal calpain 3 proteolytic activity as determined by an *in vitro* assay. *Neuromuscul Disord* 2007; 17 : 148-56.
30. Talim B, Ognibene A, Mattioli E, Richard I, Anderson LV, Merlini L. Normal calpain expression in genetically confirmed limb-girdle muscular dystrophy type 2A. *Neurology* 2001; 56 : 692-3.

Reprint requests: Dr M.M. Srinivas Bharath, National Institute of Mental Health & Neuro Sciences
 P.B # 2900, Hosur Road, Bangalore 560 029, India
 e-mail: bharath@nimhans.kar.nic.in