

# Vaccination-associated immune thrombocytopenia possibly due to ChAdOx1 nCoV-19 (Covishield) coronavirus vaccine

Prakash Sivaramakrishnan, Mayank Mishra 

Department of Pulmonary Medicine, All India Institute of Medical Sciences, Rishikesh, Uttarakhand, India

## Correspondence to

Dr Mayank Mishra;  
virgodrmayank@gmail.com

Accepted 11 March 2022

## SUMMARY

Immune thrombocytopenia (ITP) is an acquired haemorrhagic diathesis of immune-mediated destruction, impaired production or increased splenic sequestration of platelets. It can be idiopathic (primary) or secondary (infections, medications, HIV infection, malignancies, connective tissue diseases or rarely secondary to vaccination). ITP postvaccination is termed vaccine-associated ITP (VITP) and is known to be caused by vaccines against various infectious agents such as measles-mumps-rubella, *Haemophilus influenzae*, pneumococcus, hepatitis B virus and human papilloma virus. Cases of VITP post SARS-CoV-2 vaccination have also been reported in the literature. Various hypotheses on the occurrence of the same are theorised, but no single theory has been proven to cause VITP conclusively. Management includes routine treatment of ITP with use of agents such as steroids, intravenous immunoglobulins, or on rare occasions a thrombopoietic agent or vinca alkaloids. We present a case of VITP possibly due to ChAdOx1 nCoV-19 (Covishield) vaccination in a middle-aged woman who responded to steroid therapy.

## BACKGROUND

Immune thrombocytopenia (ITP) is an acquired haemorrhagic diathesis of immune-mediated destruction, impaired production or increased splenic sequestration of platelets. It is characterised by a platelet count of  $<100 \times 10^9/L$ . ITP is idiopathic in 80% of cases, also called primary ITP, which is often thought to be an autoimmune disorder. However, 20% of cases are usually secondary to an underlying precipitating aetiology, such as infections, medications, rheumatological disorders or malignancy.

Vaccine-associated ITP (VITP) is an uncommon but serious adverse event after vaccination with the novel coronavirus vaccines. It has also been reported following vaccination against various other infectious agents, namely measles-mumps-rubella, *Haemophilus influenzae*, pneumococcus, hepatitis B virus, human papilloma virus, varicella-zoster virus and polio virus.<sup>1</sup> Cases of VITP after SARS-CoV-2 vaccination with BNT162b2 (Pfizer-BioNTech) and Moderna COVID-19 vaccines have been reported.<sup>2,3</sup> We describe a case of VITP possibly due to ChAdOx1 nCoV-19 (Covishield) vaccination, with a review of relevant literature.

## CASE PRESENTATION

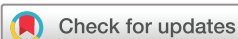A middle-aged non-smoker woman with no previous comorbidities presented with a history of haemoptysis, menorrhagia and fever 1 month after vaccination with the first dose of the Covishield vaccine received in July 2021. She had been evaluated for these complaints in the periphery, where physical examination and routine laboratory were unremarkable except for a low platelet count of  $8 \times 10^9/L$ . The patient was given a diagnosis of dengue fever and received symptomatic/supportive treatment, including four random donor platelet transfusions, and showed partial clinical improvement.

However, in view of persistent menorrhagia and streaking of sputum, the patient was referred to our centre, where thoracic imaging revealed post-infective sequelae in the left lung due to previously treated pulmonary tuberculosis and a dilated left bronchial artery on contrast tomogram thoracic aortogram. Other baseline investigations were unremarkable except for a raised total serum bilirubin of 1.3 mg/dL. Her platelet count at presentation was  $160 \times 10^9/L$  and her HIV test was negative. She was managed conservatively and was discharged following improvement a week later, with a platelet count of  $258 \times 10^9/L$ .

Following discharge, she received the second dose of the Covishield vaccine in September 2021. She again developed haemoptysis and menorrhagia 11 days after vaccination and was readmitted to our centre. Her platelet count at this time was  $10 \times 10^9/L$  and her haemoglobin was 108 g/L. Other blood parameters were within normal limits (table 1).

## TREATMENT

A haematology reference was sought and the patient was started on oral prednisolone at 80 mg/day for 2 weeks, along with supportive medications, which resulted in clinical response in terms of resolution of bleeding symptoms as well as normalisation of platelet count. However, the thrombocytopenia recurred after 1 week of steroid withdrawal (platelet count  $27 \times 10^9/L$ ). Additional anaemia and immunology work-up (antinuclear antibodies and anticyclic citrullinated peptide) was normal. Steroids were reinitiated at a dose of 60 mg/day for 2 weeks, followed by tapering by 10 mg weekly. Figure 1 illustrates the trends in platelet count with Covishield vaccination and steroid therapy.



© BMJ Publishing Group Limited 2022. No commercial re-use. See rights and permissions. Published by BMJ.

**To cite:** Sivaramakrishnan P, Mishra M. *BMJ Case Rep* 2022;**15**:e249237. doi:10.1136/bcr-2022-249237

**Table 1** Routine blood investigations at the second visit to our institute in October 2021

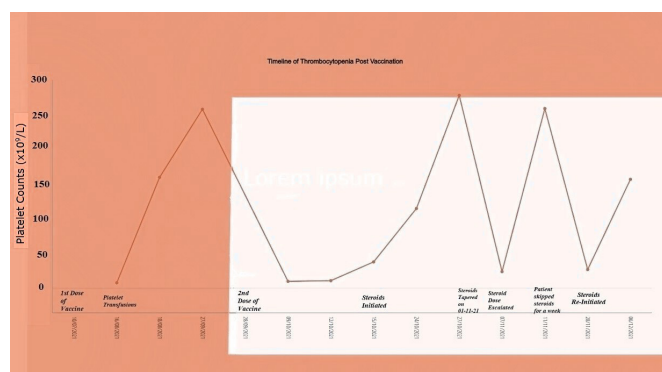
Blood test	Value
Haemoglobin (g/L)	108
Total leucocyte count ( $\times 10^9/L$ )	8.7
Platelet count ( $\times 10^9/L$ )	10
Prothrombin time/International Normalized Ratio	11.4/1.05
Blood urea/serum creatinine (mg/dL)	22.0/0.46
Serum electrolytes (mEq/L)	138/3.4/102
Serum calcium (mg/dL)	9.2
Serum phosphate level (mg/dL)	3.3
Serum Bilirubin (total) (mg/dL)	0.98
Antinuclear antibodies and anticyclic citrullinated peptide	Negative
D-dimer (mg/L)	0.21 (normal <0.5)

## OUTCOME AND FOLLOW-UP

The patient clinically responded to tapering doses of systemic steroid treatment. Her haemoptysis ceased to occur, her menorrhagia reduced and her platelet count stabilised within the normal range. She is currently doing well and on regular follow-up with clinical and blood work-up.

## DISCUSSION

VITP is a rare phenomenon postvaccination and research on its specific causation, management and outcome is lacking. Only recently, a case series based on data obtained from the Centers for Disease Control and Prevention (CDC), Food and Drug Administration (FDA) and agencies of the US Department of Health and Human Services Vaccine Adverse Event Reporting System (VAERS) was published.<sup>2,4</sup> In the case series by Lee *et al*<sup>4</sup> from VAERS data of the US FDA and CDC, all 20 patients who had ITP were investigated and they could not categorically exclude postvaccination secondary ITP from exacerbation of clinically undetected ITP. *The New York Times* reported the case of a 56-year-old physician who developed severe thrombocytopenia after receiving Pfizer's COVID-19 vaccine and eventually died due to haemorrhagic stroke.<sup>5</sup> Another report described three cases of severe VITP that occurred following COVID-19 vaccination (two received Pfizer, while one received Johnson & Johnson vaccine)<sup>6</sup> and also discussed possible treatment options for the same. A large retrospective Australian case series on ITP following AstraZeneca or Pfizer-BioNTech COVID-19 vaccination identified an increased rate of ITP after receiving the former.<sup>7</sup>



**Figure 1** Line diagram showing trends in platelet count with Covishield vaccination and steroid therapy.

Literature review of VITP following COVID-19 vaccination suggests the following hypotheses as possible pathogenetic mechanisms.<sup>2-4, 8</sup> First, treatment with antisense oligonucleotides, which are an essential component of mRNA vaccines, has been known to be associated with thrombocytopenia. However, a higher and sustained level of RNA reaching the lymph nodes would be essential to generate an immune response than is likely seen based on a single intramuscular injection.<sup>3,4</sup>

Alternatively, patients may have preformed antibodies directed against the nanoparticle layers or polyethylene glycol, both of which are components of vaccines. This theory was thought to be unlikely as it assumes that antibodies are directed against an antigen formed by attachment of vaccine particles on a small number of platelets, but ITP essentially occurs with a premise that involves 'all' platelets.<sup>4</sup>

Third theory is the possibility of a pre-existing, compensated, mild subclinical ITP or hereditary thrombocytopenia that worsens following COVID-19 vaccination. In such patients, an enhancement of macrophage-mediated clearance or impaired platelet production as part of a systemic inflammatory response to vaccination was proposed as the cause of trigger of thrombocytopenia. The literature describes a patient with borderline platelet count ( $145 \times 10^9/L$ ) 2 months prior to receipt of the vaccine which deteriorated soon after vaccination<sup>2</sup> and another patient diagnosed with chronic hereditary thrombocytopenia which had been in remission for the last 12 years but was exacerbated by COVID-19 vaccination.<sup>8</sup>

Lastly, postvaccination ITP is a distinct possibility especially in patients with bleeding symptoms or thrombocytopenia occurring 1–2 weeks after vaccination. This theory has been backed up by multiple cases that have responded well to treatment with corticosteroids with or without intravenous immunoglobulins (IVIG).<sup>4</sup> In our case, the presence of bleeding symptoms in the form of haemoptysis and menorrhagia, their occurrence within weeks of vaccination, and the subsequent clinical and haematological response to systemic steroid therapy prompted us to consider the postvaccination ITP hypothesis over others.

In all the above situations, most of the treated patients showed clinical improvement in response to standard ITP therapy with corticosteroids and IVIG, further reiterating the possibility of an antibody-mediated platelet clearance mechanism that is operative in VITP. In patients who fail to respond to standard ITP treatment, escalation of treatment to include a thrombopoietic agent and vinca alkaloids may be considered, depending on the response.<sup>4</sup> Rituximab is best avoided in the initial treatment regimen since it may take up to 6–8 weeks to produce a response and may also impair the protective effect of the COVID-19 vaccine.<sup>9</sup> One consideration could be to monitor patients with history of ITP for an antibody response after the first dose of COVID-19 vaccine and reserve the second dose for those with an inadequate antibody response.<sup>9</sup>

An important entity to be considered in such clinical scenarios is vaccine-induced immune thrombocytopenia and thrombosis (also known as thrombosis with thrombocytopenia syndrome). This rare condition has been reported with ChAdOx1 nCoV-19 vaccine, with a higher incidence in younger age group compared with older women. It is associated with elevated fibrinogen and D-dimer levels, usually requiring further thrombosis-specific work-up and imaging to facilitate its exclusion. However, we did not proceed with such investigations given our patient's normal D-dimer levels and absence of any symptoms or signs suggestive of thrombosis, such as headache, visual disturbances, abdominal pain, petechiae, etc.

To conclude, COVID-19 vaccines such as Covishield, Pfizer and Moderna are likely to have the potential to trigger de-novo ITP rarely. Extensive surveillance and meticulous reporting of adverse events are needed to determine its true incidence. Differentiation between VITP and pre-existing ITP/chronic thrombocytopenia exacerbated by vaccination is imperative and has significant implications for clinical practice. Detailed analysis and research into the possible pathogenetic mechanisms leading to VITP are required. It may be additionally worthwhile to see whether exacerbation of other conditions considered to have an autoimmune pathophysiology also occurs in relation to COVID-19 vaccination to gain a better understanding of host response to vaccination. Any patient who presents with bleeding manifestations or bruising postvaccination should be thoroughly investigated with a detailed history, physical and baseline platelet counts, and managed as per standard ITP protocol. Whether post-COVID-19 VITP cases will prove to be self-limiting or persist and lead to chronic ITP remains uncertain. Research aimed at making changes in vaccine composition to prevent thrombocytopenia would be desirable.

### Learning points

- ▶ COVID-19 vaccines such as Covishield, Pfizer and Moderna are likely to have the potential to trigger de-novo immune thrombocytopenia (ITP) rarely.
- ▶ Differentiation between vaccine-associated ITP and pre-existing ITP/chronic thrombocytopenia exacerbated by vaccination is imperative and has significant implications for clinical practice.
- ▶ Research aimed at making changes in vaccine composition to prevent thrombocytopenia would be desirable.

**Acknowledgements** We would like to acknowledge the Department of Medical Oncology-Haematology for their valuable suggestions and advice on the management of this patient.

**Contributors** PS: Acquisition of clinical details, literature search and initial manuscript draft. MM: Manuscript design, editing, review and guarantor.

**Funding** The authors have not declared a specific grant for this research from any funding agency in the public, commercial or not-for-profit sectors.

**Competing interests** None declared.

**Patient consent for publication** Obtained.

**Provenance and peer review** Not commissioned; externally peer reviewed.

Case reports provide a valuable learning resource for the scientific community and can indicate areas of interest for future research. They should not be used in isolation to guide treatment choices or public health policy.

### ORCID iD

Mayank Mishra <http://orcid.org/0000-0001-7982-6267>

### REFERENCES

- 1 David P, Shoenfeld Y. ITP following vaccination. *Int J Infect Dis* 2020;99:243–4.
- 2 Tarawneh O, Tarawneh H. Immune thrombocytopenia in a 22-year-old post Covid-19 vaccine. *Am J Hematol* 2021;96:E133–4.
- 3 Polack FP, Thomas SJ, Kitchin N, *et al*. Safety and efficacy of the BNT162b2 mRNA Covid-19 vaccine. *N Engl J Med* 2020;383:2603–15.
- 4 Lee E-J, Cines DB, Gernsheimer T, *et al*. Thrombocytopenia following Pfizer and Moderna SARS-CoV-2 vaccination. *Am J Hematol* 2021;96:534–7.
- 5 Grady D, Mazzei P. Doctor's death after Covid vaccine is being investigated, 2021. The New York Times. Available: <https://www.nytimes.com/2021/01/12/health/covid-vaccine-death.html>
- 6 Shah SRA, Dolkar S, Mathew J, *et al*. COVID-19 vaccination associated severe immune thrombocytopenia. *Exp Hematol Oncol* 2021;10:42.
- 7 Gordon SF, Clothier HJ, Morgan H, *et al*. Immune thrombocytopenia following immunisation with Vaxzevria ChadOx1-S (AstraZeneca) vaccine, Victoria, Australia. *Vaccine* 2021;39:7052–7.
- 8 Toom S, Wolf B, Avula A, *et al*. Familial thrombocytopenia flare-up following the first dose of mRNA-1273 Covid-19 vaccine. *Am J Hematol* 2021;96:E134–5.
- 9 Bonelli MM, Mrak D, Perkmann T, *et al*. SARS-CoV-2 vaccination in rituximab-treated patients: evidence for impaired humoral but inducible cellular immune response. *Ann Rheum Dis* 2021;80:1355–6.

Copyright 2022 BMJ Publishing Group. All rights reserved. For permission to reuse any of this content visit <https://www.bmj.com/company/products-services/rights-and-licensing/permissions/>  
BMJ Case Report Fellows may re-use this article for personal use and teaching without any further permission.

Become a Fellow of BMJ Case Reports today and you can:

- ▶ Submit as many cases as you like
- ▶ Enjoy fast sympathetic peer review and rapid publication of accepted articles
- ▶ Access all the published articles
- ▶ Re-use any of the published material for personal use and teaching without further permission

### Customer Service

If you have any further queries about your subscription, please contact our customer services team on +44 (0) 207111 1105 or via email at [support@bmj.com](mailto:support@bmj.com).

Visit [casereports.bmj.com](http://casereports.bmj.com) for more articles like this and to become a Fellow