

CASE REPORT

Neurological disorders caused by two cerebral alveolar hydatid cysts in an old woman: a rare case report

Hossein Mokhtari^{1,*}, Mohammadamin Sadeghdoust²,
Farnaz Aligolighasemabadi², Amirhossein Hashemiattar³, Vahid Ariabod⁴
and Saied Rahighi⁵

¹Department of Infectious Disease, Mashhad Medical Sciences Branch, Islamic Azad University, Mashhad, Iran, ²Department of Internal Medicine, Mashhad Medical Sciences Branch, Islamic Azad University, Mashhad, Iran, ³Department of Radiology, Mashhad Medical Sciences Branch, Islamic Azad University, Mashhad, Iran, ⁴Department of Pathology, Mashhad Medical Sciences Branch, Islamic Azad University, Mashhad, Iran, and ⁵Department of Neurosurgery, Mashhad Medical Sciences Branch, Islamic Azad University, Mashhad, Iran

*Correspondence address. Department of Infectious Disease, Mashhad Medical Sciences Branch, Islamic Azad University, Mashhad 9137714641, Iran. Tel: +98-51-3225-0047; Fax: +98-51-3225-0048; E-mail: hoinmokhtari@gmail.com

Abstract

Alveolar hydatid disease, caused by *Echinococcus multilocularis*, is a life-threatening infectious disease which primarily occurs in the liver. Intracranial hydatid disease is a rare presentation with reported incidence of ~1% of all cases. Here we reported a 60-year-old woman, with the past history of hydatid cysts in her liver, who was presented to us with progressive symptoms consist of headaches, diminished vision, cognitive disorders and delusion. She was disoriented in time, space and person. Bilateral mild papilledema and exaggerated reflexes were observed. Magnetic resonance imaging of the brain revealed two intra-axial multilocular cystic masses in the fronto-parietal and parieto-occipital regions. The patient underwent two operations and the lesions were removed without any rupture. Medical therapy with Albendazole was started. Neurological symptoms disappeared a few weeks after the surgeries. Although multiple alveolar hydatid cysts are extremely rare, they should be considered in the differential diagnosis of intracranial cystic lesions.

INTRODUCTION

Alveolar hydatid disease, a chronic disease caused by infestation of the larval stage of the tape worm *Echinococcus multilocularis*, is one of the world's most dangerous helminth associated zoonoses [1, 2]. It is a significant health burden in high endemic regions such as North America, Central Europe, Russia, China and Turkey. Iran is believed to be an endemic area for *E. multilocularis* [1, 3]. Humans, as the incidental intermediary host, get infected by ingestion of the parasite eggs which exist in the

food or water contaminated by the fecal materials of definitive hosts such as red fox, dogs and cats [4].

Human infections are located primarily in the liver, but secondary or metastatic lesions occur when metacestodes spread from the inevitably involved liver to other organs such as the lungs and brain. Cerebral involvement is a rare presentation with reported incidence of ~1% of all cases [5]. Although the cysts tend to be isolated, here we present a case of multiple alveolar hydatid cysts in the brain.

Received: April 21, 2017. Revised: June 3, 2017. Accepted: July 4, 2017

© The Author 2017. Published by Oxford University Press.

This is an Open Access article distributed under the terms of the Creative Commons Attribution Non-Commercial License (<http://creativecommons.org/licenses/by-nc/4.0/>), which permits non-commercial re-use, distribution, and reproduction in any medium, provided the original work is properly cited. For commercial re-use, please contact journals.permissions@oup.com

CASE REPORT

A 60-year-old woman who is living in a middle socioeconomic group in urban area of Mashhad city (Iran), was presented to us complaining of progressive symptoms consist of headaches, diminished vision in both eyes and cognitive disorders over the past 2 weeks. Delusion was added to the symptoms just over the last three days. Abnormal movements, seizure or fever were not experienced. The patient had the history of two alveolar hydatid cysts in her liver: one in the left lobe that was excised 6 years ago and the other one in the right lobe which was inoperable and was treated with Albendazole (400 mg/bid/orally) taken with meal for lifetime. She had past history of consuming the desert vegetables for many years but she had no direct contact with animals. Family history of the patient was unremarkable. On examination, the vital signs were stable. She was completely disoriented in time, space and person. Bilateral papilledema and exaggerated reflexes were observed. Laboratory tests showed mild leukocytosis ($15\,400/\text{mm}^3$) without eosinophilia. Slightly elevated liver enzymes were observed. Specific serological test for *E. multilocularis* was not available in the laboratories of our country. Other routine laboratory investigations were unremarkable. Magnetic resonance imaging (MRI) of the brain showed two intra-axial multilocular cystic masses. One in left fronto-parietal and the other in right parieto-occipital region (Fig. 1). Cystic fluid was isotense with CSF in both T1-weighted and T2-weighted sequences. Perilesional edema and some mass effects was noted. Computed tomography (CT) image with and without contrast revealed no mural calcification (Fig. 2). Abdominal ultrasonography showed calcified hydatid cystic in the posterior segment of right lobe of the liver measuring $112 \times 108 \times 106 \text{ mm}^3$. Echocardiography, chest X-ray and pelvic ultrasonography were normal. The diagnosis of alveolar cerebral hydatid cysts was made based on these findings. The patient was scheduled to undergo two separate surgeries because the cysts were in two completely different locations in the brain. There was a gap of 5 weeks between the operations. She did not take any medical therapy before the surgery except Albendazole. The lesions which were fix (not mobile) in the brain parenchyma, were completely removed under general anesthesia without any rupture (Fig. 3). The biopsy of the lesions showed two irregular tannish-brown, solid and cystic tissues measuring $4.5 \times 3 \times 2 \text{ cm}^3$ and $3 \times 2 \times 1.5 \text{ cm}^3$. Microscopic sections showed brain tissue with multiple cysts composed of laminated layer with no

conspicuous germinative layer or daughter cysts, surrounded by a marked granulomatous reaction with many foreign-body multinucleated giant cells and areas of necrosis (Fig. 4). Patient was discharged with Albendazole treatment (15 mg/kg) for lifetime as she had associated inoperable liver involvement. Doses were divided twice a day taken with fatty meals (400 mg/bid/orally). The drug is used monthly, then it is discontinued for 2 weeks to check liver function tests and complete blood count.

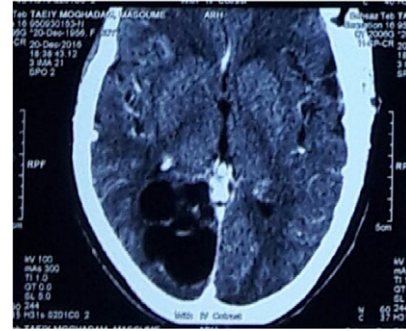


Figure 2: cranial CT scan showing no calcification.

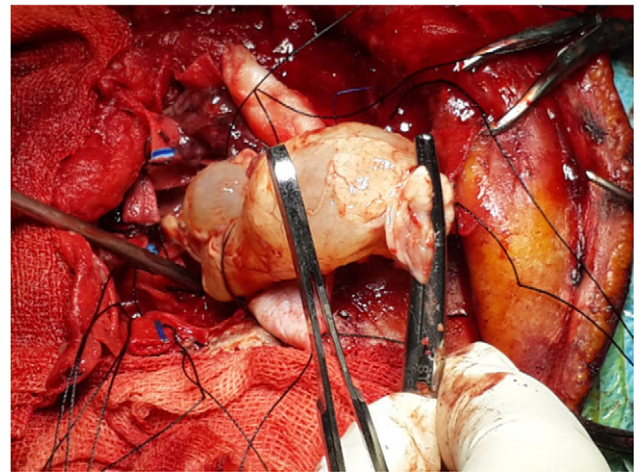


Figure 3: preoperative photograph showing the cysts excision.

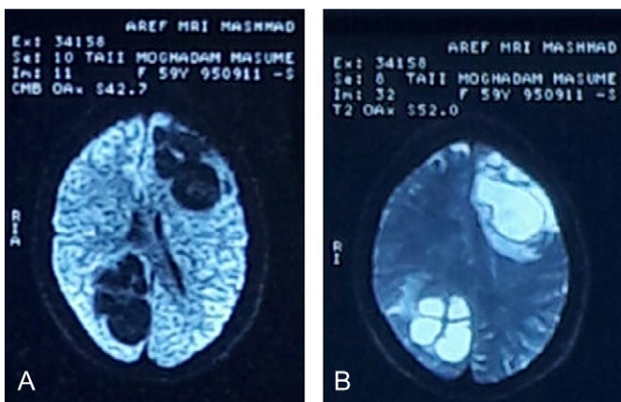


Figure 1: axial T1-weighted (A) and T2-weighted (B) MRI scan of brain demonstrating two intra-axial multilocular cystic masses.

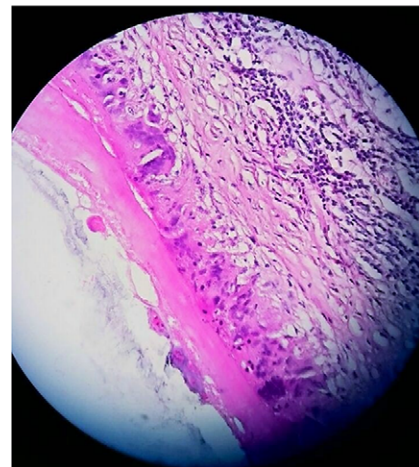


Figure 4: microscopic sections of right occipital brain cyst excision which is consistent with *Echinococcus multilocularis* cyst (H&E, $\times 400$).

Monthly post-operative follow-up showed improvement in the vision and the neurological disorders. The symptoms disappeared in about one month after the surgeries. There was no relapse until today (7 months after the operations).

DISCUSSION

Primary Cerebral hydatid cyst, as a rare fatal manifestation of *E. multilocularis*, occurs by direct infestation of the brain by larvae. The commonest site is middle cerebral territory commonly affects the parietal lobe [6]. However, the cysts in our patient occurred in fronto-parietal and parieto-occipital regions. Even though multiple alveolar hydatid cysts are uncommon, this patient had two alveolar hydatid cysts in her brain.

Less information is available regarding cerebral alveolar cysts pathogenesis in human. Since the larval masses proliferates indefinitely by exogenous budding and invades the surrounding tissues, they might resemble the appearance and behavior of malignancy [4,7]. They could develop through one of the following procedures. First way which is rare, is that the ingestion of multiple larvae leads to bilateral and multiple primary cerebral lesions. In such cases, larvae pass through the capillary filter of the liver and lungs, enter into the systemic circulation and reach the brain. The other way is that the rupture of primary hydatid cyst due to trauma, surgery or spontaneously causes secondary multiple cerebral cysts [2]. This one seems to be more probable explanation for our case because the patient had an inoperable alveolar hydatid cyst in the right lobe of liver since 6 years ago. However, protoscolices are rarely observed in infections of humans and the parasite is made of a thin cuticle with non-germinative membrane so the cerebral alveolar hydatid cysts may not be the cause for larval distant metastasis [3, 8].

The symptoms begin when the cyst become large enough to increase the intracranial pressure. Based on the size and location of the lesions clinical manifestations such as headache, vomiting, nausea, papilledema, ambulate, convulsion and hemiparesis can be seen [2, 5].

Neuroimaging, especially MRI, plays the main role in detecting the cerebral hydatid cysts. Alveolar cysts are usually associated with contrast enhancement, perilesional edema and calcification [8, 9]. Extracranial hydatid cysts must be investigated by chest X-ray and abdominal ultrasonography. Serological tests are of less importance and the diagnosis is only confirmed by histopathological examination of the cysts [2, 4].

The elective treatment for cerebral hydatid cyst is surgery and the patients normally undergo a radical resection [8]. The aim of the surgical operations is to remove the cysts without rupture. Medical therapy with Benzimidazole carbonate derivatives such as Albendazole and Mebendazole is also necessary (Albendazole is more effective). Albendazole is important in intracranial hydatidosis as it can sterilize the cysts, decrease the risk of anaphylaxis and recurrence rate [10]. Prolonged medical treatment is highly recommended for those patients who have inoperable hepatic cyst.

As a conclusion, although multiple cerebral alveolar hydatid cysts is rare, it should be considered in differential diagnosis of intracranial lesions. Such cases usually are presented with neurological symptoms. To reduce mortality and morbidity, they should be managed carefully. Immediate craniotomy

together with medical treatment is recommended. It is very important to remove the cysts completely and avoid the rupture during the surgery to prevent the recurrence and other associated side effects.

ACKNOWLEDGMENT

We acknowledge the patient who providing us complete information about his condition.

CONFLICT OF INTEREST STATEMENT

None declared.

FUNDING

There is no source of funding.

ETHICAL APPROVAL

Not required.

CONSENT

Informed consent was taken from patient.

GUARANTOR

The authors are the guarantor of this article.

REFERENCES

1. Torgerson PR, Keller K, Magnotta M, Ragland N. The global burden of alveolar echinococcosis. *PLoS Negl Trop Dis* 2010;4:e722.
2. Khan MB, Riaz M, Bari ME. Multiple cerebral hydatid cysts in 8-year-old boy: a case report and literature review of a rare presentation. *Surg Neurol Int* 2015;6:1-3.
3. Moro P, Schantz PM. Echinococcosis: a review. *Int J Infect Dis* 2009;13:125-33.
4. Geramizadeh B, Baghernezhad M. Hepatic alveolar hydatid cyst: a brief review of published cases from iran in the last 20 years. *Hepat Mon* 2016;16:1-4.
5. Senturk S, Oguz K, Soylemezoglu F, Inci S. Cerebral alveolar echinococcosis mimicking primary brain tumor. *Am J Neuroradiol* 2006;27:420-2.
6. Khuroo M. Hydatid disease: current status and recent advances. *Ann Saudi Med* 2001;22:56-64.
7. Tüzün M, Hekimoglu B. Various locations of cystic and alveolar hydatid disease: CT appearances. *J Comput Assist Tomogr* 2001;25:81-7.
8. Wang J, Cai B, You C. Surgical treatment options for cerebral alveolar echinococcosis: experience in six patients. *Neurol India* 2009;57:157.
9. Umerani MS, Abbas A, Sharif S. Intra cranial hydatid cyst: a case report of total cyst extirpation and review of surgical technique. *J Neurosci Rural Pract* 2013;4:125.
10. Hilmani S, Manfalouti M, Haouss M, Abdenbi EK, Abdessamad EA. Multiple and bilateral primary brain hydatid cyst dowling technique is not always appropriate (case report). *Int J Anat Radiol Surg* 2016;5:22-4.