

# Intracranial Volume in 15 Children with Bilateral Coronal Craniosynostosis

Robert C. J. Tovegård, MD\*  
 Giovanni Maltese, MD, PhD\*  
 Emma Wikberg, MSc†  
 Peter Bernhardt, PhD†  
 Lars Kölby, MD, PhD\*  
 Peter E. W. Tarnow, MD, PhD\*

**Background:** Intracranial volume (ICV) growth in patients with bilateral coronal craniosynostosis (BCS) is not well described. It is therefore important to evaluate the consequences of cranial surgery in children with this condition. The aim of the present study was to evaluate ICVs in patients operated on for BCS.

**Methods:** A consecutive series of patients with BCS were operated on using spring-assisted cranioplasty, with computed tomography scans in 0.6-mm slices, were included. A MATLAB-based computer program capable of measuring ICV was used. Patients were compared with an age- and gender-matched control group of healthy children. Student's *t* test was used for statistical analysis.

**Results:** Fifteen patients (7 girls and 8 boys) with 43 computed tomography scans were identified. The diagnoses were 13 syndromic BCS (3 Apert, 1 Crouzon, 6 Muenke, and 3 Saethre-Chotzen) and 2 nonsyndromic BCS. The mean preoperative volume at the age of 5 months ( $n = 15$ ) was 887 mL (range, 687–1082). Mean volume at follow-up at the age of 3 years ( $n = 13$ ) was 1369 mL (range, 1196–1616). In comparison, the mean ICVs for controls at the ages of 5 months ( $n = 30$ ) and 3 years ( $n = 26$ ) were 854 mL and 1358 mL, respectively. The differences were not statistically significant ( $P > 0.05$ ).

**Conclusions:** Patients with BCS were operated on with spring-assisted cranioplasty seem to maintain their age-related ICV at 3 years of age when compared to normal children. (*Plast Reconstr Surg Glob Open* 2014;2:e243; doi: 10.1097/GOX.0000000000000216; Published online 4 November 2014.)

**B**ilateral coronal craniosynostosis (BCS) is the premature fusion of the coronal suture bilaterally. The birth prevalence of craniosynostosis

is approximately 4 in 10,000 live births,<sup>1</sup> and BCS corresponds to 12% of the craniosynostosis cases in our unit. This cranial abnormality results in a brachycephalic skull shape, which is characterized by a short, wide, and high cranium. The deformity is usually syndromic, such as in Apert, Crouzon, Pfeiffer, Muenke, and Saethre-Chotzen syndromes, but it may also be nonsyndromic. Genetic analysis of the syndromic patients often reveals mutations in the genes encoding for the fibroblast growth factor receptor types (FGFR2, FGFR3) or in the TWIST1 gene.<sup>2</sup> The cranial malformation may prevent the brain from adequate development, with a risk of increased intracranial pressure (ICP) leading to, for example, blindness and cognitive impairment.<sup>3,4</sup>

From the \*Craniofacial Unit, Department of Plastic Surgery, Institute of Clinical Sciences, Sahlgrenska Academy at the University of Gothenburg, Sahlgrenska University Hospital, Gothenburg, Sweden; and †Department of Radiation Physics, Institute of Clinical Sciences, Sahlgrenska Academy at the University of Gothenburg, Sahlgrenska University Hospital, Gothenburg, Sweden.

Received for publication September 16, 2014; accepted October 10, 2014.

Copyright © 2014 The Authors. Published by Lippincott Williams & Wilkins on behalf of The American Society of Plastic Surgeons. PRS Global Open is a publication of the American Society of Plastic Surgeons. This is an open-access article distributed under the terms of the Creative Commons Attribution-NonCommercial-NoDerivatives 3.0 License, where it is permissible to download and share the work provided it is properly cited. The work cannot be changed in any way or used commercially.

DOI: 10.1097/GOX.0000000000000216

**Disclosure:** The authors have no financial interest to declare in relation to the content of this article. This study was supported by grants from the H.M. Queen Silvia Jubilee Foundation and the Anna and Edwin Berger Foundation. The Article Processing Charge was paid for by the authors.

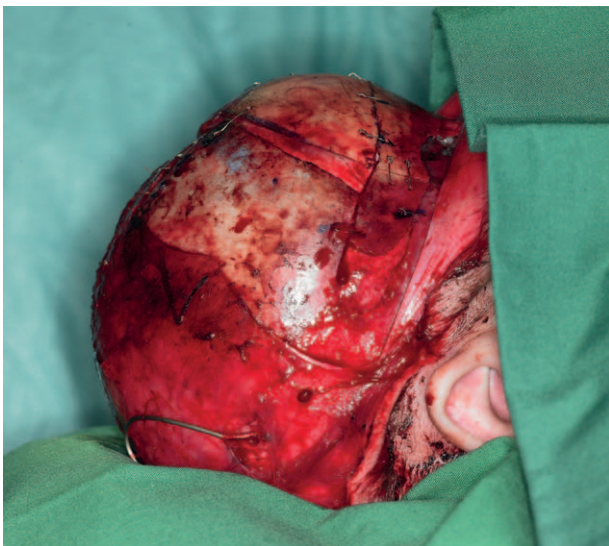Surgical correction typically consists of fronto-orbital advancement (FOA)/posterior skull expansion<sup>5-9</sup> and is usually performed before the first year of age.<sup>10</sup> Despite the fact that raised ICP may have devastating effects, there is still a debate about the relationship between intracranial volume (ICV) and raised ICP. The purpose of cranial surgery in BCS is to increase the ICV and normalize the skull shape. However, little is known about the effects of surgery on ICV. To date, no studies have been published describing specifically the ICV in patients with BCS.

The aim of the present study was to measure ICV preoperatively and at follow-up in children with BCS and to compare the ICVs with an age- and gender-matched control group.

## PATIENTS AND METHODS

### Patients

A consecutive series of patients were operated on with the standardized spring-assisted cranioplasty for BCS (Fig. 1) between 2005 and 2009 at the Craniofacial Unit, Department of Plastic Surgery, Sahlgrenska University Hospital, Gothenburg, Sweden, were extracted from the Sahlgrenska craniofacial registry. Computed tomography (CT) scans (Fig. 2) were routinely performed in 0.6-mm slices before surgery, at the time of spring removal, that is, 6 months after operation, and finally at 3 years of age. CT scans were obtained in the equipment General Electric Advantage Workstation Volumes share 4.3 (GE Healthcare, Buc, France).



**Fig. 1.** Intraoperative photograph of the technique used, including frontal remodeling with advancement, and spring distraction over the lambdoid sutures bilaterally.

### Volume Calculation

A computer program capable of measuring the total ICV by semiautomatic segmentation had been developed previously at our unit using MATrix LABoratory (MATLAB) version R2011a (MathWorks, Boston, MA).<sup>11</sup> The program uses the concept of region growing, which is an image segmentation method. Horizontal slices were determined by manually choosing the start-slice just above the foramen magnum and the end-slice just beneath the vertex of the skull. The program calculated the total ICV by multiplying the number of pixels in each slice by the pixel size and slice thickness. Measurements from preoperative, postoperative, and follow-up CT scans were performed in 0.6-mm slices ( $n = 43$ ) by the same investigator (R.C.J.T.).

An age- and gender-matched group of healthy children ( $n = 86$ ) who underwent CT scans for neurological or posttraumatic reasons were used as control data. To reduce the exposure to radiation, these CT examinations are routinely performed in thick 5-mm slices. Measurements of the control group were carried out by the coauthor (E.W.) and corrected for slice thickness.<sup>11</sup> The control group was compared to other published normative data.

### Statistical Analysis

Student's *t* test was used to compare ICVs; analyses were performed in the program SPSS version 19.0.0 (IBM, SPSS Statistics, Chicago, Ill.). All *P*-values less than 0.05 were considered significant.

## RESULTS

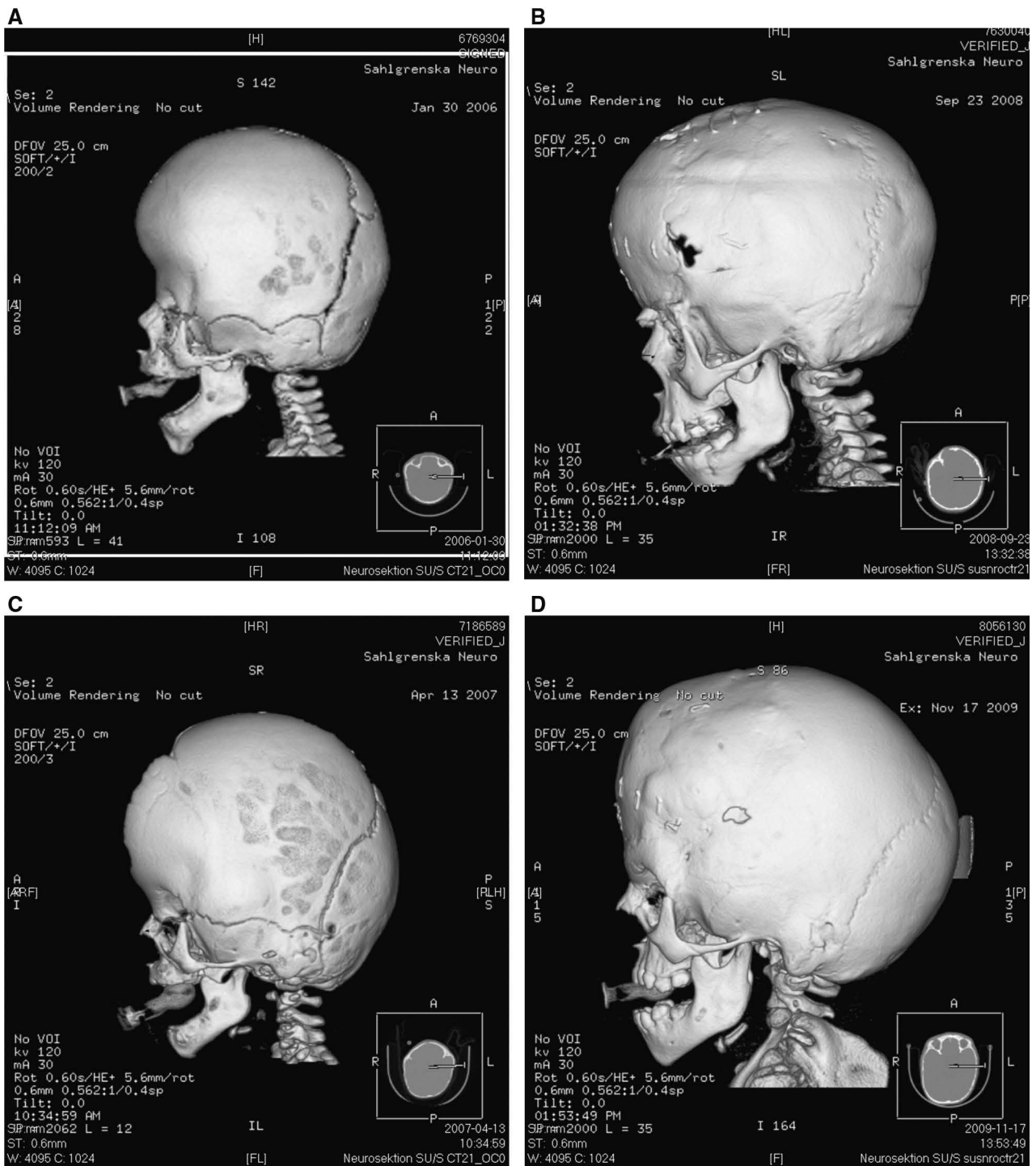
### Patients

Fifteen patients (7 girls and 8 boys) with 43 CT scans—15 preoperative (mean age, 5 months), 15 postoperative (mean age, 11 months), and 13 follow-up (mean age, 3 years)—who underwent spring-assisted cranioplasty for BCS were identified. Thirteen children had syndromic synostosis (3 Apert syndrome, 1 Crouzon syndrome, 6 Muenke syndrome, and 3 Saethre-Chotzen syndrome) and 2 had non-syndromic synostosis. DNA analyses were performed in 12 patients, and those with Apert syndrome were diagnosed clinically.

### Volumes

The mean preoperative ICV was 887 mL [standard deviation (SD), 139 mL], mean 6-month postoperative ICV was 1177 mL (SD, 133 mL), and mean follow-up ICV was 1369 mL (SD, 131 mL). Individual results for the patients are presented in Table 1.

In comparison, the mean ICV values for controls at the mean ages of 5 months ( $n = 30$ ), 11 months ( $n = 30$ ), and 3 years ( $n = 26$ ) were 854 mL



**Fig. 2.** CT scans of a girl with nonsyndromic bilateral coronal craniosynostosis (A and B) and a boy with Apert syndrome (C and D). A and C, Preoperative image; B and D, 3-year follow-up.

(SD, 137mL), 1118mL (SD, 117mL), and 1358mL (SD, 113mL), respectively (Fig. 3). The current controls differed somewhat when compared to other published normative data<sup>12,13</sup> (Table 2).

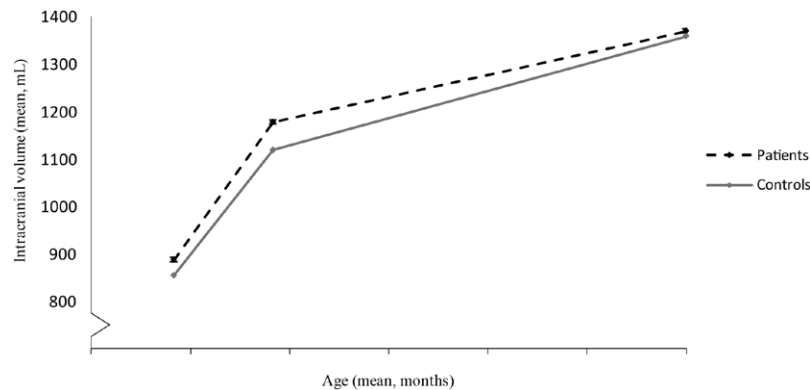
The differences between patients and controls in each age group were not statistically significant ( $P > 0.05$ ).

The difference between the mean ICV for patients at a mean age of 5 months (887mL) and at a mean age of 3 years (1369mL) was 482mL, an increase of 54.3%. The difference between the mean ICV for controls at a mean age of 5 months (854mL) and at a mean age of 3 years (1358mL) was 504mL, an increase of 59%.

**Table 1. Intracranial Volume in 15 Children with Bilateral Coronal Craniosynostosis**

Patient	Sex	Diagnosis	Measurements (mL)		
			Preoperative	Postoperative	Follow-up
1	Male	Apert	1079	1400	1616
2	Female	Apert	1038	1250	1439
3	Female	Apert	1082	1385	1559
4	Female	Crouzon	840	1186	1367
5	Male	Muenke	1010	1255	1434
6	Female	Muenke	737	997	1196
7	Male	Muenke	687	970	1243
8	Male	Muenke	960	1272	1452
9	Male	Muenke	995	1270	MD
10	Female	Muenke	968	1202	1402
11	Male	Saethre-Chotzen	838	1090	1243
12	Male	Saethre-Chotzen	732	1131	1334
13	Female	Saethre-Chotzen	817	1164	1288
14	Female	Nonsyndromic	821	1026	1220
15	Male	Nonsyndromic	705	1052	MD

Measurements were performed at 5 months (preoperative), 11 months (postoperative), and 3 years (follow-up). MD, missing data.



**Fig. 3.** Mean intracranial volume in patients preoperatively, postoperatively, and at 3-year follow-up compared with age- and gender-matched controls.

**Table 2. Total Intracranial Volume and Comparison of Normative Data**

Authors	Dekaban <sup>12</sup>	Abbott et al <sup>13</sup>	Present Study
No. individuals	<i>n</i> = 1058	<i>n</i> = 157	<i>n</i> = 86
Year	1977	2000	2013
Normal female	<i>n</i> = 503	<i>n</i> = 82	<i>n</i> = 42
6 months old	748	825	848*
12 months old	913	1025	1064*
36 months old	1148	1243	1325
Normal male	<i>n</i> = 555	<i>n</i> = 75	<i>n</i> = 44
6 months old	847	909	860*
12 months old	1010	1126	1166*
36 months old	1206	1374	1397
Methods	Calculation of ICV by mathematical formulas from head x-rays	Measurement of ICV in the software Persona from CT scans less than 5 mm in slice thickness	Measurement of ICV in a software using MATLAB from CT scans

All intracranial volumes are presented as mean values in mL.

\*Measurements for the controls in the present study were performed at the ages 5 months, 11 months, and 36 months.

Patients with Apert syndrome (*n* = 3) had greater ICV than the rest of the group (*n* = 12) preoperatively (1067 mL vs 842 mL) and at 3 years follow-up (1538 vs 1318 mL). When patients with Apert syndrome were

excluded, the results for the rest of the group were not significantly (*P* > 0.05) different from controls. Even when the 2 nonsyndromic cases were excluded, results were still not significantly different from controls.



## DISCUSSION

In this study, we investigated the ICV in patients with BCS and compared it with an age- and gender-matched control group. We found that the ICV in patients was similar to that of normal children, both preoperatively and postoperatively, and that patients maintained their age-related ICV at follow-up. To date, there have been few published studies on ICV in patients with complex craniosynostosis, none specifically describing the ICV in BCS.

We measured the ICVs from CT scans by semiautomatic segmentation in a MATLAB-based program previously developed at our unit.<sup>11</sup> Methods of ICV measurement have been improved over the last decades, from estimations using skull x-rays and mathematical formulas<sup>12,14</sup> to the use of computerized software for measuring ICV from CT scans,<sup>11,13,15,16</sup> or magnetic resonance imaging,<sup>17</sup> or by indirect methods using three-dimensional (3D) photography.<sup>18</sup> The disadvantages of using CT scans are the exposure to radiation and the need of anesthesia in some children, but ICV measurements from CT scans are more accurate than estimations from x-rays and 3D photographs. Magnetic resonance imaging has the advantage of accurately measuring brain and ventricular volumes separately. However, CT scans with low-radiation technique are currently used for diagnosis and follow-up at our unit. When using the 3D photography, there is no radiation; the ICV is estimated but can be converted into the absolute volume by dividing the estimated volume by a constant (1.34).<sup>18</sup>

Only a few studies have been published on normal ICV in children. The normative data of Lichtenberg<sup>14</sup> from 1960 have previously been accepted and used by several authors.<sup>19–24</sup> Posnick et al<sup>21</sup> were surprised to find ICVs above the norms of Lichtenberg in a series of patients with metopic and sagittal craniosynostosis. The study by Posnick et al<sup>21</sup> was later questioned by Marsh<sup>25</sup> because of the selection of normative data. The norms presented by Lichtenberg were obtained from a French population using skull x-ray and mathematical formulas for ICV estimation. Abbott et al<sup>13</sup> and Kamdar et al<sup>15</sup> have presented normative data from CT scans. The problem is that almost all craniofacial centers use different methods of ICV measurement, and the accuracy might be questioned when comparing such data. When we compared the available normative data at the ages of 6 months, 12 months, and 36 months from Dekaban<sup>12</sup> and Abbott et al<sup>13</sup> with our own data (Table 2), our measurements were greater in these age groups compared with Dekaban's, but more similar to Abbott's study. The differences in ICV may be explained by differences in selection of control groups and in measurement methodologies.

In our previous study, Wikberg et al,<sup>11</sup> the ICV measurements were evaluated for methodological errors. Precision was evaluated by running the program 10 times in each slice thickness, 0.6 mm and 5 mm. The differences between the 2 slice thicknesses were also calculated. In addition, human dry skulls were filled with agar gel and compared to the ICVs calculated from CT scans of the same skulls.

Surgical treatment of BCS has the purpose of increasing the ICV and normalizing the skull shape. Several surgical techniques are used at different craniofacial units. We use a combined procedure of frontal advancement and spring expansion of the posterior skull, together with biparietal restriction<sup>9</sup> (Fig. 1). Vinchon et al<sup>26</sup> use FOA with frontoparietal remodeling for nonsyndromic craniosynostosis with brachycephaly. Several craniofacial units use posterior skull expansion, with spring-assisted techniques<sup>27,28</sup> or with distractors,<sup>8,29</sup> as an initial surgical intervention in patients with BCS. Serlo et al<sup>29</sup> propose posterior cranial expansion as an initial procedure for syndromic cases because of the greater gain in ICV compared to the previously used technique with frontal advancement. In our combined procedure, the increase in ICV for patients was comparable to the normal ICV growth in healthy children. We believe that the skull expansion will have positive effects for the patient by reducing the risk of raised ICP. The normalization of ICV and cranial shape will probably also be of importance when it comes to intellectual development and psychosocial abilities. The ICV is age dependent and for that reason we were not capable to compare our results with that of other centers due to the lack of published data in the age groups 6 months, 12 months, and 3 years. The heterogeneity and small numbers of this study may show a type II error in the statistical analysis, something one has to be aware of when interpreting the results. Further case-control studies will be required to determine whether our results are comparable to those of other centers.

We know very little about the natural history of patients with craniosynostosis, which is a substantial drawback in the interpretation of our results. Patients who have not been operated on may have normal, supranormal, or subnormal ICV, the latter with a risk of increased ICP, and a cranial deformity due to compensatory skull growth in uninvolved sutures. No patient in this study had a ventriculoperitoneal shunt. Another concern is the heterogeneity of our study, by including syndromic and nonsyndromic BCS, that may cause a different outcome.

The relationship between ICV and ICP is however not well defined in the literature. Gault et al<sup>24</sup> presented a series of 66 children with craniosynostosis. Thir-

teen patients (20%) had raised ICP and 12 out of these (92%) also had a reduced ICV. Raised ICP was found to be more common in patients with multiple-suture craniosynostosis.<sup>24</sup> Fok et al<sup>23</sup> studied a series of 41 consecutive craniosynostosis cases; 38 patients (93%) had raised ICP, but only 4 (10%) had a reduced ICV.

Children with single-suture craniosynostosis may be more capable of compensating in their skull growth than patients with multiple-suture craniosynostosis. Craniofacial anomalies with multiple-suture involvement are seen, for example, in Apert, Crouzon, Pfeiffer, and Saethre-Chatzen syndromes. These patients are more prone to develop intracranial hypertension,<sup>30,31</sup> probably due to the lack of compensatory skull growth. Patients with Apert syndrome generally have a greater ICV compared with normal controls,<sup>19,20</sup> and there is no discernible difference between the 2 genotypes Ser252Trp and Pro-253Arg.<sup>32</sup> Interestingly, Gosain et al<sup>20</sup> noted that the ICV of patients with Apert syndrome was raised after 3.5 months of age, a raise that seemed unaffected by both ventriculomegaly and cranial vault surgery.

The skull surgery may not only keep the ICV in a normal range but also impair the skull growth, resulting in a reduced ICV. Therefore, to detect alterations, ICV measurements could be useful for surgical evaluation of patients with craniosynostosis.

## CONCLUSIONS

In conclusion, patients with BCS who are operated on with the spring-assisted cranioplasty seem to maintain their age-related ICV at 3 years of age when compared with normal controls. Further studies will be required to determine whether these short-term results continue into adulthood.

**Robert Tovetjärn, MD**

Craniofacial Unit  
Department of Plastic Surgery  
Sahlgrenska University Hospital  
SE-413 45 Gothenburg  
Sweden  
E-mail: robert.tovetjarn@gu.se

## ACKNOWLEDGMENTS

We thank our medical photographers Åsa Bell and Niclas Löfgrén. The study was performed in accordance with the Helsinki declaration on ethical principles for medical research. The study was approved by the Human Ethics Committee, the Medical Faculty at the University of Gothenburg (No. 784-11).

## REFERENCES

- Cohen MM. Epidemiology of craniosynostosis. In: Cohen MM, MacLean RE, eds. *Craniosynostosis: Diagnosis, Evaluation, and Management*. New York: Oxford University Press; 2000:112–118.

- Morriss-Kay GM, Wilkie AO. Growth of the normal skull vault and its alteration in craniosynostosis: insights from human genetics and experimental studies. *J Anat*. 2005;207:637–653.
- Tuite GF, Chong WK, Evanson J, et al. The effectiveness of papilledema as an indicator of raised intracranial pressure in children with craniosynostosis. *Neurosurgery* 1996;38:272–278.
- Arnaud E, Meneses P, Lajeunie E, et al. Postoperative mental and morphological outcome for nonsyndromic brachycephaly. *Plast Reconstr Surg*. 2002;110:6–12; discussion 13.
- Schouman T, Vinchon M, Ruhin-Coupet B, et al. Isolated bilateral coronal synostosis: early treatment by peri-fronto-orbital craniectomy. *J Craniofac Surg*. 2008;19:40–44.
- Marchac D, Renier D, Jones BM. Experience with the “floating forehead”. *Br J Plast Surg*. 1988;41:1–15.
- Wagner JD, Cohen SR, Maher H, et al. Critical analysis of results of craniofacial surgery for nonsyndromic bicoronal synostosis. *J Craniofac Surg*. 1995;6:32–37; discussion 38–39.
- White N, Evans M, Dover MS, et al. Posterior calvarial vault expansion using distraction osteogenesis. *Childs Nerv Syst*. 2009;25:231–236.
- Tovetjärn R, Maltese G, Kölby L, et al. Spring-assisted cranioplasty for bicoronal synostosis. *J Craniofac Surg*. 2012;23:977–981.
- Renier D, Lajeunie E, Arnaud E, et al. Management of craniosynostoses. *Childs Nerv Syst*. 2000;16:645–658.
- Wikberg E, Bernhardt P, Maltese G, et al. A new computer tool for systematic evaluation of intracranial volume and its capacity to evaluate the result of the operation for metopic synostosis. *J Plast Surg Hand Surg*. 2012;46:393–398.
- Dekaban AS. Tables of cranial and orbital measurements, cranial volume, and derived indexes in males and females from 7 days to 20 years of age. *Ann Neurol*. 1977;2:485–491.
- Abbott AH, Netherway DJ, Niemann DB, et al. CT-determined intracranial volume for a normal population. *J Craniofac Surg*. 2000;11:211–223.
- Lichtenberg R. Radiographie du crane de 226 enfants normaux de la naissance a 8 ans. *Impressionis Digitiformes, Capacité, Angles et Indices (Thesis)*. Paris: University of Paris, 1960.
- Kamdar MR, Gomez RA, Ascherman JA. Intracranial volumes in a large series of healthy children. *Plast Reconstr Surg*. 2009;124:2072–2075.
- Goldstein JA, Paliga JT, Wink JD, et al. A craniometric analysis of posterior cranial vault distraction osteogenesis. *Plast Reconstr Surg*. 2013;131:1367–1375.
- de Jong T, Rijken BF, Lequin MH, et al. Brain and ventricular volume in patients with syndromic and complex craniosynostosis. *Childs Nerv Syst*. 2012;28:137–140.
- McKay DR, Davidge KM, Williams SK, et al. Measuring cranial vault volume with three-dimensional photography: a method of measurement comparable to the gold standard. *J Craniofac Surg*. 2010;21:1419–1422.
- Gault DT, Renier D, Marchac D, et al. Intracranial volume in children with craniosynostosis. *J Craniofac Surg*. 1990;1:1–3.
- Gosain AK, McCarthy JG, Glatt P, et al. A study of intracranial volume in Apert syndrome. *Plast Reconstr Surg*. 1995;95:284–295.
- Posnick JC, Armstrong D, Bite U. Metopic and sagittal synostosis: intracranial volume measurements prior to and after cranio-orbital reshaping in childhood. *Plast Reconstr Surg*. 1995;96:299–309; discussion 310–315.
- Posnick JC, Armstrong D, Bite U. Crouzon and Apert syndromes: intracranial volume measurements before and

- after cranio-orbital reshaping in childhood. *Plast Reconstr Surg*. 1995;96:539–548.
23. Fok H, Jones BM, Gault DG, et al. Relationship between intracranial pressure and intracranial volume in craniosynostosis. *Br J Plast Surg*. 1992;45:394–397.
  24. Gault DT, Renier D, Marchac D, et al. Intracranial pressure and intracranial volume in children with craniosynostosis. *Plast Reconstr Surg*. 1992;90:377–381.
  25. Marsh J. Metopic and sagittal synostosis: intracranial volume measurements prior to and after cranio-orbital reshaping in childhood: discussion. *Plast Reconstr Surg*. 1995;96:310–315.
  26. Vinchon M, Pellerin P, Baroncini M, et al. Non-syndromic oxycephaly and brachycephaly: a review. *Childs Nerv Syst*. 2012;28:1439–1446.
  27. Arnaud E, Marchac A, Jeblaoui Y, et al. Spring-assisted posterior skull expansion without osteotomies. *Childs Nerv Syst*. 2012;28:1545–1549.
  28. de Jong T, van Veelen ML, Mathijssen IM. Spring-assisted posterior vault expansion in multisuture craniosynostosis. *Childs Nerv Syst*. 2013;29:815–820.
  29. Serlo WS, Ylikontiola LP, Lähdesluoma N, et al. Posterior cranial vault distraction osteogenesis in craniosynostosis: estimated increases in intracranial volume. *Childs Nerv Syst*. 2011;27:627–633.
  30. Renier D, Sainte-Rose C, Marchac D, et al. Intracranial pressure in craniostenosis. *J Neurosurg*. 1982;57:370–377.
  31. Woods RH, Ul-Haq E, Wilkie AO, et al. Reoperation for intracranial hypertension in TWIST1-confirmed Saethre-Chotzen syndrome: a 15-year review. *Plast Reconstr Surg*. 2009;123:1801–1810.
  32. Anderson PJ, Netherway DJ, Abbott AH, et al. Analysis of intracranial volume in Apert syndrome genotypes. *Pediatr Neurosurg*. 2004;40:161–164.