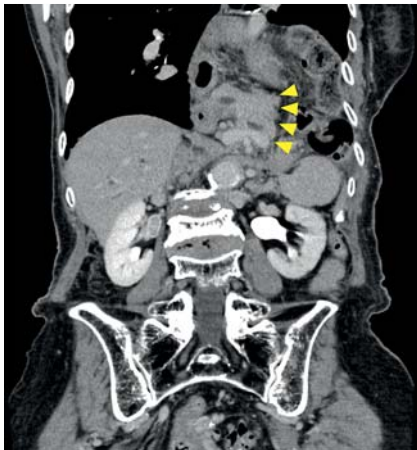
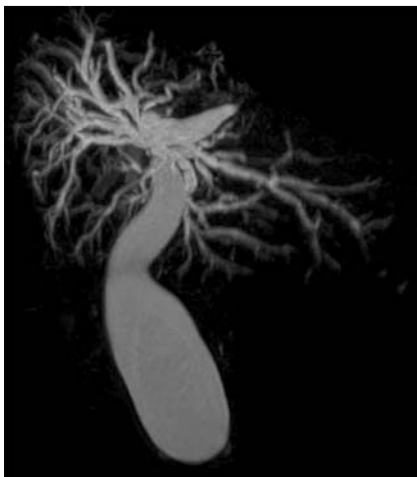


## Successful biliary drainage in a patient with a giant hiatal hernia and pancreatic prolapse using the percutaneous–endoscopic rendezvous technique

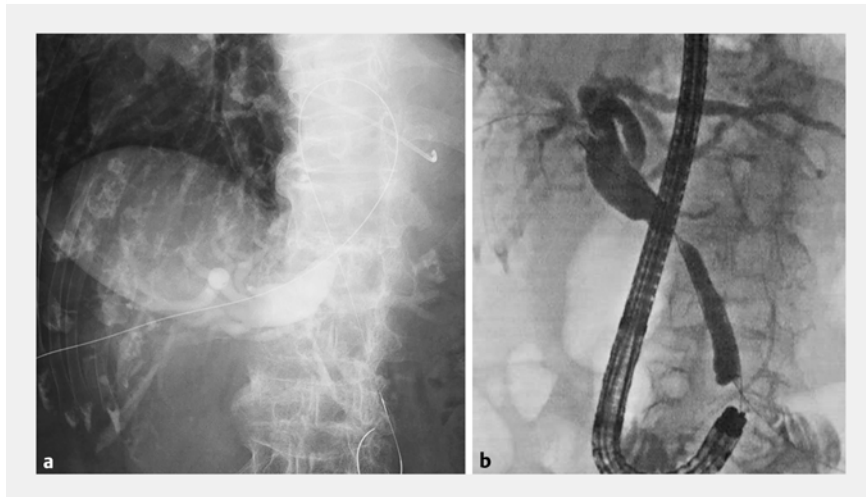


► **Fig. 1** Contrast-enhanced computed tomography showing a giant hiatal hernia with pancreatic prolapse into the thoracic cavity.



► **Fig. 2** Magnetic resonance cholangiopancreatography showing the inverted bile duct.

In patients who have a giant hiatal hernia, it is often difficult to advance a duodenoscope to the papilla of Vater [1]. In extremely rare cases of pancreatic prolapse into the thoracic cavity, endoscopic retrograde cholangiopancreatography (ERCP) is challenging because the orientation of the bile and pancreatic



► **Fig. 3** Fluoroscopic views during the percutaneous–endoscopic rendezvous technique showing: **a** the guidewire being advanced to the duodenum, although the orientation of the bile duct was inverted; **b** the hiatal hernia having been released and biliary cannulation achieved after the scope had been advanced into the duodenum.

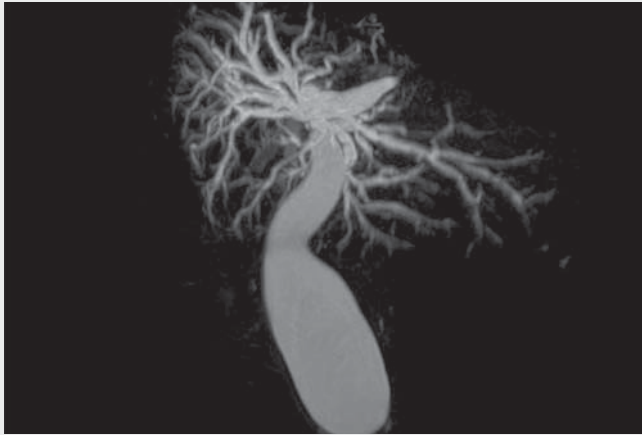
ducts is inverted [2, 3]. Herein, we report a case of successful biliary drainage, performed using the percutaneous–endoscopic rendezvous technique, in a patient with a giant hiatal hernia and pancreatic prolapse [4].

An 88-year-old woman was transferred from another hospital for treatment of obstructive jaundice due to distal bile duct cancer. Contrast-enhanced computed tomography revealed a giant hiatal hernia with pancreatic prolapse into the thoracic cavity (► **Fig. 1**). Magnetic resonance cholangiopancreatography revealed that the orientation of the bile duct was inverted (► **Fig. 2**). Although ERCP was attempted with a duodenoscope, access to the papilla was difficult owing to the giant hiatal hernia. We did reach the papilla using a forward-viewing scope (SIF-H290S; Olympus, Tokyo, Japan), but attempted biliary cannulation failed, even after performing precutting. Subsequently, the percutaneous–endoscopic rendezvous technique was performed. The B5 bile duct was punctured

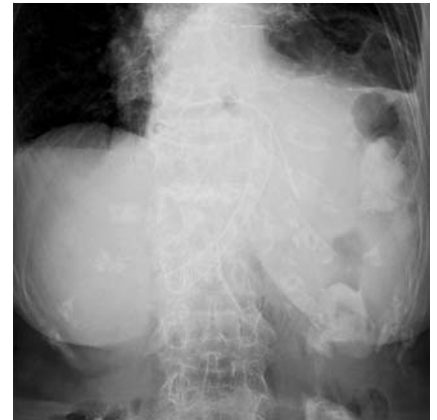percutaneously, and the guidewire (VisiGlide 2; Olympus) was advanced to the duodenum. The forward-viewing scope was advanced to the papilla, and biliary cannulation was achieved alongside the guidewire (► **Fig. 3**). Finally, a covered self-expanding metal stent (WallFlex Biliary RX Stent, 10×60 mm; Boston Scientific Corp., Natick, Massachusetts, USA) was successfully deployed (► **Video 1**; ► **Fig. 4**). The patient was discharged 4 days after the procedure without any adverse events. She had no symptoms until a year later, when the jaundice again flared up.

More recently, endoscopic ultrasonography-guided biliary drainage has been developed but, in patients with a giant hiatal hernia, there is a risk of mediastinitis occurring from the punctured thoracic cavity. Consideration of a multidisciplinary approach is indispensable to ensure patient safety in difficult cases.

Endoscopy\_UCTN\_Code\_TTT\_1AR\_2AZ



**▶ Video 1** Successful biliary drainage is performed in a patient with a giant hiatus hernia and pancreatic prolapse using the percutaneous-endoscopic rendezvous technique.



**▶ Fig. 4** Fluoroscopic view after deployment of a covered self-expanding metal stent; the hernia relapsed immediately after endoscopic retrograde cholangiopancreatography was completed.

## Competing interests

A. Katanuma has received lecture fees from Olympus Co., Tokyo, Japan. The remaining authors declare that they have no conflict of interest.

## The authors

**Kosuke Iwano, Tatsuya Ishii, Tsuyoshi Hayashi, Toshifumi Kin, Akio Katanuma**  
Center for Gastroenterology, Teine-Keijinkai Hospital, Sapporo, Hokkaido, Japan

## Corresponding author

**Kosuke Iwano, MD**  
Center for Gastroenterology, Teine-Keijinkai Hospital, 1-40, 12-chome, 1-jou, Maeda, Teine-ku, Sapporo 006-0811, Hokkaido, Japan  
ksk.own@gmail.com

## References

- [1] Sakai H, Iwai N, Okuda T et al. Single-balloon-assisted ERCP in a patient with a giant hiatal hernia. *Gastrointest Endosc* 2021; 94: 1147–1148

- [2] Itoi T, Watanabe H, Gotoda T et al. Therapeutic endoscopic retrograde cholangiopancreatography using a large dilating balloon in a patient with upside-down stomach and bile duct stones (with video). *J Hepatobiliary Pancreat Sci* 2015; 22: 177–179
- [3] Khirfan K. A rare cause of difficult endoscopic retrograde cholangiopancreatography. *Gastroenterology* 2020; 158: e10–e11
- [4] Martin DF. Combined percutaneous and endoscopic procedures for bile duct obstruction. *Gut* 1994; 35: 1011–1012

## Bibliography

*Endoscopy* 2022; 54: E842–E843  
DOI 10.1055/a-1816-7678  
ISSN 0013-726X  
published online 13.5.2022  
© 2022. The Author(s).

This is an open access article published by Thieme under the terms of the Creative Commons Attribution-NonDerivative-NonCommercial License, permitting copying and reproduction so long as the original work is given appropriate credit. Contents may not be used for commercial purposes, or adapted, remixed, transformed or built upon. (<https://creativecommons.org/licenses/by-nc-nd/4.0/>)  
Georg Thieme Verlag KG, Rüdigerstraße 14, 70469 Stuttgart, Germany



## ENDOSCOPY E-VIDEOS

<https://eref.thieme.de/e-videos>



*Endoscopy E-Videos* is an open access online section, reporting on interesting cases and new techniques in gastroenterological endoscopy. All papers include a high quality video and all contributions are freely accessible online. Processing charges apply (currently EUR 375), discounts and waivers acc. to HINARI are available.

This section has its own submission website at <https://mc.manuscriptcentral.com/e-videos>