

Received: 2020.05.27  
Accepted: 2020.09.17  
Available online: 2020.10.02  
Published: 2020.11.13

# Acute Respiratory Distress and Hyperchloremic Metabolic Acidosis as a Result of Massive Irrigation Fluid Extravasation After Arthroscopic Shoulder Surgery: A Case Report and Recommendations for Preventable Complications

## Authors' Contribution:

Study Design A  
Data Collection B  
Statistical Analysis C  
Data Interpretation D  
Manuscript Preparation E  
Literature Search F  
Funds Collection G

BCDEF 1 **Raid A. Abutalib**  
BCDEF 1 **Asim J. Alamri**  
EF 1 **Samir A. Aqel**  
AC 1 **Ibrahim M. Alhumaidi**  
AB 2 **Ibrahim A. Almohini**

1 Department of Orthopedic Surgery, Prince Mohammed Bin Abdulaziz Hospital, Almadinah Almunawwarah, Saudi Arabia  
2 Department of Orthopedics, College of Medicine, King Saud Bin Abdulaziz University of Health Sciences, Riyadh, Saudi Arabia

**Corresponding Author:** Raid A. Abutalib, e-mail: [raidabu@yahoo.com](mailto:raidabu@yahoo.com)

**Conflict of interest:** None declared

**Patient:** Female, 68-year-old  
**Final Diagnosis:** Pleural effusion  
**Symptoms:** Breathlessness • shortness of breath  
**Medication:** —  
**Clinical Procedure:** Arthroscopic Rotator Cuff repair  
**Specialty:** Orthopedics and Traumatology

**Objective:** Unusual or unexpected effect of treatment  
**Background:** Airway compromise caused by massive fluid extravasation in association with arthroscopic shoulder surgery is rare. However, it is even more rare to occur as a result of pleural effusion. We present this case to increase the awareness of this rare complication and show how to minimize the likelihood of this uncommon incident.  
**Case Report:** We describe a case of a 68-year-old woman who underwent elective shoulder arthroscopy for rotator cuff repair. She had immediate postoperative shortness of breath and was found to have bilateral pulmonary edema and pleural effusion accompanied by metabolic acidosis. She was managed conservatively in the intensive care unit and then transferred to the general ward after clinical and radiological improvement the next day.  
**Conclusions:** This uncommon complication was self-limiting, and the patient recovered uneventfully. High clinical suspicion is required to address this event so proper rapid management can be made.

**MeSH Keywords:** Airway Obstruction • Arthroscopy • Pleural Effusion • Pulmonary Edema • Rotator Cuff • Shoulder Joint

**Full-text PDF:** <https://www.amjcaserep.com/abstract/index/idArt/926357>



2090



—



5



26

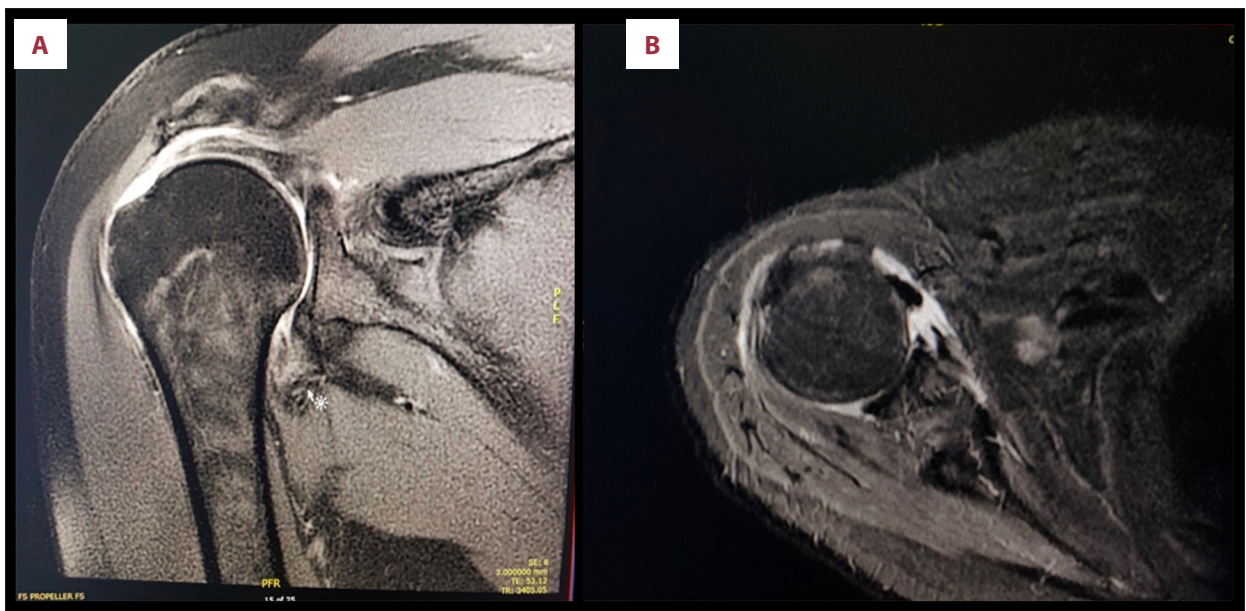


## Background

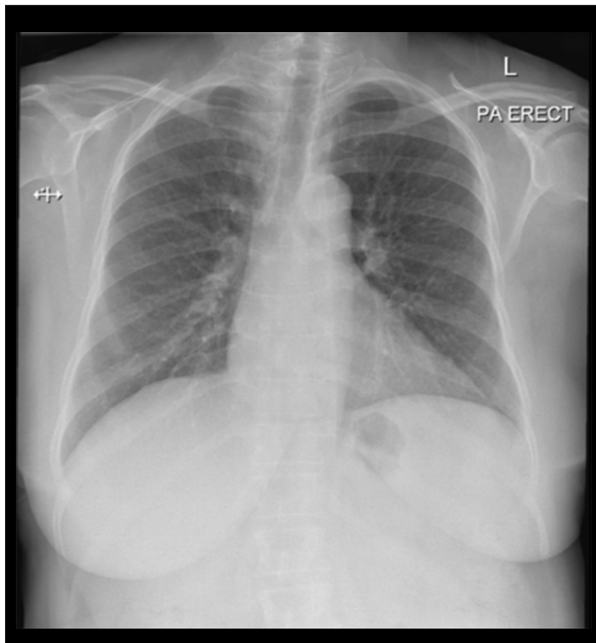
A shoulder arthroscopic procedure is a well-tolerated intervention that offers minimal invasive technique with less soft-tissue trauma compared with the open approach [1]. However, a small amount of fluid extravasation from the joint space into the deltoid muscles occurs commonly during shoulder arthroscopy, which is inevitable and is often self-limiting [2]. Only a significant amount of fluid extravasation reported in some cases can lead to life-threatening respiratory tract obstruction. Nevertheless, all incidents markedly improved within 24 h after the arthroscopic procedure [1,3–8]. Other respiratory complications, including pneumothorax, pulmonary edema, pleural effusion, and mediastinal effusion with airway compression, were also reported [9–11]. Besides previous complications, airway compromise caused by massive fluid extravasation is rarely associated with shoulder surgery, and also rarely occurs from pleural effusion [12]. In this report, we describe a woman who underwent elective shoulder arthroscopy and had immediate postoperative breathing difficulty and pleural effusion. This complication is addressed as a life-threatening airway compromise that might occur if not managed properly [12]. The unique presentation in this case that was not observed in previous reports is the development of hyperchloremic metabolic acidosis as a result of systemic absorption of extravasated irrigation fluid.

## Case Report

A 68-year-old woman presented to the orthopedic clinic complaining of right shoulder pain for 6 months that was associated with limitation of movement, which affects her activities of daily living. The pain was aggravated by lying on the right shoulder, reaching, and lifting with right arm. It is worth noting that there was no history of trauma, fever, or multiple joint pain. She had a positive history of diabetes and hypertension. Upon physical examination, her height was 150 cm, weight 60 kg with a body mass index (BMI) of 26.7 kg/m<sup>2</sup>. A diffuse tenderness was noted throughout the right shoulder, and the active range of motion was limited because of pain, especially on abduction and internal rotation. Furthermore, Hawkins sign, Jobe test, Neer sign, and lift-off test were all positive. The rest of the examination was unremarkable. Radiography of the right shoulder revealed mild acromioclavicular joint degenerative changes. Magnetic resonance imaging showed massive rotator cuff tear with subscapularis and biceps tendons subluxation (Figure 1). The patient was scheduled to undergo an elective right shoulder arthroscopy for rotator cuff repair. She was referred to the preoperative anesthesia clinic. Physical assessment showed no abnormalities and laboratory investigations were all within the normal range. Electrocardiogram (ECG) and chest radiograph had normal results (Figure 2). The patient was labeled as American Society of Anesthesiologists class 2. The procedure was performed under general anesthesia and interscalene block. The patient was placed in a beach-chair position. The posterior portal was placed about 2 cm inferior and 1 cm medial to the posterolateral corner of the

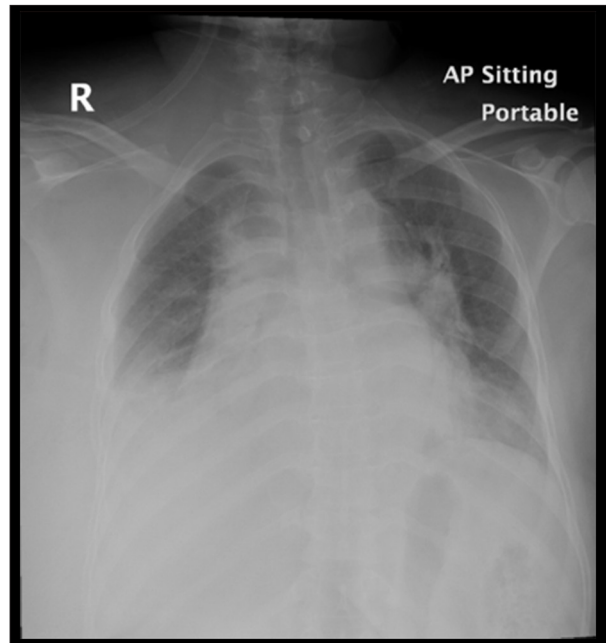


**Figure 1.** (A) Right shoulder magnetic resonance imaging without contrast (coronal view) showing retracted massive rotator cuff tear. (B) Right shoulder magnetic resonance imaging without contrast (axial view) showing retracted subscapularis tear with subluxation of the long head of biceps.



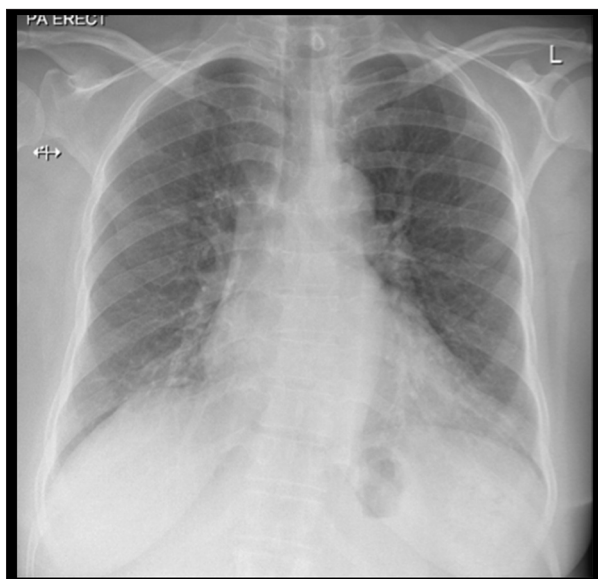**Figure 2.** Posteroanterior erect chest radiograph 1 week before surgery showing no abnormalities.

acromion. The anterior portal was placed lateral to the coracoid process and anterior to the acromioclavicular joint, and the lateral portal was inserted 1 cm distal to the lateral edge of the acromion. The amount of irrigation fluid was 30 L of normal saline; 0.33 mg of epinephrine was added to each liter. The shoulder joint space was then inflated by a Dyonics 25 fluid management system pressure pump infusion, with pressure ranging between 50 and 60 mmHg and flow rate ranging from 0.8 to 2.5 L/min. Exploration was made, and tears of subscapularis and supraspinatus were identified along with subluxation of the biceps tendon. Repair of subscapularis and supraspinatus using suture anchors, tenotomy of the biceps tendon, coracoplasty, and acromioplasty were all carried out. There were no complications during the procedure and the patient was stable intraoperatively. The duration of surgery was around 3 h. The patient was extubated as there was no airway compromise, and then shifted to the recovery room. Thirty minutes later, in the recovery room, the patient developed breathing difficulty, and her oxygen saturation dropped to 90% with a 5 L/min face mask. The respiratory rate was 30 breaths/min; the remaining vitals were within normal limits. On examination, the patient had marked swelling across the entire chest wall, including the right breast extending to the right neck and shoulder. She had dull percussion sounds over the right side of her chest wall. A decrease in air entry on the right side was noticed on auscultation as well. The chest radiograph showed an obliterated right costophrenic angle by homogenous opacity with suspicion of underlying basal lung consolidative collapse accompanied by bilateral hilar congestion more on the left side (Figure 3). The arterial blood gases

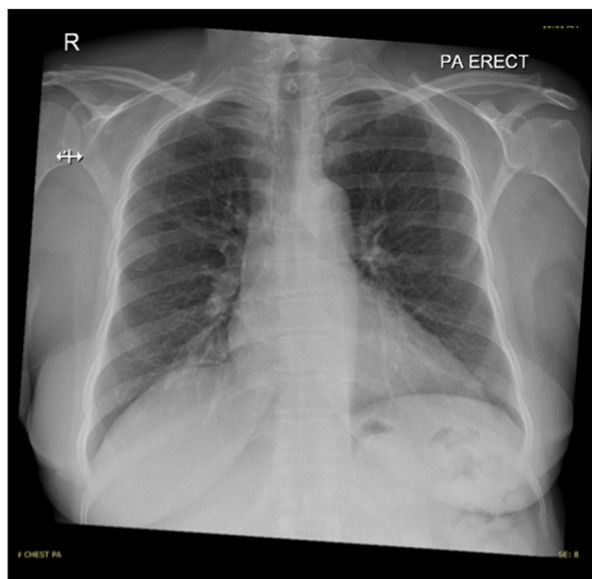


**Figure 3.** Anteroposterior semisitting portable chest radiograph immediately after surgery showing an obliterated right costophrenic angle by homogenous opacity, suggesting right pleural effusion producing adjacent consequent passive minimal subsegmental atelectasis accompanied by bilateral hilar congestion more on the left side.

(ABG) revealed pH 7.24 (reference range 7.35–7.45);  $p\text{CO}_2$  40.2 mmHg (reference range 35–45 mmHg);  $p\text{O}_2$  62.2 mmHg (reference range 75–100 mmHg);  $\text{HCO}_3^-$  17.2 mmol/L (reference range 22–26 mmol/L); base excess  $-9.5$  mmol/L (reference range  $-2.00$  to  $+2.00$  mmol/L); and lactic acid 3.19 mmol/L (reference range 0.5–2 mmol/L). Initial laboratory evaluation revealed the following values: sodium 142 mmol/L (reference range 136–145 mmol/L); potassium 4.3 mmol/L (reference range 3.5–5.1 mmol/L); chloride 116 mmol/L (reference range 101–111 mmol/L); and adjusted calcium 1.87 mmol/L (reference range 2.20 to 2.50). These results indicated a nonanion gap metabolic acidosis. Other values were: glomerular filtration rate of 113 (reference range 90–120  $\text{mL min}^{-1} [1.73 \text{ m}^2]^{-1}$ ); blood urea nitrogen 3.4 mg/dL (reference range 5–20 mg/dL); creatinine 50  $\mu\text{mol/L}$  (reference range 74–107  $\mu\text{mol/L}$ ); creatine kinase 226 U/L (reference range 22–198 U/L); lactate dehydrogenase 302 (reference range 140–280 U/L); troponin I level  $<0.010$  ng/mL (reference range 0 to 0.4 ng/mL); and brain natriuretic peptide (BNP) 42 pg/mL (reference range  $<100$  pg/mL). Complete blood count and liver function had unremarkable results. The patient was initially given a bolus dose of 40 mg of furosemide intravenously. After the stabilization of her respiratory condition and because she was hemodynamically stable, the patient was transferred to the intensive care unit for supportive management, further investigations, and



**Figure 4.** Posteroanterior erect chest radiograph on the fourth postoperative day showed significant improvement of pulmonary edema and pleural effusion.



**Figure 5.** Posteroanterior erect chest radiograph at 2-week follow-up revealed nearly complete resolution of pulmonary edema and pleural effusion.

observation. In the intensive care unit, she continued to be closely monitored with a simple face mask at 2–3 L/min of oxygen. Echocardiogram showed normal left ventricular size and function, normal valves, and small pericardial effusion with 55% of left ventricular ejection fraction (reference range 50–70%). The patient's symptoms continued to improve during the first 6 h and she was completely asymptomatic after 24 h. On the second postoperative day, the patient was vitally stable with no respiratory distress. Her oxygen saturation was 97% on room air. The follow-up chest radiograph showed improvement of pleural effusion and resolution of pulmonary edema. The patient shifted to the orthopedic ward and stayed there for 3 days. On the third postoperative day, the chest radiograph was repeated, which showed a complete resolution of pleural effusion (Figure 4). Finally, she was discharged home on the fourth postoperative day in a stable condition. At 2-week follow-up, in the clinic, the patient's chest radiograph showed a complete resolution of all radiological findings (Figure 5).

## Discussion

On the basis of the presentation and radiological findings, the diagnosis of right-sided pleural effusion with bilateral pulmonary edema due to extravasation of irrigation fluid has been made. Other relevant causes of pulmonary edema associated with pleural effusion were ruled out, such as a cardiogenic/renal cause and iatrogenic volume overload [13]. Cardiogenic causes such as acute myocardial infarction and heart failure are unlikely as our patient has no history of cardiac disease. Echocardiography showed preserved ejection fraction with

normal left ventricular size and function and normal valves. Other cardiac investigations such as BNP, troponin I levels, and ECG were unremarkable. Despite a relatively low level of calcium, absence of other electrolyte disturbance and normal renal profile makes nephrogenic causes less likely. The presence of hyperchloremic metabolic acidosis found in ABG can be explained by the rapid systemic absorption of irrigation fluid. Prompt absorption of irrigation fluid containing sodium chloride causes a dilution of plasma bicarbonate, which elevates chloride level and further metabolic acidity with a normal anion gap as in our case [14]. This finding is supported by several studies reporting low plasma pH accompanied by hyperchloremia while using normal saline observed during intra-/perioperative time and acute-care setting [15–17]. Ringer's lactate is a relatively safe crystalloid because of the fact that chloride amount is roughly equal to the plasma concentration, whereas high concentration of chloride tends to be seen in normal saline [18,19]. Bhagat et al. revealed that the group given normal saline had hyperchloremic metabolic acidosis with hypocalcemia, which was also seen in our study [16]. The overall management of our patient was directed toward reversing hypoxia and decreasing the fluid overload, guided by serial physical examination, ABG analysis, and chest radiograph. The patient was given a bolus dose of 40 mg of furosemide intravenously to relieve the symptoms of fluid overload. Clinical and radiological resolution within hours confirms the diagnosis of fluid overload due to the extravasation of irrigation fluid. Although thoracentesis can be considered in the diagnosis and management of pleural effusion, it was recommended not to be utilized in our case since the patient's condition improved. The current evidence does not support utilizing steroids and

diuretics as part of medical management for fluid overload, where most of the cases recover during the first day and life-threatening airway compromise rarely occurs [20]. Several factors have been recognized in the literature that potentially predispose patients to the development of pleural effusion that was seen in our case. These factors include longer procedural time, subacromial involvement, and high BMI [3–8]. In contrast to young adults, older individuals and patient with high BMI have skin and subcutaneous tissues with prominent laxity that allow more diffusion of irrigation fluid out of the shoulder joint space [20,21]. Regional anesthesia such as interscalene brachial plexus block (ISB) has a significant advantage that offers better postoperative pain control with analgesia while avoiding multisystemic agents from general anesthesia [22]. Phrenic nerve injury is a rare complication of ISB that might happen because of its close anatomical relation with the brachial plexus; hence hemidiaphragm paralysis may occur. In our case, the absence of abnormally elevated hemidiaphragm decreases the possibility of nerve paresis [23,24]. Subacromial decompression might be the reason for pleural effusion and fluid extravasation in our case. The subacromial space lacks the surrounding capsule. Thus, an elevated amount of pump pressure is necessary for expanding the joint space, which increases the risk of fluid extravasation into anatomically related cavities in the neck and chest [10]. Morrison et al. reported that the clarity of the subacromial visual field could be achieved by maintaining a blood pressure difference (systolic blood pressure – subacromial space pressure) of 49 mmHg or less. Hence, the use of relative hypotensive anesthesia will prevent the significant bleeding that obscures the clarity of the subacromial visual field. Furthermore, it will permit lower pump pressures and significantly reduces the risk of fluid extravasation into the subcutaneous tissues of the shoulder [25]. With prolonged operation time, the volume of irrigation fluid will increase; hence, the risk of fluid extravasation. Khan et al. suggested that minimizing surgical duration to 90–120 min assists in reducing the risk of fluid extravasation and serious airway complications [26]. We believe that complexity of the procedure and unfamiliarity of the surgical nurses and assistant doctors with shoulder arthroscopic surgeries makes the lengthy operation require more irrigation fluid and high risk of extravasation.

## Recommendations

Early recognition of post-shoulder arthroscopy fluid extravasation and pleural effusion can prevent lethal airway compromise. After surgical drape removal, evaluating the soft tissues surrounding the shoulder, including the face, neck, and chest, helps to detect swelling. An immediate chest radiograph is highly recommended if severe soft-tissue swelling is noticed in the chest wall associated with decrease of oxygen saturation to rule out pleural effusion and serious respiratory conditions. Also, minimizing the operating time, which requires more experience and frequent participation in shoulder cadaveric courses and training the nurse staff and assistant doctors, and using the least possible amount of irrigation fluid with minimal pump pressure has better safety and low operation-related complications. Utilization of relatively hypotensive anesthesia also helps in reduction of bleeding; hence, pump pressure can be decreased.

## Conclusions

Arthroscopic shoulder procedures seem to be harmless and safe techniques. Nevertheless, they can carry a possible risk of respiratory complications and acid-base abnormalities, which may lead to lethal outcomes when not appropriately anticipated. Our case highlights the importance of anticipation of such complications while they can be prevented by performing proper fluid measurements and mastering skills in surgical practice.

## Acknowledgment

The authors thank Prof. Khalid I. Khoshhal, Pediatric Orthopedics, for his assistance in the writing of this case report.

## Conflicts of interest

None.

## References:

1. Vier BR, Mombell KW, Gagliano EL et al: Extravasation of fluid in arthroscopic shoulder surgery requiring prolonged intubation: A case report. *Patient Saf Surg*, 2019; 13: 21
2. Han JY, Lee KN: Extravasation of joint fluid into the mediastinum and the deep neck during arthroscopic shoulder surgery. *J Korean Soc Radiol*, 2014; 70(1): 43–46
3. Yang HS, Huh IY, Kim D et al: Pleural effusion caused by extravasation of irrigation fluid during arthroscopic shoulder surgery: A case report. *Korean J Anesthesiol*, 2009; 56(2): 217–20
4. Sharma M, Achar SK: Airway oedema during shoulder arthroscopy: How we played it safe! *Indian J Anaesth*, 2013; 57(3): 319–20
5. Blumenthal S, Nadig M, Gerber C, Borgeat A: Severe airway obstruction during arthroscopic shoulder surgery. *Anesthesiology*, 2003; 99(6): 1455–56
6. Orebaugh SL: Life-threatening airway edema resulting from prolonged shoulder arthroscopy. *Anesthesiology*, 2003; 99(6): 1456–58
7. Antonucci S, Orlandi P, Mattei PA, Amato F: Airway obstruction during arthroscopic shoulder surgery: Anesthesia for the patient or for the surgeon? *Minerva Anestesiol*, 2006; 72(12): 995–1000
8. Jirativanont T, Tritrakarn TD: Upper airway obstruction following arthroscopic rotator cuff repair due to excess irrigation fluid. *Anaesth Intensive Care*, 2010; 38(5): 957–58
9. Kim JB, Choi MK, Jeon YK, Lee JM: Chest wall swelling and pneumothorax after shoulder arthroscopy: Were the 2 events totally independent? *Medicine (Baltimore)*, 2017; 96(21): e7020
10. Gogia AR, Bajaj J, Sahni A, Saigal D: Negative-pressure pulmonary oedema in a patient undergoing shoulder arthroscopy. *Indian J Anaesth*, 2012; 56(1): 62–65
11. Gomide L, Santos C, Pereira C et al: Fluid leakage into the mediastinum and pleural effusion during shoulder arthroscopy: A case report. *Rev Bras Ortop*, 2007; 42(8): 266–68
12. Ko S, Jung K, Cha J, Song M, Choe C: Severe airway obstruction and pleural effusion after arthroscopic shoulder surgery: A case report. *Arthrosc Orthop Sports Med*, 2015; 2(2): 124–27
13. Burdett E, Roche AM, Mython MG: Hyperchloremic acidosis: Pathophysiology and clinical impact. *Transfus Altern Transfus Med*, 2003; 5(4): 424–30
14. Jameson JL, Fauci AS, Kasper DL et al: *Harrison's principles of internal medicine*. 20th ed. New York (NY): McGraw-Hill; 2018.
15. Pfortmueller CA, Funk GC, Reiterer C, et al. Normal saline versus a balanced crystalloid for goal-directed perioperative fluid therapy in major abdominal surgery: A double-blind randomised controlled study. *Br J Anaesth*, 2018; 120(2): 274–83
16. Bhagat H, Singhal V, Dash HH et al: Comparative evaluation of intraoperative use of normal saline, Ringer's lactate, and combination of normal saline and Ringer's lactate in neurosurgical patients – a preliminary randomized clinical trial. *Neurol India*, 2019; 67(2): 452–58
17. Barker ME: 0.9% saline induced hyperchloremic acidosis. *J Trauma Nurs*, 2015; 22(2): 111–16
18. Raghunathan K, Nailor P, Konoske R: What is the ideal crystalloid? *Curr Opin Crit Care*, 2015; 21: 309–14
19. Prough DS, Bidani A: Hyperchloremic metabolic acidosis is a predictable consequence of intraoperative infusion of 0.9% saline. *Anesthesiology*, 1999; 90: 1247–49
20. Memon M, Kay J, Gholami A et al: Fluid extravasation in shoulder arthroscopic surgery: A systematic review. *Orthop J Sports Med*, 2018; 6(5): 2325967118771616
21. Yoshimura E, Yano T, Ichinose K, Ushijima K: Airway obstruction involving a laryngeal mask airway during arthroscopic shoulder surgery. *J Anesth*, 2005; 19: 325–27
22. Park SK, Choi YS, Choi SW, Song SW: A comparison of three methods for postoperative pain control in patients undergoing arthroscopic shoulder surgery. *Korean J Pain*, 2015; 28(1): 45–51
23. Brandl F, Taeger K: The combination of general anesthesia and interscalene block in shoulder surgery. *Anesthetist*, 1991; 40(10): 537–42
24. Kayerker UM, Dick MM: Phrenic nerve paralysis following interscalene brachial plexus block. *Anesth Analg*, 1983; 62(5): 536–37
25. Morrison DS, Schaefer RK, Friedman RL: The relationship between subacromial space pressure, blood pressure, and visual clarity during arthroscopic subacromial decompression. *Arthroscopy*, 1995; 11(5): 557–60
26. Khan F, Padmanabha S, Shantaram M, Aravind M: Airway compromise due to irrigation fluid extravasation following shoulder arthroscopy. *J Anaesthesiol Clin Pharmacol*, 2013; 29(4): 578–79