




Contents lists available at ScienceDirect

International Journal for Parasitology: Parasites and Wildlife

journal homepage: [www.elsevier.com/locate/ijppaw](http://www.elsevier.com/locate/ijppaw)

## Are feral goats intermediate hosts for *Linguatula* (Pentastomida) in Australia?

Diane P. Barton<sup>a,\*</sup>, Bridgette Shackelford<sup>b</sup>, Shokoofeh Shamsi<sup>a</sup>, David Jenkins<sup>a</sup>

<sup>a</sup> School of Agricultural, Environmental and Veterinary Sciences, Charles Sturt University, Wagga Wagga, New South Wales, 2678, Australia

<sup>b</sup> School of Animal and Veterinary Sciences, The University of Adelaide, Roseworthy, South Australia, 5371, Australia

### ARTICLE INFO

#### Keywords:

Introduced parasite  
Introduced host  
Transmission ecology  
Zoonotic disease  
Meat inspection

### ABSTRACT

Feral goats, *Capra hircus* (Bovidae), currently occur across 28% of Australia, and are found in all states and territories as well as some offshore islands. Feral goats are harvested for live export or processed as game meat, with feral goats making up approximately 90% of goats sent to slaughter in Australia. Nymphs of the pentastomid parasite, *Linguatula serrata*, are common parasites of goats elsewhere in the world, where they cause Halzoun or Marrara disease in humans through the consumption of nymphs in raw or semi-cooked edible offal. Despite being commonly encountered in cattle at slaughter in Australia, *L. serrata* nymphs have never been reported from feral goats in Australia. Goats at slaughter, however, commonly show infections of lymph nodes, the majority of which are diagnosed as caseous lymphadenitis caused by bacteria, although a small number have no known aetiology. Examination of 33 feral goats from locations in New South Wales and South Australia found a *Linguatula* sp. nymph encased in the mesenteric lymph node of one goat from the Cooma region of New South Wales. The potential risk of transmission of *Linguatula* sp. to humans and other domestic animals is discussed. This study has highlighted the importance of continued surveys of feral animals for infection with parasites, especially as their distribution changes.

### 1. Introduction

Feral goats, *Capra hircus* (Bovidae), currently occur across 28% of Australia, and are found in all states and territories as well as some offshore islands (Anon, 2011). Goats were brought to Australia with European settlement and have become feral pests through a combination of accidental and deliberate releases of domestic goats (Fleming, 2004; Anon, 2011). Feral goats are more common in rocky or hilly semi-arid areas in western New South Wales (NSW), Queensland (Qld), South Australia (SA) and Western Australia (WA) (Anon, 2011; Pople and Froese, 2012), although high densities occur in the high rainfall areas along the eastern Australian coast, in the highlands of the Great Dividing Range (Fleming, 2004). The population of feral goats in western NSW was estimated at 3.38 million in 2013 (GICA, 2015), with annual increases of 5–10% of the population in a number of areas (Pople and Froese, 2012).

Feral goats are harvested for live export or processed as game meat, with feral goats making up approximately 90% of goats sent to slaughter in Australia (Pople and Froese, 2012; Jenkins et al., 2018; GICA, 2015). In 2010, 1.6 million feral goats were processed in abattoirs, with meat

used for domestic consumption as well as being exported (Pople and Froese, 2012); the value of exported goat meat in 2014 was \$248.1 million (GICA, 2015).

Very few studies have documented the parasite fauna of feral goats in Australia (Hein and Cargill, 1981; Beveridge et al., 1987; Jenkins et al., 2018). Feral goats have been found to act as reservoirs for a range of diseases that infect domestic production animals, especially sheep (Hein and Cargill, 1981; Beveridge et al., 1987; Fleming, 2004; Jenkins et al., 2018), and carry a range of external and internal parasites (Chief Vet Officer, 2016). There has not been, however, a systematic survey of the parasites of goats across a wide geographic range since the work of Beveridge et al. (1987).

As Australia becomes an important exporter of goats and goat meat worldwide, further studies to determine potential disease risks, and financial impacts of these diseases, are warranted (Jenkins et al., 2018). A lack of knowledge regarding feral goat biology and ecology, and their potential biosecurity risks, has been identified by the Goat Industry Council of Australia Strategic Plan (2020) as a potential threat to the industry.

*Linguatula serrata*, a pentastomid parasite, is commonly found in

\* Corresponding author.

E-mail address: [dibarton@csu.edu.au](mailto:dibarton@csu.edu.au) (D.P. Barton).

<https://doi.org/10.1016/j.ijppaw.2022.07.004>

Received 7 May 2022; Received in revised form 26 June 2022; Accepted 11 July 2022

Available online 15 July 2022

2213-2244/© 2022 The Authors. Published by Elsevier Ltd on behalf of Australian Society for Parasitology. This is an open access article under the CC BY-NC-ND license (<http://creativecommons.org/licenses/by-nc-nd/4.0/>).

goats elsewhere in the world, where they cause Halzoun or Marrara disease in humans through the consumption of nymphs in raw or semi-cooked edible offal (Fard et al., 2010; Eslami et al., 2018; Hajipour et al., 2019). Nymphs of *L. serrata* have been commonly encountered in Australian cattle (Pullar, 1936; Shamsi et al., 2017) but have not yet been reported from feral or domestic goats in Australia (Shamsi et al., 2020). Although data from goats was unavailable, over 1.7 million kilograms of sheep and lamb offal for human consumption was exported in 2009 (GHD, 2011). Recent research has shown a range of feral and native Australian animals infected with *L. serrata* nymphs (Shamsi et al., 2020; Barton et al., 2020a,b). As part of the ongoing project to determine the range of intermediate hosts of *L. serrata* in Australia, a number of feral goats were examined.

## 2. Materials and methods

Feral goats were collected from various locations across New South Wales (NSW) and South Australia (SA) between late 2020 and late 2021. The feral goats in NSW were all harvested and transported to the abattoir at Wodonga (northern Victoria) for slaughter: 5 from the Cooma region, 4 from the Cobar region, 5 from the Wilcannia region, and 9 from the Mudgee region. The 10 feral goats in SA were killed as part of the Southern Mallee goat control program and were processed on site. At the time of processing the carcasses, the hearts, lungs, livers and mesenteric lymph nodes were collected, bagged and frozen.

After defrosting, these organs were separated and individually processed. The heart was opened and the walls of the heart cut into approximately 5 mm slices; the heart was placed into a container of tap water and shaken vigorously, removed and examined for parasites; the washings were allowed to sediment, then the supernatant was poured off and the sediment examined under a dissecting microscope for parasites. The lungs and livers were processed as described in Barton et al. (2020a, b). The lymph nodes were processed as described in Shamsi et al. (2017) for cattle lymph nodes.

Any small pale masses in tissue and/or parasites found were collected and preserved in 70% ethanol. The pale masses of tissue were carefully dissected under a dissecting microscope and the contents placed in lactophenol on a slide for examination under a compound microscope at  $\times 40$  magnification.

Photos were taken using an eyepiece camera (AmScope AM900).

The collected specimen has been deposited in the Australian Museum (AM P.105551).

## 3. Results

A total of 33 feral goats were examined for parasites. Two small lumps were observed within a mesenteric lymph node from one of the Cooma goats. The lymph node was normal in appearance, with no discoloration or obvious calcification. No pentastomes were recovered from any other organs or from any other of the goats.

Dissection of the lumps found a single pentastomid nymph (Fig. 1). The nymph was damaged during dissection which prevented a total annulus count and gross body measurements; the sex of the nymph could not be determined. The nymph possessed dorsal accessory pieces associated with the hooks and spines along the posterior annulus edges, indicating that they were infective (as per Riley, 1986). Overall morphology (Table 1), in combination with location in host as well as host species, identified the nymph as *Linguatula* sp. Unfortunately, a genetic sample could not be obtained as the specimen had already been in lactophenol for a period of time (see Barton and Morgan, 2016), so confirmation of species was not possible.

## 4. Discussion

This is the first report of a feral goat as an intermediate host of a species of *Linguatula* in Australia. The overall morphology and history of

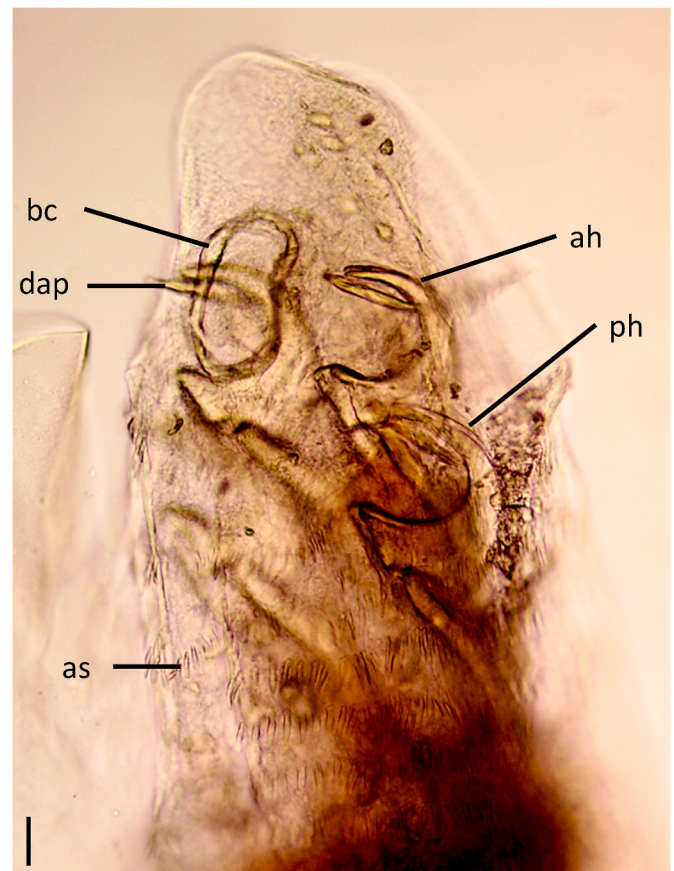


Fig. 1. Anterior end of infective nymph of *Linguatula* sp. removed from capsule within mesenteric lymph node of a feral goat examined in this study. Lateral view. Note capsule wall on left side of photograph. ah, anterior hook; as, annular spine; bc, buccal capsule; dap, dorsal accessory piece; ph, posterior hook. Scale bar 50  $\mu$ m.

Table 1

Morphological measurements of the nymph of *Linguatula* sp. collected from the lymph nodes of a feral goat, *Capra hircus*, in this study compared to measurements of nymphs of *Linguatula serrata* collected from other intermediate hosts in the same region. Measurements are in micrometers and presented as a mean with range in parentheses. Hook measurements follow the methodology of Barton et al. (2020a).

Host	<i>Capra hircus</i>	<i>Oryctolagus cuniculus</i>	<i>Notamacropus rufogriseus</i>
Reference	This study	Barton et al. (2020a)	Barton et al. (2020b)
No. of nymphs	1	11	6
Anterior hooks			
AC		159 (141–170)	158.8 (150–175)
AD		197 (193–202)	197.5 (185–220)
BC	145	130.2 (90–153)	141.5 (130–155)
CD	97	76.8 (66–93)	88 (80–100)
AB		93.5 (84–103)	85 (75–95)
DAP	120	139 (128–150)	109.2 (102.5–115)
Posterior hooks			
AC	180	164.8 (131–176)	161.7 (155–165)
AD	220	199.5 (188–210)	201.7 (190–210)
BC	148	134.7 (99–155)	140.6 (130–150)
CD	100	81.8 (56–106)	93.8 (85–115)
AB	100	90.8 (81–100)	89 (82–92.5)
DAP	120	134 (118–150)	111.9 (110–117.5)

*Linguatula* in Australia (see Shamsi et al., 2020) supports the identification to most likely be *L. serrata*; however, without molecular confirmation we are unable to provide a definitive identification of the species.

Unlike the nymphs collected from rabbits (Barton et al., 2020a) and red-necked wallabies (Barton et al., 2020b), this nymph was encased in a small hard pale envelope of tissue. Whether this is due to the species of host (ungulate versus lagomorph and macropod) or the location within the host (lymph node versus lung and liver) is unclear and further work should be undertaken on the development of nymphs within various host species to determine these developmental characteristics.

The collected nymph was infective, as defined by Riley (1986), with the “double hooks” and spined annuli (Fig. 1). Unfortunately, as the specimen was damaged during removal, the total number of annuli could not be determined. Annuli count can be used to identify nymphal pentastomes to species (Riley, 1986), however, the range of counts can vary significantly between specimens (see Barton et al., 2020b for example) and the usefulness of annuli counts for differentiating between species of *Linguatula* has not yet been fully determined. The measurements of the hooks, however, fell within the range of measurements previously reported for nymphs of *L. serrata* from other species of intermediate hosts in Australia (Barton et al., 2020a, 2020b). It is most likely that this specimen is *L. serrata*, but due to the damage to the specimen, which has prevented an overall morphological description, and the lack of molecular verification, we have erred on the side of caution by identifying the specimen as *Linguatula* sp.

Although widely occurring as intermediate hosts elsewhere in the world, goats (and sheep) appear to not have been considered as potential hosts in Australia, with most early records concentrating on cattle (see Pullar, 1936). There may be a number of reasons for this.

Firstly, the number of feral goats sent to abattoirs was small until recently (Pople and Froese, 2012), thus the meat inspectors at abattoirs were not “acquainted with the parasite” (Pullar, 1936, p. 63) as they were for cattle. Histological examination of mesenteric lymph nodes of cattle infected with *L. serrata* found that calcification of cysts was common (Shamsi et al., 2018). However, the cause of the lymphadenitis observed in cattle lymph nodes was often not differentiated (Shamsi et al., 2018). Nymphs of *L. serrata* have been shown to transmit bacteria as they migrate through their intermediate host (Hajimohammadi et al., 2017) and infected mesenteric lymph nodes in goats in Iran often had encapsulated abscesses (Tabaripour et al., 2017). It could be possible that the cause of some lymph node lesions seen in sheep and goats in Australia that cannot be determined (see McKenzie et al., 1979; Hein and Cargill, 1981), may be caused by *L. serrata*.

Secondly, modern post-mortem meat inspection procedures in Australian abattoirs were developed to detect zoonotic diseases of public health significance from the late 19th and early 20th Centuries (Dobrenov, 2011). This involved the visual and olfactory examination and palpation or incision of parts of carcass or organs to detect macroscopic abnormalities. However, many of these diseases of significance have now largely been eradicated or suppressed. Additionally, significant changes in animal husbandry and veterinary practices have altered transmission dynamics of many of these diseases. An example is caseous lymphadenitis, also known as cheesy gland, which is the dominant bacterial disease of sheep and goats (Hein and Cargill, 1981; McKenzie et al., 1979; Dobrenov, 2011). Since it has been found to not be a significant food safety concern, the incision of lymph nodes of sheep has been abandoned and replaced by observation and palpation (Dobrenov, 2011).

Thirdly, the majority of goats sent to slaughter at abattoirs are from the more arid areas of western NSW and South Australia (McKenzie et al., 1979; Hein and Cargill, 1981; Beveridge et al., 1987; Pople and Froese, 2012; Goat Industry Council of Australia, 2020). The majority of verified reports of infection with *L. serrata* have originated in the higher rainfall areas of the Great Dividing Range (Shamsi et al., 2017; Barton et al., 2020a, b). Thus, species of *Linguatula* may be absent from goats in hotter, drier regions because any eggs released from infected definitive hosts are rapidly desiccated under these conditions. However, there have been a number of unverified reports of both adult and nymphal *L. serrata* from areas outside of the Great Dividing Range (see Shamsi

et al., 2017, 2020; Barton et al., 2020a,b); more research needs to be undertaken on the distribution of *L. serrata* in both definitive and intermediate hosts to determine its true geographical distribution in Australia.

As with the previous reports of infection with *L. serrata* (Shamsi et al., 2017, 2020; Barton et al., 2020a, b), the goat in this study came from an area near Cooma, in the Kosciuszko Mountain region of the Great Dividing Range. Feral goat populations are widespread and expanding in Australia. Future studies need to determine the level of infection within goats from a larger sample size from the Cooma region and also whether this parasite exists in populations elsewhere.

Production animal offal products are commonly consumed by both people and pets (see GHD 2011). Halzoun or Marrara disease, caused by *L. serrata*, is a common problem throughout the Middle East, where raw or undercooked offal is commonly consumed (Fard et al., 2010; Eslami et al., 2018; Hajipour et al., 2019). As the consumption of goat meat and offal increases, both in Australia and of Australian product overseas, the potential risk of infection with *L. serrata* needs to be considered.

The life cycle of *L. serrata* is similar to that of taeniid cestodes, as reported by Jenkins et al. (2018). Adults are found in wild dogs and foxes primarily, with potential infections in domestic dogs if they have the opportunity to consume raw offal. Thus, although goat numbers in arid areas are generally lower where there are significant numbers of wild dogs, the climate and geography of the Great Dividing Range may allow for greater numbers of goats, despite the number of wild dogs (Jenkins et al., 2018). Transmission of *L. serrata* to goats, other wild introduced herbivores and macropod marsupials, therefore, may well be occurring at a high rate in that area.

A recent practice is to harvest of feral goats for the purpose of ‘re-domesticating’ and then referring to them as ‘rangeland’ goats (Pople and Froese, 2012). Although the majority of parasites (such as lice and nematodes) can be treated prior to the incorporation of these goats into domestic herds, infection with larval parasitic stages, such as taeniid metacestodes and *L. serrata* nymphs, are generally not able to be detected and treated. Thus, care needs to be taken in the release of previously unfrozen offal from these animals for consumption by humans and, particularly, domestic dogs.

This study has highlighted the importance of continued surveys of feral animals for infection with parasites, especially as the distribution of the feral animals’ changes.

## Funding

This research did not receive any specific grant from funding agencies in the public, commercial, or not-for-profit sectors.

## Declaration of competing interest

None.

## Acknowledgments

The authors are grateful to Dr Mick Shield and Dr Ian Wardelle (Wodonga Abattoir) for provision of material from New South Wales examined in this study. The authors are also grateful to the South Australia Department of Environment and Water and the Conservation and Wildlife Management Branch SA for allowing BS to attend the feral animal collection for samples. The authors thank Dr Krishna Roy (CSU) for assistance with dissections. The publication of this manuscript was funded by the Charles Sturt University Open Access Scheme.

## References

- Anon, 2011. The Feral Goat (*Capra hircus*). Department of Sustainability, Environment, Water, Population and Communities. Australian Government, Canberra, Australia.



- Barton, D.P., Baker, A., Porter, M., Zhu, X., Jenkins, D., Shamsi, S., 2020a. Verification of rabbits as intermediate hosts for *Linguatula serrata* (Pentastomida) in Australia. *Parasitol. Res.* 119, 1553–1562. <https://doi.org/10.1007/s00436-020-06670-y>.
- Barton, D.P., Morgan, J.A.T., 2016. A morphological and genetic description of pentastomid infective nymphs belonging to the family Sebekidae Sambon, 1922 in fish in Australian waters. *Folia Parasitol.* 63 <https://doi.org/10.14411/fp.2016.026>, 026.
- Barton, D.P., Porter, M., Baker, A., Zhu, X., Jenkins, D.J., Shamsi, S., 2020b. First report of nymphs of the introduced pentastomid, *Linguatula serrata*, in red-necked wallabies, *Notamacropus rufogriseus*, in Australia. *Aust. J. Zool.* 67, 106–113. <https://doi.org/10.1071/ZO20017>.
- Beveridge, I., Pullman, A.L., Henzell, R., Martin, R.R., 1987. Helminth parasites of feral goats in South Australia. *Aust. Vet. J.* 64, 111–112.
- Chief Veterinary Officers Unit, 2016. Review of Diseases and Pathogens of Invasive Animals that May Present Food Safety and Human Health Risks. Submission 214, Attachment 1 to the Parliamentary Inquiry into the Control of Invasive Animals on Crown Land. Victorian Government, p. 26.
- Dobrenov, B., 2011. Review of the Historical Basis of Post-mortem Meat Inspection Procedures in Australia. Final Report. Project A.RPB.0008. Meat and Livestock Australia Limited, North Sydney, 51 pp.
- Eslami, G., Khalatbari-Limaki, S., Oryan, A., Zohortabar, A., Amiri, A., Hajimohammadi, B., 2018. A survey on prevalence and molecular characteristics of *Linguatula serrata* isolated from slaughtered sheep and goat in Yazd slaughterhouse. *J. Vet. Res.* 72, 403–410. <https://doi.org/10.22059/jvr.2018.104493.2147> (In Persian, with English abstract).
- Fard, S.T.N., Kheirandish, R., Asl, E.N., Fathi, S., 2010. The prevalence of *Linguatula serrata* nymphs in goats slaughtered in Kerman slaughterhouse, Kerman, Iran. *Vet. Parasitol.* 171, 176–178. <https://doi.org/10.1016/j.vetpar.2010.03.010>.
- Fleming, P.J.S., 2004. Relationships between Feral Goats (*Capra hircus*) and Domestic Sheep (*Ovis aries*) with Reference to Exotic Disease Transmission. Unpublished PhD Thesis. University of Canberra, Canberra.
- GHD, 2011. Cost Benefits of E-Surveillance System for Animal Health Monitoring. Final Report. Project P.PIP.0196. Meat and Livestock Australia Limited, North Sydney, 73 pp.
- Goat Industry Council of Australia, 2015. Goatmeat and Livestock Industry Strategic Plan 2020, 16 pp. [www.gica.com.au](http://www.gica.com.au).
- Hajimohammadi, B., Eslami, G., Khalatbari-Limaki, S., Ehrampoush, M.H., Oryan, A., Zandi, H., Dehghan, H.R., 2017. The role of *Linguatula serrata* nymph in transmission of enteric bacterial pathogens to internal organs in sheep. *J. Parasit. Dis.* 41, 754–760. <https://doi.org/10.1007/s12639-017-0884-8>.
- Hajipour, N., Soltani, M., Mirshekar, F., 2019. Effect of age, sex, and season on the prevalence of *Linguatula serrata* infestation in mesenteric lymph nodes of goats slaughtered in Tabriz, Iran. *Trop. Anim. Health Prod.* 51, 879–885. <https://doi.org/10.1007/s11250-018-1768-3>.
- Hein, W.R., Cargill, C.F., 1981. An abattoir survey of diseases of feral goats. *Aust. Vet. J.* 57, 498–503.
- Jenkins, D.J., Cowled, B., Brookes, V., 2018. Taeniid metacestodes in rangeland goats in Australia. *Vet. Parasitol.* 255, 1–9. <https://doi.org/10.1016/j.vetpar.2018.03.012>.
- McKenzie, R.A., Green, P.E., Thornton, A.M., Blackall, P.J., 1979. Feral goats and infectious diseases: an abattoir survey. *Aust. Vet. J.* 55, 441–442.
- Pople, T., Froese, J., 2012. Distribution, Abundance and Harvesting of Feral Goats in the Australian Rangelands. Final Report to the ACRIS Management Committee. February 2012. Queensland Government.
- Pullar, E.M., 1936. A note on the occurrence of *Linguatula serrata* (Frohlich, 1789) in Australia. *Aust. Vet. J.* 61–64. April.
- Riley, J., 1986. The biology of pentastomids. *Adv. Parasitol.* 25, 45–128.
- Shamsi, S., Barton, D.P., Zhu, Z., Jenkins, D.J., 2020. Characterisation of the tongue worm, *Linguatula serrata* (pentastomida: linguatulidae), in Australia. *Int. J. Parasitol.: Parasites Wildl.* 11, 149–157. <https://doi.org/10.1016/j.ijppaw.2020.01.010>.
- Shamsi, S., Loukopoulos, P., McSpadden, K., Baker, S., Jenkins, D., 2018. Preliminary report of histopathology associated with infection with tongue worms in Australian dogs and cattle. *Parasitol. Int.* 67, 597–600. <https://doi.org/10.1016/j.parint.2018.05.011>.
- Shamsi, S., McSpadden, K., Baker, S., Jenkins, D.J., 2017. Occurrence of tongue worm, *Linguatula cf. serrata* (Pentastomida: linguatulidae) in wild canids and livestock in south-eastern Australia. *Int. J. Parasitol.: Parasites Wildl.* 6, 271–277. <https://doi.org/10.1016/j.ijppaw.2017.08.008>.
- Tabaripour, R., Fakhar, M., Alizadeh, A., Youssefi, M.R., Tabaripour, R., Teshnizi, S.H., Sharif, M., 2017. Prevalence and histopathological characteristics of *Linguatula serrata* infection among slaughtered ruminants in Mazandaran Province, northern Iran. *Comp. Clin. Pathol.* 26, 1259–1265. <https://doi.org/10.1007/s00580-017-2517-0>.