

# Clinical Outcomes After Cervical Transcorporeal Microdecompression and Vertebral Body Access Channel Repair

David W. Lowry, MD,<sup>1</sup> Scott M. Tuinstra, PA-C,<sup>1</sup> Kevin Liang Ph.D.,<sup>2</sup> Joseph A. Sclafani MD<sup>2</sup>

<sup>1</sup>The Brain and Spine Center, Holland, MI, USA <sup>2</sup>Milestone Research Organization, San Diego, CA

## Abstract

### Background

Although anterior cervical decompression and fusion (ACDF) can be performed using minimally invasive techniques, the extensive removal of anatomical keystones during decompression requires a segmental fusion to restore biomechanical stability. Treatment with arthrodesis techniques may result in a prolonged recovery time, loss of motion, and the need for further treatment if a pseudarthrosis or adjacent segment disease occur. Transcorporeal microdecompression (TCMD) is a newly developed motion sparing, minimally invasive anterior cervical spine decompression procedure that utilizes a small channel through the cervical vertebral body to decompress areas of central or foraminal stenosis while preserving the native disc. Cervical decompression with TCMD can be performed as a stand-alone or hybrid procedure with ACDF at the adjacent levels. This study retrospectively assesses patient based clinical outcome measures in patients treated with TCMD.

### Methods

A retrospective, non-randomized, single-center chart review of single surgeon experience with patients undergoing TCMD both with and without adjacent level ACDF using both a trajectory control guide and access channel repair. Statistical analyses were performed on pre and post-operative data collected using visual analog scale (VAS) and neck disability index (NDI) outcome measures.

### Results

Among 62 patients, there were no cases of neurovascular injury, CSF leak, transfusion, or migration of repair implement. Revision surgery was required in 6.4% (n=4) patients. A subanalysis of outcome metrics was performed for patients that underwent standalone TCMD (TCMD group, n=42) and TCMD with concurrent ACDF at one or more levels (TCMD+ACDF group, n=20). TCMD group NDI improved from 20.0 to 2.7 at 1 year ( $p = 0.0001$ ); Axial VAS improved from 5.5 to 0.6 ( $p = 0.0001$ ); and Radiating VAS improved from 7.0 to 0.7 ( $p = 0.0001$ ). TCMD+ACDF group NDI improved from 22.0 to 4.0 at 1 year ( $p = 0.004$ ); Axial VAS improved from 7.1 to 1.2 ( $p = 0.01$ ); and Radiating VAS trended towards significant improvement from 6.4 to 2.3 ( $p = 0.09$ ). Mean return to work was 10 days in the TCMD group and 57 days in the TCMD+ACDF group.

### Conclusions

Within the limits of a retrospective, single-surgeon study, patients did experience both functional improvement and pain relief as measured by NDI and VAS respectively from standalone TCMD or combined ACDF / TCMD procedures. Definitive statements on long-term efficacy, disc space preservation, and motion preservation await further study.

KEYWORDS: MINIMALLY INVASIVE SPINE SURGERY, MOTION PRESERVATION, CLINICAL OUTCOME, ANTERIOR CERVICAL DECOMPRESSION

VOLUME 9 ARTICLE 10 DOI: 10.14444/2010

## Introduction

Stenosis secondary to cervical spondylosis or an

acute focal cervical disc herniation can manifest clinically as a combination of axial neck pain, cervical radiculopathy and myelopathy.<sup>1</sup> There are two pur-

posed mechanisms to explain these clinical sequelae. First, mechanical compression of the exiting nerve root, either by a soft disc herniation or a disc-osteophyte complex, acts to increase the permeability of intrinsic nerve root blood vessels. This leads to nerve root edema, an increased neurologic response threshold, and ultimately an amplified sensitivity to pain signals.<sup>2,3</sup> Secondly, chemical mediators released from the pathologic disc fragment (bradykinin, serotonin, histamine, prostaglandins, leukotrienes) as well as from the compressed nerve root (substance P, somatostatin, VIP) provoke and perpetuate a dysregulated inflammatory response.<sup>4</sup> Surgical decompression of neurovascular structures is indicated if there is progressive neurologic decompensation or if non-operative modalities fail to adequately improve the patient's quality of life.

Anterior cervical decompression and fusion (ACDF) is a well-established procedure to treat severe degenerative conditions and focal disc herniation of the cervical spine.<sup>5-8</sup> Although ACDF can be performed using minimally invasive techniques, the extensive removal of anatomical keystones during decompression requires a segmental fusion to restore biomechanical stability. Treatment with arthrodesis techniques may result in a prolonged recovery time, loss of motion, and the need for further treatment if adjacent level disease or a pseudarthrosis develop.<sup>9</sup> Posterior decompression only techniques such as laminectomy or laminoplasty preserve the adjacent level and eliminate the risk of pseudarthrosis but increase the risk of post-operative instability or kyphotic deformity secondary to extensive dissection of the posterior cervical paraspinal musculature and often times does not adequately decompress anterior pathologies.<sup>10,11</sup>

Transcorporeal micro decompression (TCMD) is a newly developed motion sparing, minimally invasive cervical spine decompression procedure. TCMD utilizes an anterior approach to channel through the cervical vertebral body and access the disc pathology. This technique allows the surgeon to decompress areas of central or foraminal stenosis while preserving the native disc and posterior stabilizing musculature of the cervical spine. Cervical decompression with TCMD can be performed as a stand-alone or hybrid procedure with an ACDF at the adjacent levels. Pa-

tients presenting with cervical radiculopathy secondary to an isolated soft disc herniation are ideal candidates for standalone TCMD. Simultaneous TCMD with adjacent level ACDF is used to address symptomatic pathology such as a soft disc herniation with spondylotic myelopathy at other levels. This study retrospectively assesses perioperative outcomes as well as patient based clinical outcome measures after either a standalone TCMD, or TCMD with concomitant ACDF performed at the adjacent level.

## Methods

A retrospective, non-randomized, single-center chart review was conducted for a series of patients that underwent a standalone TCMD procedure using both a trajectory control guide and access channel repair (Beta-tricalcium phosphate + local autograft; TransCorp Spine, Byron Center, Michigan, USA), or TCMD with concomitant adjacent level ACDF. All procedures were performed by a single surgeon who had already overcome the initial procedural learning curve (DL). Following Institutional Review Board approval, pre-operative patient demographics (age, gender, BMI, diagnosis, previous spine surgeries, Visual Analog Scale (VAS) for axial neck and arm pain, Neck Disability Index (NDI) score, worker's compensation claim status, co-morbidities) were collected through the chart review. Operative and peri-operative data were obtained from available operative reports and hospital discharge summaries by an on-site research coordinator. Post-operative complication rate, VAS neck and arm pain score, NDI, time until return to employment and reoperation rate were also obtained through chart review. All data were electronically collected and patient information was de-identified prior to analysis by an independent clinical research organization.

Data were segmented for analysis based on age (<50 years versus ≥50 years), procedure (TCMD versus TCMD with adjacent level ACDF), gender, primary indication, number of operative levels, previous cervical surgery, pre-operative VAS and NDI, and co-morbidity. Data are reported as means ± SD. Statistical analyses were performed via either a one-way ANOVA or paired t-tests. Statistical analysis of com-

plication rate was performed using the chi-squared method with Yate's correlation. Significance is defined as  $p < 0.05$ .

## TCMD Procedure

After administration of a general anesthetic, the patient is positioned supine with a rolled towel under the interscapular region. The incision is made at a level which permits a direct line of site through the intended oblique trajectory of the guide, which is generally similar to where an incision would be placed if doing an ACDF one segment farther cranially. Once the spine is visualized and levels are confirmed fluoroscopically, the midline is marked at the disc space above and below the target vertebral body, and both midline in the sagittal plane and midplane in the axial plane are identified fluoroscopically, when possible given patient body habitus. The trajectory control device is then oriented with respect to midline and midplane, tamped into position on the anterior surface of the vertebral body, and then secured in position using a single anchoring pin. Positioning is confirmed fluoroscopically when possible. A hand operated drill with variable depth settings is used to penetrate the vertebral body in the desired trajectory to a depth of no more than 3 mm less than the AP diameter of the vertebral body at midplane as measured on pre-op studies. (The autograft from the hand drill is preserved for subsequent channel repair.) The trajectory is obliquely oriented caudally and laterally to permit access to the anterior aspect of the foramen while also preserving the uncovertebral joint. Hemostasis of the cancellous bone is achieved by passing a hemostatic agent through the trajectory control guide. After removal of the control guide, the last 3 mm of bone is removed using a high speed bur. The epidural plane is then entered in the superomedial quadrant of the access channel by first using a disc-shaped microdissector. The area of exposed dura is enlarged using Kerrison rongeurs. Osteophytes are removed using the burr and Kerrisons while herniated disc material is removed using standard microsurgical dissecting instruments. The adequacy of the decompression is verified both visually and by feel using a 90-degree ball tip dissector. The access channel is repaired by using a beta-tricalcium phosphate implant filled with the locally harvested auto-

graft preserved from the hand drill (Figure 1, Figure 2). Prior to placing the implant, a reamer is used to prepare the channel. After fluoroscopically verifying implant positioning and achieving hemostasis, the incision is closed.

## Results

Sixty-two patients (22 female, 40 male) with a mean age of 50.6 years (range: 30-71 years) at the time of surgery were included in the study. The primary surgical indications were degenerative disc disease with stenosis (DDD,  $n=37/62$ , 60%), or acute disc herniation (HNP,  $n=25/62$ , 40%). Five patients had undergone previous cervical spine surgery (2 anterior cervical fusion, 3 posterior decompression). Zero patients were treated under pending litigation or a Worker's Compensation claim. A standalone TCMD

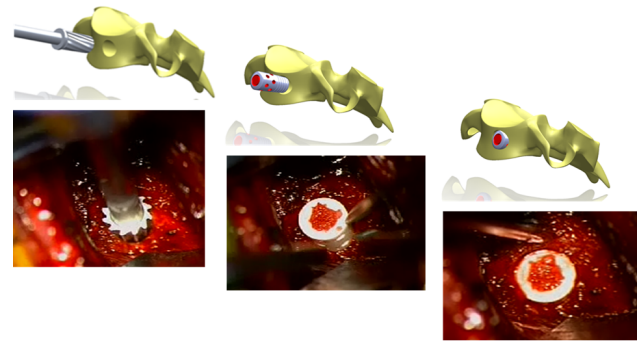


Fig. 1. Illustration of the stepwise process of a channel repair implant that is filled with beta-tricalcium phosphate and local autograft.

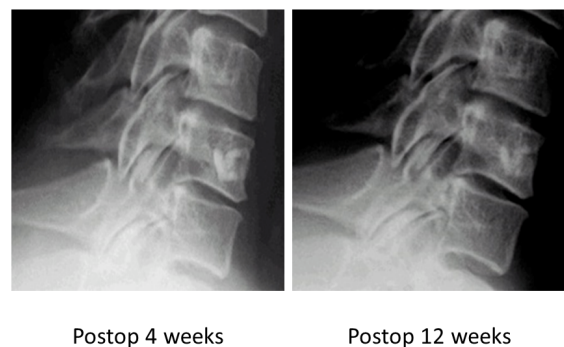


Fig. 2. Access channel demonstrates ossification at 12 weeks postoperation.

was performed in 42/62 patients and 20/62 patients underwent a combined TCMD with adjacent level anterior cervical discectomy and fusion procedure (TCMD + ACDF) at one or more levels (Table 1).

Median hospital admission time was 1 day (range 0-3 days) in the TCMD + ACDF group and 1 day (range 0-2 days) in the standalone TCMD group. Forty-three percent (18/42) of standalone TCMD patients were discharged home on the day of surgery. Zero patients required a peri-operative blood transfusion and there were no cases of neurovascular injury, CSF leak, or migration of repair implement reported within 90 days of operation. However, revision surgery was required in 6.4% (n=4/62) patients during the follow up period. Revision rate was not significantly higher in the standalone TCMD group (n=2/42) than in the TCMD + ACDF group (n=2/18,  $\chi^2$  p>0.05). Mean return to work duration was shorter in the TCMD group (10 days, n=42, p=0.0001) than in the TCMD + ACDF group (59 days, n=12) (Figure 3).

TCMD group NDI improved from  $20.0 \pm 10.4$  to  $6.5 \pm 8.1$  at 1 month (n=41, p = 0.0001); Axial VAS improved from  $5.5 \pm 3.1$  to  $1.6 \pm 2.1$  (n=42, p = 0.0001); and Radiating VAS improved from  $7.0 \pm 2.4$  to  $1.2 \pm 2.0$  (n=41, p = 0.0001). At 1 year post-op, the TCMD group NDI improved from  $20.0 \pm 10.4$  to  $2.7 \pm 3.9$  (n=22, p = 0.0001); Axial VAS improved from  $5.5 \pm 3.1$  to  $0.6 \pm 0.8$  (n=22, p = 0.0001); and Radiating VAS improved from  $7.0 \pm 2.4$  to  $0.7 \pm 1.4$  (n=22, p = 0.0001). The TCMD + ACDF group NDI improved from  $22.0 \pm 11$  to  $15.3 \pm 9.3$  at 1 month (n=18, p =

0.05); Axial VAS improved from  $7.1 \pm 2.1$  to  $2.4 \pm 2.1$  (n=18, p = 0.0001); and Radiating VAS improved from  $6.4 \pm 2.9$  to  $2.3 \pm 2.2$  (n=18, p = 0.0001). At one year post-op, the TCMD + ACDF group NDI improved from  $22.0 \pm 11$  to  $4.0 \pm 3.5$  (n=7, p = 0.004); Axial VAS improved from  $7.1 \pm 2.1$  to  $1.2 \pm 1.0$  (n=7, p = 0.01); and Radiating VAS trended towards significant improvement from  $6.4 \pm 2.9$  to  $2.3 \pm 3.2$  (n=7, p = 0.09) (Table 2). There was not a significant difference in outcome measures between groups when the data was stratified based on patient age, sex, number of levels treated and specific level treated (p>0.05).

Percent Returned to Work by Post-Op Day

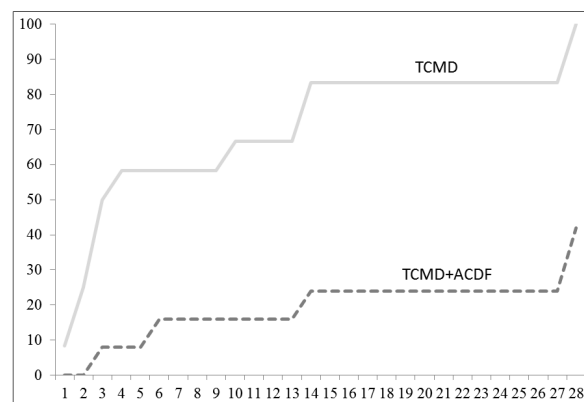


Fig. 3. Mean return to work duration was shorter in the TCMD than in the TCMD + ACDF group. All patients in the TCMD group returned to work by post-op day 60 and all patients in the TCMD + ACDF group returned to work by post-op day 120.

Table 2. Patient based outcome measures for the standalone TCMD group and TCMD + ACDF group.

TCMD	Preoperation	1 year postoperation	Paired t-test (p)
NDI	$20 \pm 10.4$ (n = 41)	$2.7 \pm 2.9$ (n = 22)	0.0001
VAS Neck	$5.5 \pm 3.1$ (n = 42)	$0.6 \pm 0.8$ (n = 22)	0.0001
VAS Arm	$7.0 \pm 2.4$ (n = 41)	$0.7 \pm 1.4$ (n = 22)	0.0001
TMCD + ACDF	Preoperation	1 year postoperation	Paired t-test (p)
NDI	$22 \pm 11$ (n = 18)	$4.0 \pm 3.5$ (n = 7)	0.004
VAS Neck	$7.1 \pm 2.1$ (n = 18)	$1.2 \pm 1.0$ (n = 7)	0.01
VAS Arm	$6.4 \pm 2.9$ (n = 18)	$2.3 \pm 3.2$ (n = 7)	0.09

Table 1. Patient demographics.

	n
Total patients	62
Mean age at surgery (years)	50.6
<b>Diagnosis</b>	
Degenerative Disc Disease with Stenosis	37
Acute Disc Herniation	25
<b>Procedure</b>	
Standalone TCMD	42
TCMD + ACDF procedure	20

## Discussion

Within the limits of a single center retrospective review, the results of this study demonstrate that TCMD is a safe and effective minimally invasive surgical option to treat cervical spondylosis with radiculopathy or acute cervical disc herniation. There were no major complications reported and no cases that required a peri-operative blood transfusion. Overall length of hospital stay compares favorably to previous studies of cervical decompression procedures.<sup>12,13</sup>

Patients in the standalone TCMD group were able to achieve a level of function necessary to return to work significantly faster than those treated with TCMD + ACDF. However, both standalone TCMD as well as TCMD with concomitant adjacent level ACDF groups reported significant improvement in pain scores and functional outcome as early as one month post-op that continued until the 1 year post-operative clinical follow up visit.

There are several advantages to implementing a transcorporeal microdecompression with concomitant adjacent level ACDF over a multilevel cervical fusion in cases of severe multilevel deformity. TCMD eliminates the risks of postoperative instrumentation failure or pseudoarthrosis at the TCMD level and requires a less extensive dissection than ACDF to reach the surgical target. Additionally, limiting the extension of arthrodesis preserves an additional native motion segment which can protect against adjacent level degenerative changes. Prasarn et al. conducted one of the few studies in the literature on adjacent level biomechanics after single versus multilevel cervical spine fusion.<sup>14</sup> These authors demonstrated that extension of a single level fusion to a two-level fusion in a cadaveric model system increased sagittal range of motion and stress forces at the motion segment adjacent to the arthrodesis. In light of these findings, performing a motion preserving TCMD procedure together with ACDF in cases of multilevel pathology will likely reduce the rate of adjacent level hypermobility and accelerated degeneration.

While motion was preserved at the one year post-op mark for all patients who have reached that point, a

limitation of our study is that long-term efficacy, disc space maintenance and motion preservation were not studied. Several previous studies have confirmed that arthrodesis of a cervical motion segment leads to increased stress, load, and intradiscal pressures at the level adjacent to the fusion construct.<sup>15-19</sup> Such forces likely accelerate degenerative changes in levels adjacent to arthrodesis which could lead to clinical deterioration necessitating further intervention. Hiltbrand and Robbins followed 374 patients over a period of 10 years after ACDF and found that symptomatic adjacent level disease developed at a rate of 2.9% per year.<sup>20</sup> Anterior transcorporeal decompression techniques are designed to remove anterior pathologic compressive fragments while limiting disruption of the native disc and bony stabilizers of the cervical spine.<sup>21</sup> The clinical impact of preserving the native anatomical architecture during TCMD procedures should be investigated in future dedicated studies of long term functional and radiographic outcomes. Future studies will also compare the clinical outcome of standalone TCMD versus standalone ACDF procedures to better appreciate the best indications for each respective procedure.

## References

1. Rao R. Neck Pain, Cervical Radiculopathy, and Cervical Myelopathy Pathophysiology, Natural History, and Clinical Evaluation. *J Bone Joint Surg Am.* 2002;84(10):1872-1881.
2. Cooper RG, Freemont AJ, Hoyland JA, Jenkins JP, West CG, Illingworth KJ, Jayson MI. Herniated intervertebral disc-associated periradicular fibrosis and vascular abnormalities occur without inflammatory cell infiltration. *Spine.* 1995;20:591-8.
3. Humphreys SC, Hodges SD, Patwardhan A, Eck JC, Covington LA, Sartori M. The natural history of the cervical foramen in symptomatic and asymptomatic individuals aged 20–60 years as measured by magnetic resonance imaging. A descriptive approach. *Spine.* 1998; 23:2180–2184.
4. Chabot MC, Montgomery DM. The pathophysiology of axial and radicular neck pain. *Semin Spine Surg.* 1995;7:2-8.
5. Cloward RB. The anterior approach for removal of ruptured cervical disks. *J Neurosurg.* 1958;

15:602–617.

6. Kaiser MG, Haid RWJ, Subach BR, Barnes B, Rodts GEJ. Anterior cervical plating enhances arthrodesis after discectomy and fusion with cortical allograft. *Neurosurgery*. 2002;50:229–236.
7. Robinson RA, Smith GW. Antero-lateral cervical disc removal and interbody fusion for cervical disc syndrome. *Bull Johns Hopkins Hosp*. 1955; 96:223–224.
8. Wang JC, McDonough PW, Endow K, Delamarter, RB. Increased fusion rates with cervical plating for two-level anterior cervical discectomy and fusion. *Spine*. 2000;25:41–45.
9. Yonenobu Y, Cervical radiculopathy and myelopathy: when and what can surgery contribute to treatment? *Eur Spine J*. 2000; 9: 1–7.
10. Longstein J. Post-Laminectomy kyphosis spinal deformities and neurologic dysfunction. New York, Raven Press. 1978; 53–63.
11. Sim FH, Suijen HJ, Bickel WH, Janes JM. Swan neck deformity following extensive cervical laminectomy. *J Bone Joint Surgery*. 1974; 56A:564–580.
12. Stieber JR, Brown K, Donald GD, Cohen JD. Anterior cervical decompression and fusion with plate fixation as an outpatient procedure. *The Spine Journal*. 2005; 5(5), 503–507.
13. Fessler RG, Khoo LT. Minimally invasive cervical microendoscopic foraminotomy: an initial clinical experience. *Neurosurgery*. 2002; 51(5), S2–37.
14. Prasarn ML, Baria D, Milne E, Latta L, Sukovich W. Adjacent-level biomechanics after single versus multilevel cervical spine fusion. *Laboratory investigation. J Neurosurg Spine*. 2012; 16:172–177.
15. Ren C, Song Y, Xue Y, Yang X. Mid- to long-term outcomes after cervical disc arthroplasty compared with anterior discectomy and fusion: a systematic review and meta-analysis of randomized controlled trials. *European Spine Journal*. 2014; 23:5, 1115–1123.
16. Kramer J, Javidan Y, Smith J. The value of disk replacement?. *Seminars in Spine Surgery*. 2014; 26:1, 45–51.
17. Sundseth J, Jacobsen EA, Kolstad F, Nygaard

OP, Zwart JA, Hol PK. Magnetic resonance imaging evaluation after implantation of a titanium cervical disc prosthesis: a comparison of 1.5 and 3 Tesla magnet strength. *European Spine Journal*. 2013; 22:10, 2296–2302.

18. Zigler JE, Delamarter R, Murrey D, Spivak J, Janssen M. ProDisc-C and Anterior Cervical Discectomy and Fusion as Surgical Treatment for Single-Level Cervical Symptomatic Degenerative Disc Disease. *Spine*. 2013; 38:3, 203–209.
19. Coric D, Kim PK, Clemente JD, Boltes MO, Nussbaum M, James S. Prospective randomized study of cervical arthroplasty and anterior cervical discectomy and fusion with long-term follow-up: results in 74 patients from a single site. *Journal of Neurosurgery: Spine*. 2013;18:1, 36–42.
20. Hilibrand AS, Robbins M: Adjacent segment degeneration and adjacent segment disease: the consequence of spinal fusion?. *Spine J 6 Suppl*. 2004; 4:190S–1944S.
21. Choi G, Lee SH, Bhanot A, Chae YS, Jung B, Lee S. Modified transcorporeal anterior cervical microforaminotomy for cervical radiculopathy: a technical note and early results. *European Spine Journal*. 2007; 16(9), 1387–1393.

## Corresponding Author

Joseph Sclafani, Milestone Research Organization, San Diego, CA. [jsclafani@milestonecro.com](mailto:jsclafani@milestonecro.com)

## Disclosures

Conflicts of Interest and Source of Funding: Milestone Research Organization was hired as the clinical research organization to conduct the study. This entity was compensated to conduct the study, analyze results and author the manuscript.

Published 30 March 2015.

This manuscript is generously published free of charge by ISASS, the International Society for the Advancement of Spine Surgery. Copyright © 2015 ISASS. To see more or order reprints or permissions, see <http://ijssurgery.com>.