

Dislocation of polyfocal full-optics accommodative intraocular lens after neodymium-doped yttrium aluminum garnet capsulotomy in vitrectomized eye

Kyung Tae Kang, Yu Cheol Kim

We report a case of dislocation of WIOL-CF[®] polyfocal full-optics intraocular lens (IOL) after neodymium-doped yttrium aluminum garnet (Nd: YAG) laser capsulotomy in the vitrectomized eye. At 22 months before the dislocation of the IOL, a 55-year-old male patient underwent phacoemulsification with WIOL-CF[®] IOL implantation in a local clinic and 10 months after the cataract surgery the patient underwent pars plana vitrectomy, endolaser photocoagulation and 14% C₃F₈ gas tamponade for the treatment

of rhegmatogenous retinal detachment. At 9 months after the vitrectomy, the patient visited our clinic for a sudden decrease of vision after Nd: YAG capsulotomy in the local clinic. On fundus examination, the dislocated IOL was identified and the Nd: YAG capsulotomy site and the larger break, which is suspected to have been a route of the dislocation were observed in the posterior capsule.

Key words: Dislocation, neodymium-doped yttrium aluminum garnet capsulotomy, polyfocal full-optics intraocular lens

In recent years, the implantation of multifocal intraocular lens (IOL) or accommodative IOL is getting popular to correct presbyopia as well as cataracts in cataract surgery. Among accommodative IOLs, WIOL-CF[®] (Gelmed International, Kamenne Zehrovice, Czech Republic) is a polyfocal full-optics IOL made of hydrogel (Wi-GEL) and can induce refractive changes by the contraction and changes of the ciliary body and elevated pressure in the vitreous cavity during near gaze.^[1] WIOL-CF[®] is entirely composed of a 9.0 mm - sized optic without haptic [Fig. 1]^[1] and this unique structure does not allow adhesion between anterior and posterior capsules, which may reduce the after-cataract incidence, but increase the risk of IOL dislocation when the capsular bag is damaged.^[2,3]

Therefore, the authors report a case of WIOL-CF[®] IOL dislocation after neodymium-doped yttrium aluminum garnet (Nd: YAG) capsulotomy in a vitrectomized eye.

Case Report

A 55-year-old male patient visited our clinic for the chief complaint of sudden-onset vision decrease after Nd: YAG capsulotomy in a local clinic. At the time of admission, the uncorrected visual acuity was 20/1000 and the intraocular pressure was 15 mm Hg.

At 22 months before the dislocation of the IOL, the patient underwent uneventful phacoemulsification with WIOL-CF[®] IOL implantation in the local clinic and 10 months after the cataract surgery, the patient was transferred to our clinic for the

Access this article online	
Quick Response Code:	Website: www.ijo.in
	DOI: 10.4103/0301-4738.119335

Department of Ophthalmology, School of Medicine, Dongsan Medical Center, Keimyung University, Daegu, Korea

Correspondence to: Dr. Yu Cheol Kim, Department of Ophthalmology, School of Medicine, Dongsan Medical Center, Keimyung University, #56, Dalseong-ro, Jung-gu, Daegu 700-712, Korea. E-mail: eyedr@dsmc.or.kr

Manuscript received: 20.08.12; **Revision accepted:** 15.07.13

treatment of rhegmatogenous retinal detachment (RRD) with 3 disc diameter-sized horseshoe tear located at 12 o'clock. Patient underwent pars plana vitrectomy, endolaser photocoagulation and 14% C_3F_8 gas tamponade and recovered the vision up to 20/20 of the best corrected visual acuity (BCVA) with well-attached retina, 3 months after the RRD surgery.

At 9 months after RRD surgery, the BCVA decreased to 20/25 and in the slit lamp examination, the inferonasal continuous curvilinear capsulorhexis (CCC) margin was dragged superotemporally and anterior capsule was folded. However, the IOL was not subluxated and definite signs of damaged posterior capsule or zonules were not identified [Fig. 2]. At 2 days later, the patient visited our clinic after Nd: YAG posterior capsulotomy in the local clinic and in fundus examination, the dislocated IOL was identified [Fig. 3]. Slit lamp examination revealed the ovoid Nd: YAG capsulotomy site and the larger linear break, which is the suspected route of the IOL dislocation, in the posterior capsule [Fig. 4].

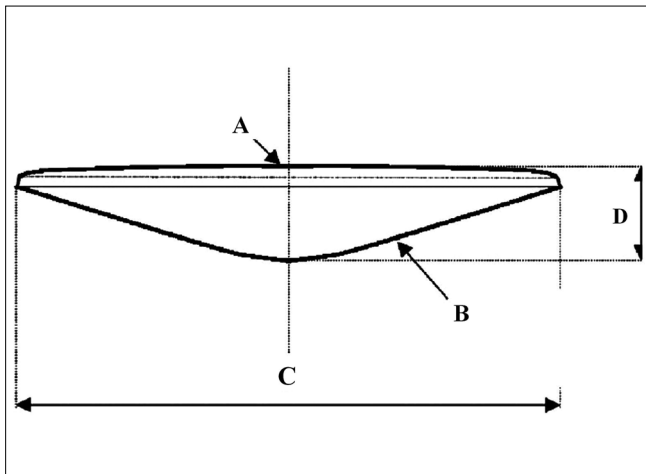


Figure 1: The design of WIOL-CF[®] polyfocal full-optics accommodative intraocular lens. A = meniscoid anterior surface, B = hyperboloid surface contacting posterior capsule, C = optic diameter 8.6-9.0 mm, D = central thickness 1.1-1.4 mm

Discussion

One of the popular methods that improve near and intermediate vision as well as far vision in cataract surgery is implanting an accommodative IOL. WIOL-CF[®] is very similar to human crystalline lens in shape and so the entire lens capsule is in contact with IOL optic. This IOL is only made up of optics and does not have haptics or positioning holes, which are used to fixate the lens to the capsular bag and is remarkably thick resembling human crystalline lens. Although the absence of adhesion between anterior and posterior capsules may cause positional instability of IOLs, WIOL-CF[®] IOL adheres to the lens capsule instead of inter-capsular adhesion.^[4] Through the adhesion between IOL surface and lens capsule, the contraction force of ciliary body can be transferred to IOL and the IOL then moves and changes, giving accommodative power for near vision. Therefore, sufficient near vision is acquired not just after the operation, but after the adhesion between IOL surface and lens capsule.^[1] Nevertheless the current case shows that

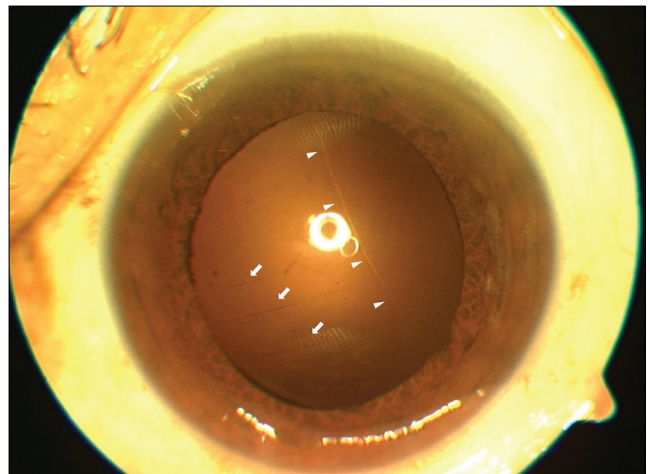


Figure 2: Slit lamp photograph shows superotemporally dragged continuous curvilinear capsulorhexis margin (arrow head) and folded inferonasal anterior capsule (arrow) with the well centered intraocular lens

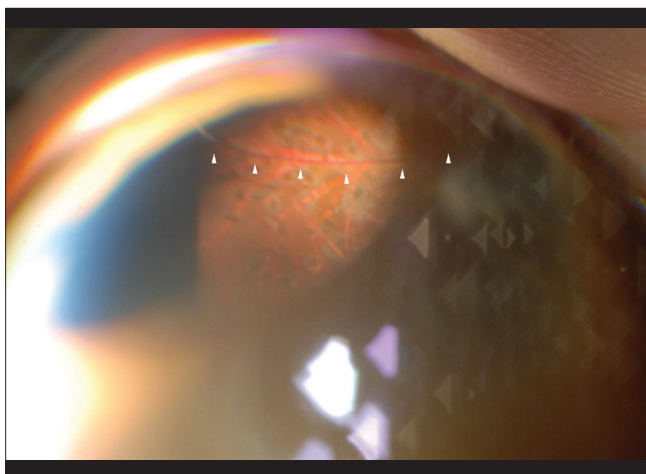


Figure 3: Fundus examination using 90 D lens shows the dislocated intraocular lens (arrow head) at the bottom

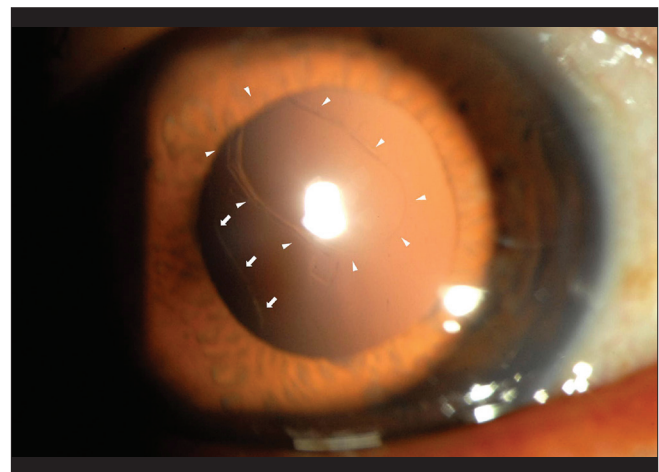


Figure 4: Slit lamp photograph shows neodymium-doped yttrium aluminum garnet capsulotomy site at the posterior capsule (arrow head) and a linear posterior capsular rupture (arrow) at inferotemporal, which is presumed to be a route of intraocular lens dislocation

the adhesion between IOL optic surface and capsule is not sufficient for the positional stability of IOL. To the best of our knowledge, few or no histological studies describing the relationship between lens capsule and WIOL-CF[®] have been reported yet.

In the current case, the patient has two breaks in the posterior capsule. The IOL was not assumed to be dislocated through the Nd: YAG capsulotomy site, but it is plausible that the mechanical force by Nd: YAG capsulotomy tore the existing break or weak point in the inferior capsule and the IOL was then dislocated through the inferior larger break. The slit lamp examination at 2 days before Nd: YAG capsulotomy showed the superotemporally dragged CCC margin, which implied that undetectable breaks or stretched capsule existed in the inferior capsular bag, which corresponded with the inferior larger break suspected the passage of IOL dislocation.

There are several possible explanations about the existing break or weak portion in capsule. WIOL-CF[®] IOLs are possibly heavier than other conventional IOLs and the stress of IOL to capsule might become greater after the loss of vitreous that had acted as cushion against the weight of IOL. It was also possible that a tiny iatrogenic tear in the capsule, which had been made during the vitrectomy expanded with the weight of IOL.^[5]

If the pressure change of vitreous cavity is essential for the accommodative power in WIOL-CF[®], it is assumed that WIOL-CF[®] IOL in vitrectomized eye is not able to induce sufficient accommodation.^[6] It is regrettable not to have checked the accommodative power in this case. Sparing the vitreous around the lens during vitrectomy is presumed to be an option in WIOL-CF[®] implanted eyes to preserve the accommodative power and reduce the risk of IOL dislocation.

In the authors' experience, although the chances may be lower than in conventional IOL, after-cataract can also develop in WIOL-CF[®] implanted eyes. Due to the lack of firm adhesion between anterior and posterior capsule, Nd: YAG capsulotomy for the treatment of after-cataract may induce WIOL-CF[®] IOL posterior dislocation more often than conventional IOL. Capsular bag fixation of conventional IOLs with C-loop haptics is secured through adhesion between anterior and posterior capsule around haptics. In plate-haptic IOLs, fixation holes within IOL allow ingrowth of lens epithelial cells and fibrosis to ensure synechia. Since plate-haptic IOLs with no-hole or small-holes have no structural elements that allow this synechia, they do not have firm fixation of the IOL within the capsular bag, similar to WIOL-CF[®] IOL. Therefore, no-hole or small-hole plate IOLs are susceptible to decentration or dislocation after

procedure of Nd: YAG capsulotomy for after-cataract.^[7] In order to enhance capsular fixation, enlarging fixation holes in the loop has been used, so more fibrosis through the holes take place. Since WIOL-CF[®] IOL is remarkably thicker than that of conventional IOL; making peripheral fixation holes within the lens would not work to induce fibrosis. Thus, the authors urge that the lens require other contrivance to give more stability in the capsular bag in case capsular bag become instable after Nd: YAG capsulotomy.

Conclusion

Pars plana vitrectomy and Nd: YAG capsulotomy in WIOL-CF[®] implanted eyes have probably a very high risk of IOL dislocation. Further studies about the stability of WIOL-CF[®] in vitrectomized eyes, the treatment of after-cataract in WIOL-CF[®] implanted eyes and the changes of accommodative power in vitrectomized eyes are needed and histological evaluation of between capsular bag and WIOL-CF[®] will be helpful to understand the stability of the IOL implantation.

References

1. Kim HJ, Seo JW, Shin SJ, Chung SK. Visual outcome and stability of hydrogel full-optics accommodative intraocular lens. *J Korean Ophthalmol Soc* 2011;52:1448.
2. Liu CS, Wormstone IM, Duncan G, Marcantonio JM, Webb SF, Davies PD. A study of human lens cell growth *in vitro*. A model for posterior capsule opacification. *Invest Ophthalmol Vis Sci* 1996;37:906-14.
3. Ishibashi T, Hatae T, Inomata H. Collagen types in human posterior capsule opacification. *J Cataract Refract Surg* 1994;20:643-6.
4. Nagamoto T, Tanaka N, Fujiwara T. Inhibition of posterior capsule opacification by a capsular adhesion-preventing ring. *Arch Ophthalmol* 2009;127:471-4.
5. Framme C, Hoerauf H, Roeder J, Laqua H. Delayed intraocular lens dislocation after neodymium: YAG capsulotomy. *J Cataract Refract Surg* 1998;24:1541-3.
6. Nguyen NX, Seitz B, Reese S, Langenbacher A, Kuchle M. Accommodation after Nd: YAG capsulotomy in patients with accommodative posterior chamber lens 1CU. *Graefes Arch Clin Exp Ophthalmol* 2005;243:120-6.
7. Mamalis N, Omar O, Veiga J, Tanner D, Pirayesh A, Fernquist DS. Comparison of two plate-haptic intraocular lenses in a rabbit model. *J Cataract Refract Surg* 1996;22 Suppl 2:1291-5.

Cite this article as: Kang KT, Kim YC. Dislocation of polyfocal full-optics accommodative intraocular lens after neodymium-doped yttrium aluminum garnet capsulotomy in vitrectomized eye. *Indian J Ophthalmol* 2013;61:678-80.

Source of Support: Nil. **Conflict of Interest:** None declared.