

ACCIDENTAL INTRAOPERATIVE FINDING OF PARASITIC FIBROIDS IN THE MESENTERY OF A MIDDLE-AGED WOMAN

A.O. Bankole¹, R.A. Abdus-Salam², A.J. Fakoya³, O.O. Adegoke⁴, I.O. Morhason-Bello^{2,5}

1. Department of Obstetrics and Gynaecology, University College Hospital, Ibadan, Nigeria.
2. Department of Obstetrics and Gynaecology, College of Medicine, University of Ibadan/University College Hospital, Ibadan, Nigeria.
3. Department of Surgery, University College Hospital, Ibadan, Nigeria.
4. Department of Pathology, University College Hospital, Ibadan, Nigeria.
5. Institute for Advanced Medical Research and Training, College of Medicine, University of Ibadan, Ibadan, Nigeria.

Correspondence:

Dr. Imran O. Morhason-Bello

Dept of Obstetrics and Gynaecology,
Faculty of Clinical Sciences,
College of Medicine,
University of Ibadan,
Ibadan, Oyo State,
Nigeria.

Email: imranmorhasonbello@gmail.com

ABSTRACT

Fibroid (myoma) is the most common benign tumor of the female genital tract. The tumour may occur in the uterine corpus as intramural, submucous, subserous, cervical fibroid; or in the broad ligament as intraligamentary fibroid or outside of uterus as parasitic fibroid. Parasitic fibroid is rare as a primary or secondary tumour. It is commonly diagnosed as an incidental finding during radiologic or abdominal surgical procedures.

This was a case report of histologically confirmed multiple parasitic fibroids in a 39-year-old woman coexisting with primary uterine fibroids. The woman presented with a history of progressive abdominal swelling and associated lower abdominal pain of 8 years duration. There was an antecedent history of exploratory laparotomy with excision of uterine mass.

Abdominal ultrasonography revealed multiple uterine fibroid nodules in the submucous, intramural and subserous layers of the uterus with bilateral normal ovaries. She had abdominal myomectomy. The intraoperative findings revealed multiple uterine fibroid nodules with a total weight of 1670g. There were multiple parasitic fibroid nodules attached to the serosa of the colon with the largest measuring 3.5 x 2cm.

We discussed the management and associated challenges of unanticipated parasitic fibroids at surgery. We highlighted the role of multi-disciplinary care and advocated for a high index of suspicion while preparing for surgical intervention in women with multiple uterine fibroids.

Keywords: Uterine fibroids, Myoma, Fibroid location, Parasitic fibroid

INTRODUCTION

Uterine leiomyoma is the commonest benign tumour of the female genital tract consisting of uterine smooth muscle cells with varying amount of fibrous connective tissues. Although the real aetiology of uterine fibroids is unknown, the tumour is associated with several epidemiological risk factors. Some of the risk factors associated with uterine fibroids include age above 35 years, low parity, obesity, being of black race, genetic factors, familial factors, and nutrients low in vitamin D amongst others.¹ The exact incidence or prevalence of fibroids is difficult to determine. Studies have reported an incidence rate of 190 per 100,000 to 270 per 100,000 women years in different populations.¹ Uterine fibroid was reported in 50-80% of pathological or postmortem specimens.^{2,3} Generally, uterine fibroids is asymptomatic, mostly diagnosed

accidentally during ultrasound; and only 20-50% become symptomatic.²

Generally, fibroids are classified based on their location within the uterus. They may be submucous, intramural, sub-serous, inter-ligamentous, cervical and parasitic.³ Parasitic or ectopic fibroids are rare intra-abdominal tumour usually with the same histological features with uterine fibroids.² In general, parasitic fibroids usually arise as projections from sub-serosal part of uterine fibroids. Afterwards, the growth rate of the serosal projections of these fibroids supersedes the primary vascular supply from the uterus leading to atrophy of the uterine myoma junction and subsequent detachment. During this period, the outgrown tumour

will latch on the adjacent mesenteric vessels for its new blood supply.

We present a case of parasitic fibroids coexisting with uterine fibroids that was accidentally discovered during surgery in a middle-aged woman.

CASE REPORT

A 39-year-old woman, Para 1⁺¹ (1 Alive) presented with a history of progressive abdominal swelling and associated lower abdominal pain of 8 years duration. This was associated with menorrhagia and passage of blood clots which worsened 2 months before presentation.. Menorrhagia was severe and she was transfused with 6 units of blood at a private healthcare facility. There was a previous history of exploratory laparotomy and Caesarean delivery in 2013.

On physical examination, she was conscious and not in pain. She was not pale, anicteric, afebrile, not dehydrated and had no pedal oedema. The abdomen was distended and there was a midline scar. There was 28 -week sized abdomino-pelvic mass non-tender, had an irregular surface and freely mobile. There was no demonstrable ascites. A speculum vaginal examination revealed a healthy-looking vulva, vagina and cervix. On digital vaginal examination, the vaginal mucosa was normal, both adnexae were free and non-tender and the pouch of Douglas was flat.

Abdominal ultrasonography showed multiple uterine fibroid nodules in the submucous, intramural and

subserous layers of the uterus with bilateral normal ovaries. A diagnosis of symptomatic uterine fibroid was made. The blood chemistry analysis, urinalysis, complete blood count and clotting profile were within the normal limits. The patient was counselled for abdominal myomectomy because she was desirous of pregnancy in the future. The patient had bowel preparation because of two previous abdominal surgeries and anticipation for possible bowel adhesions. The general surgical team was invited to co-manage the patient because of the possibility of extensive intraabdominal adhesions from previous surgeries.

The intraoperative findings at laparotomy via a midline incision included dense intraperitoneal adhesions between the colon, omentum and the posterior wall of the uterus; multiple uterine fibroid nodules with a total weight of 1670g; additional three greyish white fibroid nodules on the serosa of the transverse colon were separated from the uterus with the largest measuring 3.5 x 2.0cm (see Figure 1a, 1b and 2). The patient had laparotomy, adhesiolysis, myomectomy, and excision of the parasitic nodule on the colon. The estimated blood loss was 1.2 litres and two units of crossmatched blood were transfused intraoperatively.

The patient was managed with intravenous infusion (normal saline and dextrose saline), analgesics and antibiotic management in the postoperative period. The post-operative period was uneventful and recovery was satisfactory. The clinical condition was satisfactory at the six weeks follow-up visit.

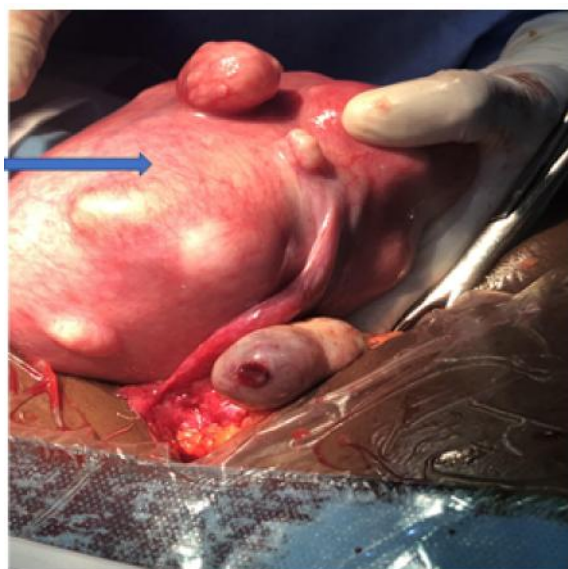

Figure 1a

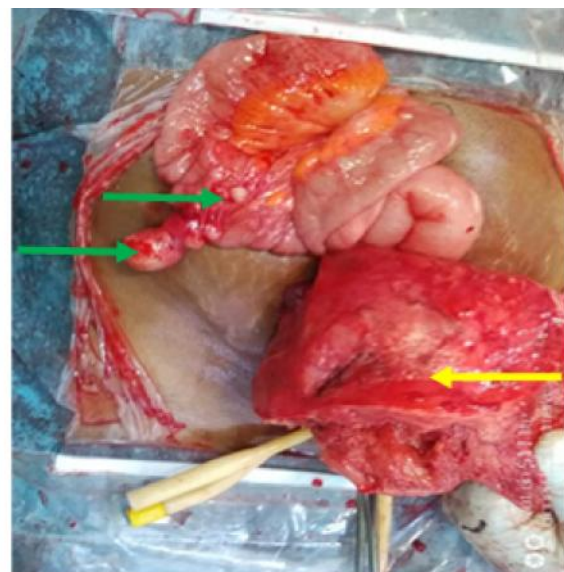


Figure 1b

Figure 1: Figure 1a – shows a bulky uterus with multiple uterine fibroids before enucleation of fibroid nodules (blue arrow). Figure 1b – Shows uterus after enucleation of multiple fibroid nodules (yellow arrow) and parasitic fibroid nodules attached to the serosal surface of the colon (green arrow).

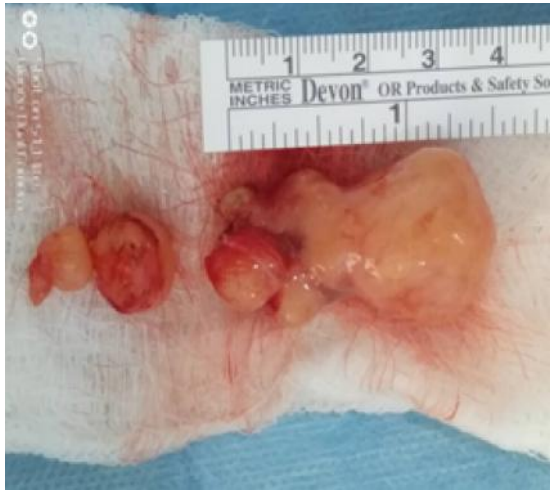

Figure 2: Parasitic fibroid nodules removed from the surface of the colon; largest measuring 3.5cm.

The histological examination of the cut section of the masses revealed whorled appearance, with some of the uterine masses showing degenerative features (See figure 3).

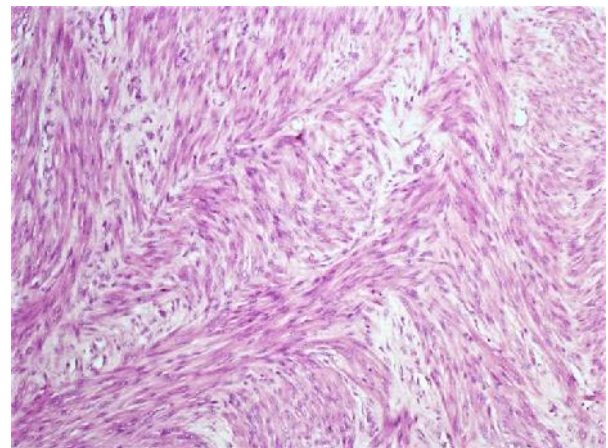
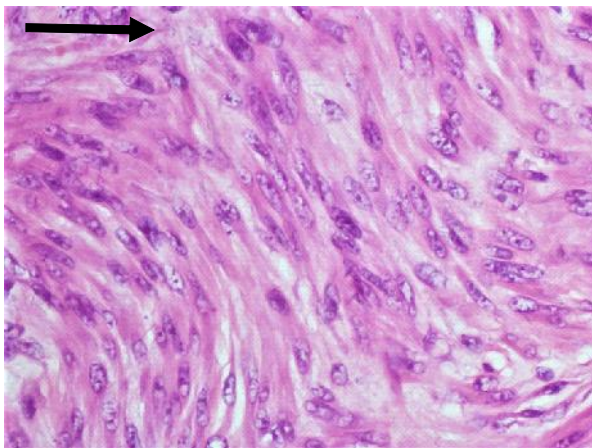


Figure 3: Histology micrograph of the parasitic fibroid nodules showing whorled appearance, with some of the uterine masses showing degenerative changes.

DISCUSSION

This case report describes parasitic fibroid nodules on the mesentery of the transverse colon coexisting with uterine fibroid found incidentally during abdominal myomectomy. The patient had symptomatic uterine fibroid complicated by menorrhagia. The presence of concomitant parasitic fibroid attached to the large bowel was not suspected pre-operatively and there were no gastrointestinal symptoms. The uterine and parasitic fibroids were successfully removed at abdominal myomectomy with no injury to the colon. Uterine fibroids are apparent in only about 20-25% of women of reproductive age and in many cases the diagnosis is straightforward.⁴ A parasitic fibroid may

occur beyond the uterus when a fibroid nodule acquires its major blood supply from adjacent structures and surviving on blood the new blood supply.^{5,6}

The incidence of parasitic fibroid is 0.12%. Parasitic fibroids are rare, difficult to diagnose, may be solitary or multiple⁷, small to large sized; and may be spontaneous (primary) or iatrogenic (secondary) following antecedent surgery. Shallu *et al.* and Sarmalkar *et al.* reported cases of primary spontaneous parasitic leiomyoma with no antecedent history of pelvic surgery.^{6,8} It can occur in older women; Nkencho *et al.* reported a huge primary parasitic leiomyoma occurring in a postmenopausal woman.⁹ Parasitic fibroid can grow to large sizes, Huang found fibroid size ranging between 8-30cm.

Mechanism of formation, location and antecedent events

In the formation of a parasitic fibroid, a subserous fibroid may attach to surrounding structures and acquires a new blood supply is the common mechanism. It subsequently outgrows the blood supply

from the uterus and the uterine pedicle becomes avascular.⁵ A detached fibroid nodule or fragments at myomectomy or pelvic surgery may also attach to structures and acquire blood supply.¹⁰ Other reports suggest the possibility of hematogenous spread of monoclonal cells to distant sites.^{3,11}

Parasitic fibroid commonly attaches to structures such as colon as seen in the index case, omentum and small bowel, port site, common iliac artery and inferior mesenteric artery.^{5,6,12,13} Also, the fibroid may be attached to the urinary bladder and large gut acquiring blood supply from these structures.⁶ Other rare

location reported by Yanzume et al is the abdominal wall subcutaneous adipose tissue along the longitudinal surgical scar.¹⁴

Parasitic fibroids are commonly preceded by previous pelvic surgery such as abdominal myomectomy, laparoscopic surgeries - myomectomy, laparoscopic myomectomy with morcellation, laparoscopic hysterectomy.¹⁵ There are increasing reports of parasitic fibroids being recognized after laparoscopic myomectomy, especially in cases where tumors are morcellated for removal.^{7,15} In a review by Huang *et al.*, 78% of patients with parasitic fibroid had laparoscopic myomectomy and morcellation as the antecedent surgery preceding the formation of parasitic fibroid.⁷ There is a growing evidence that the risk is higher in laparoscopic than open pelvic operations. Due to a rise in uptake of laparoscopic procedures, surgeons should be aware of the potential for iatrogenic parasitic myoma formation, the increasing frequency, and intraoperative precautions should be taken to minimize occurrence of the type of myoma.

In a case series of parasitic fibroids over a three-year period, 4 cases were detected in 423 women where electric morcellators were used for tumor removal. The over-all prevalence of developing parasitic fibroids was reported to be 0.9 and 1.2% for those who had laparoscopic myomectomies.¹⁶

Kimberly A *et al.* outlined a large series of twelve cases of parasitic myoma. They observed 83% with prior abdominal surgery, 67% had prior myomectomy comprising of 6 laparoscopic myomectomies with morcellation and 2 cases of laparotomy. Almost all cases presented with pain and uterine bleeding.¹⁷ They attributed these symptoms to concomitant uterine fibroid.

Clinical presentation and diagnosis:

Parasitic fibroids are known for atypical clinical presentation and the clinical features depend on the adjoining visceral structures it is attached to. It may be asymptomatic and only discovered as an incidental finding at surgery as seen in this case report or during radiologic evaluation^{17,18} for other indications especially if it is a small parasitic fibroid nodule. Or it may be symptomatic presenting with clinical features such as abdominal swelling or distension, abdominal pain, pelvic pain, dyspareunia, vaginal mass⁷; or features of bowel obstruction.¹⁹

In this case report, the parasitic fibroid was an incidental intraoperative finding. The patient had previous uterine surgery and presented with uterine bleeding. The patient had other uterine fibroid-related

symptoms which may have distracted the patient from observing significant gastrointestinal symptoms as a result of its location considering its attachment to the colon.

Even though it is rare, it should be considered in the differential diagnosis of pelvic or abdominal tumors in females especially in women with antecedent history of risk factors. In a few cases it poses a diagnostic dilemma and may necessitate histology or immunohistochemistry for diagnosis.¹⁵

The complications associated with parasitic fibroid vary and depends on the location and adjoining structures. Jamwal *et al.* reported a case of parasitic fibroid burrowing into the posterior wall of the small gut.⁶ Degenerative changes and its sequel may occur in parasitic fibroid. Araki et al reported red degenerative changes of parasitic fibroid on Magnetic resonance imaging.²⁰

Parasitic fibroids are commonly incidental findings. Imaging techniques such as Magnetic resonance imaging (MRI), abdominal and pelvic ultrasonography may be useful modalities in identification of parasitic fibroid in some cases. However, these may be misleading or fail to establish the diagnosis.²¹

In conclusion, parasitic fibroid is rare, it can be a diagnostic challenge and may be missed in asymptomatic patients. In patients with uterine fibroid undergoing primary or repeat surgery; it is important to explore the peritoneal cavity at surgery to rule out the presence of a parasitic fibroid at surgery and to reduce the risk of parasitic fibroid and its attendant complications.

Declaration of Conflicts of Interest: The authors have no conflicts of interest to declare.

Funding Statement: Self-sponsored

Acknowledgement: None

REFERENCES

1. **Stewart EA**, Cookson CL, Gandolfo RA, Schulze-Rath R. Epidemiology of uterine fibroids: a systematic review. *BJOG* 2017;124(10):1501-1512.
2. **Jones HW**, Rock JA. Leiomyomata Uteri and Myomectomy. In: Jones HW, eds. *Te Linde's Operative Gynecology*. 11th ed. Philadelphia, (PA): Wolters Kluwer; 2015. p. 658-662.
3. **Berek JS**. Uterine Fibroids. In: Berek JS, eds. *Berek & Novak's Gynecology*. 15th ed. Philadelphia, (PA): Lipincott Williams & Wilkins; 2015. p. 797-865.

4. **Ali R**, Gunesekera A, Alman G. A case of parasitic leiomyoma. 26th World Congress on Ultrasound in Obstetrics and Gynecology. EP29.10
5. **Elagwany AS**, Rady HA, Abdeldayem TM. A case of parasitic leiomyoma with serpentine omental blood vessels: An unusual variant of uterine leiomyoma. *Journal of Taibah University Medical Sciences* (2014) 9(4), 338e340
6. **Jamwal S**, Manhas A, Manhas K. A Parasitic Fibroid. *JK Science July - September 2015; 17(3): 161-162*
7. **Huang P**, Chang W, Huang S. Iatrogenic parasitic myoma: A case report and review of the literature. *Taiwanese Journal of Obstetrics & Gynecology* 53 (2014) 392e396
8. **Sarmalkar M**, Nayak A, Singh N, *et al.* A rare case of primary parasitic leiomyoma mimicking as ovarian mass: a clinical dilemma. *International Journal of Reproduction, Contraception, Obstetrics and Gynecology. Int J Reprod Contracept Obstet Gynecol.* 2016 Feb;5(2):545-548
9. **Osegi N**, Oku EY, Uwaezuoke CS, *et al.* Huge primary parasitic leiomyoma in a postmenopausal lady: A rare presentation. *Hindawi. Case Reports in Obstetrics and Gynecology. Volume 2019; Article ID 7683873, 4 pages.* <https://doi.org/10.1155/2019/7683873>
10. **Aust T**, Gale P, Cario G, Robertson G. Bowel resection for iatrogenic parasitic fibroids with preoperative investigations suggestive of malignancy. *Fertility and Sterility.* 2011, July; Vol. 96: No. 1. doi:10.1016/j.fertnstert.2011.04.097
11. **Barnas E**, Ras R, Skret-Magiero J, *et al.* Natural history of leiomyomas beyond the uterus. *Medicine* 2019; 98:25(e15877). <http://dx.doi.org/10.1097/MD.00000000000015877>
12. **Anand N**, Handler M, Khan A, *et al.* Disseminated peritoneal leiomyomatosis status post laparoscopic hysterectomy with morcellation. *Radiology Case.* 2016 Dec; 10(12):12-18. DOI: 10.3941/jrcr.v10i12.2904
13. **Oindi FM**, Mutiso SK, Obura T. Port site parasitic leiomyoma after laparoscopic myomectomy: a case report and review of the literature. *Journal of Medical Case Reports* (2018) 12:339. <https://doi.org/10.1186/s13256-018-1873-y>
14. **Yanazume S**, Tsuji T, Yoshioka T, *et al.* Large parasitic myomas in abdominal subcutaneous tissue along a previous myomectomy scar. *J Obstet Gynaecol Res.* 2012; 38:875-879
15. **Pai AH**, Yen C, Lin S. Parasitic Leiomyoma. *Gynecology and Minimally Invasive Therapy* 2020; 108-109.
16. **Cucinella G**, Granese R, Calagna G, *et al.* Parasitic myomas after laparoscopic surgery: an emerging complication in the use of morcellator? Description of four cases. *Fertil Steril.* 2011;96(2): e90-96.
17. **Kimberley AK**, Ceana N. Parasitic myomas. *Obstet and Gynecol* 2009;114:6+11-15.
18. **Okoro I**, Ododo N, Egejuru R. Parasitic leiomyoma: a diagnostic dilemma. A case report. *Niger J Clinl Pract* 2007;10(4): 349-351
19. **Khan A**, Shawl A, Leung PS. Parasitic leiomyoma of the greater omentum presenting as small bowel obstruction. *Journal of Surgical Case Reports,* 2018; 7: 1–3. doi: 10.1093/jscr/rjy164
20. **Araki H**, Yoshizako T, Yoshida R, Maruyama M, Ishikawa N, Kitagaki H. MR Imaging of Parasitic Leiomyoma with Red Degeneration. *Magn Reson Med Sci* 2020; 19; 87–88. doi:10.2463/mrms.ici.2019-0028
21. **Kale T**, Tambe S, Alnur Y. Parasitic fibroid: a diagnostic dilemma. *The New Indian Journal of OBGYN.* 2016; 3(1):47-50. doi:10.21276/obgyn.2016.3.1.9