

Received: 2017.06.22
Accepted: 2017.08.07
Published: 2018.02.21

Comparison of Percutaneous Kyphoplasty and Bone Cement-Augmented Short-Segment Pedicle Screw Fixation for Management of Kümmell Disease

Authors' Contribution:
Study Design A
Data Collection B
Statistical Analysis C
Data Interpretation D
Manuscript Preparation E
Literature Search F
Funds Collection G

ABCEF 1 **Yan-Sheng Huang**
ADG 2 **Ding-Jun Hao**
BF 2 **Hang Feng**
C 2 **Hai-Ping Zhang**
B 2 **Si-Min He**
D 2 **Chao-Yuan Ge**
F 1 **Xing-Bang Niu**

1 Xi'an Medical University, Xi'an, Shaanxi, P.R. China
2 Department of Spine Surgery, Honghui Hospital, Xi'an Jiaotong University, Xi'an, Shaanxi, P.R. China

Corresponding Author: Ding-Jun Hao, e-mail: 15891729582@163.com

Source of support: This study was supported by the National Natural Science Foundation of China (No. 81472098)

Background: The purpose of this study was to compare the efficacy of percutaneous kyphoplasty (PKP) and bone cement-augmented short segmental fixation (BCA+SSF) for treating Kümmell disease.





Material/Methods: Between June 2013 and December 2015, 60 patients were treated with PKP or BCA+SSF. All patients were followed up for 12–36 months. We retrospectively reviewed outcomes, including Oswestry Disability Index (ODI), visual analogue scale (VAS), and kyphotic Cobb angle.

Results: VAS, ODI, and Cobb angle, measured postoperatively and at the final follow-up, were lower than those measured preoperatively in both groups ($P < 0.05$). VAS, ODI, and Cobb angle measured postoperatively demonstrated no significant differences when compared with those measured at the final follow-up in the PKP group ($P > 0.05$). In the BCA+SSF group, VAS and ODI at the final follow-up were lower than those measured postoperatively ($P < 0.05$), but no significant difference was found in the Cobb angle ($P > 0.05$). The PKP group had better VAS and ODI than the BCA+SSF group, postoperatively ($P < 0.05$). No significant difference was found in VAS and ODI at the final follow-up ($P > 0.05$) or the Cobb angle measured postoperatively and at the final follow-up ($P > 0.05$) between the 2 groups. Operative time, blood loss, and hospital stay in the PKP group were lower than those in the BCA+SSF group ($P < 0.05$). No significant difference was found in complications ($P > 0.05$).

Conclusions: PKP patients had better early clinical outcomes, shorter operation times and hospital admission times, and decreased blood loss, but had similar complications, radiographic results, and long-term clinical outcomes compared with BCA+SSF patients.

MeSH Keywords: **Comparative Study • Fracture Fixation, Internal • Kyphoplasty • Osteoporosis • Spinal Fractures**

Full-text PDF: <https://www.medscimonit.com/abstract/index/idArt/905875>

 2790  4  2  28



Background

Kümmell disease, as a complication of osteoporotic vertebral fractures (OVF), is not rare, especially with an increasing number of OVF cases reported in recent years [1]. Primary symptoms include intractable back pain, activity limitation, kyphosis progression, and delayed neurological deficits. Since Kümmell disease was first described in 1891, various reports have regarded this disease as a nonunion of OVF [2,3], intravertebral pseudarthrosis [4], delayed osteonecrosis [5,6], delayed collapse after vertebral fracture [7], and intravertebral vacuum sign [8,9]. Although the concept and diagnosis of Kümmell disease are ambiguous, more and more cases are being recognized with the advancement of radiographic evaluations of vertebral status, particularly after the popularity of magnetic resonance imaging (MRI).

Treatment strategies for Kümmell disease differ between the patients with neurological symptoms and those without. For patients without neurological symptoms, the aim of the treatment is to preserve movement in the diseased vertebra and to maintain the sagittal balance of the spine. Percutaneous kyphoplasty (PKP) and percutaneous vertebroplasty (PVP) restore the vertebral body height and correct the deformity, which help to achieve satisfactory effects in relieving pain. These procedures have been widely accepted for the treatment of Kümmell disease [10–12]. However, some reports have noted the occurrence of cement displacement and further collapse following PKP or PVP [13–15]. Therefore, bone cement augmentation in combination with short-segment pedicle screw fixation (BCA+SSF) has been recommended to treat this particular condition in recent years. Some positive effects on pain relief and functional recovery have been reported following the elimination of vertebral instability by posterior short-segment fixation operation [16–18]. However, there is no consensus on the best treatment options for Kümmell disease. Meanwhile, there have been no comparative studies on PKP and BCA+SSF for treating Kümmell disease previously; thus, this study may provide a reference for the selection of therapeutic methods.

In this study, we compared the efficacy of PKP and BCA+SSF in treating Kümmell disease and explored suitable therapy options.

Material and Methods

Ethics statement

This retrospective study was approved by the Ethics Committee of Honghui Hospital, affiliated with Xi'an Jiaotong University. Written consent was obtained from all patients.

Patients

Between June 2013 and December 2015, 60 patients with Kümmell disease were treated at our center. These patients were divided into 2 groups (PKP or BCA+SSF) according to the surgical intervention used in their treatment. The PKP group consisted of 32 patients (8 males and 24 females), with ages ranging from 56 to 83 years (mean, 70.5 ± 5.8 years). The T-score of lumbar spine bone mineral density ranged from -2.6 to -4.3 standard deviation (SD), with a mean of -3.36 ± 0.4 SD. The course of disease in the PKP group ranged from 1 to 7 months, with an average duration of 3.75 ± 1.7 months. In contrast, the BCA+SSF group included 28 patients (6 males and 22 females), with their ages ranging from 54 to 81 years (mean, 69.8 ± 6.0 years). The T-score of lumbar spine bone mineral density ranged from -2.6 to -4.2 SD, with a mean of -3.42 ± 0.4 SD. The course of disease in the BCA+SSF group ranged from 1 to 8 months, with an average duration of 3.82 ± 1.8 months. Forty-two of the 60 patients underwent episodes of trauma. The general data of patients in both groups are shown in Table 1. All patients had severe back pain, and in all cases, the severity of back pain depended on the patient's position. All patients underwent conservative treatment for at least 1 month prior to admission. Patients with neurological deficits, tumor, infection, or previous spinal surgery were excluded from this study.

Surgical procedures

Patients in the PKP group received local anesthesia and were placed in a prone position, with pillows placed under the pelvis and upper chest to promote the reduction of the diseased vertebra. Bilateral transpedicular working channels were completed by cannula and trocar systems under fluoroscopic control. A balloon was then placed into the cavity of the intravertebral cleft (IVC) in the collapsed vertebrae through the working channel. Satisfactory effects of the correction of kyphosis and vertebral height were predominantly noted after the balloon was inflated carefully. Finally, polymethylmethacrylate (PMMA) bone cement was injected slowly to the point at which it became doughy and could stand at the tip of the bone cement inserter. The injection process was deemed complete when a large amount of cement was injected into the cavity of the intravertebral cleft (IVC). All the above processes were monitored under fluoroscopic control in the lateral plane.

For their procedures, the patients in the BCA+SSF group received general anesthesia and were placed in a prone position. Pillows were placed under the diseased vertebra to restore the hyperextension of the spine preoperatively. It is known that the height of the vertebral body can be restored through this hyperextension position. We used a standard posterior midline approach to expose the spinous processes, lamina, and facet joint, and 6 screws were inserted bilaterally into one

Table 1. General data of patients in 2 group.

	PKP	BCA+SSF	P
Number of patients	32	28	
Age (years)	70.5±5.8	69.8±6.0	0.640
Sex (Female/Male)	24/8	22/6	0.744
Medical history (month)	3.75±1.7	3.82±1.8	0.875
BMD (T score)	-3.36±0.4	-3.42±0.4	0.627

PKP – percutaneous kyphoplasty; BCA+SSF – bone cement-augmented short segmental pedicle screw fixation; BMD – bone mineral density.

level above, one level below, and at the location of the collapsed vertebra itself. After that, 6 pedicle screws were fixed with 2 rods. PMMA cement was injected slowly into the vertebral body after a proper recovery of the vertebral height, and this process was monitored under fluoroscopic control in the lateral plane. Allograft was then used to facilitate posterolateral fusion. A crosslink was used in all patients. The incision was rinsed and hemostasis achieved. Finally, the wound was closed using a layer-to-layer suture.

Effectiveness evaluation

Impact on the patient's daily life was evaluated using the Oswestry Disability Index (ODI). Back pain was assessed using the visual analogue scale (VAS) score. The kyphotic Cobb angle was measured using the lateral x-ray. All the above data were analyzed preoperatively, immediately after surgery, and at the final follow-up. Each patient underwent spinal x-ray, MRI, and computed tomography (CT) preoperatively, as well as X-rays postoperatively and during follow-up. Postoperative CT and MRI were performed selectively, depending on the patient's condition. Additionally, the duration of surgery, blood loss, hospital stay, and complications were recorded and evaluated.

Statistical analyses

All analyses were performed using IBM SPSS Statistics for Windows, version 19.0 (IBM Corp., Armonk, NY, USA). All measurement data were expressed as mean and SD. Pre- and postoperative measurement data were compared using a paired t-test. Statistical analyses between the 2 groups were performed using chi-square test or Fisher's exact test for count data and Student's t-test for measurement data. $P < 0.05$ was considered to indicate a statistically significant difference.

Results

There were no statistically significant differences in general data (patients' age, sex, medical history, and bone mineral density)

between the 2 groups (Table 1). Follow-up data were recorded for every patient. The follow-up period ranged from 12 to 36 months, with a mean of 24.5 months. The operation time (43.1 ± 7.1 minutes) in the PKP group was significantly lower than that in the BCA+SSF group (115.9 ± 10.0 minutes; $P < 0.05$). Blood loss in the PKP group (9.9 ± 2.7 mL) was significantly lower than that in the BCA+SSF group (214.3 ± 17.5 mL; $P < 0.05$). The length of hospital admission in the PKP group (3.4 ± 1.2 days) was significantly lower than that in the BCA+SSF group (7.6 ± 1.3 days; $P < 0.05$).

The VAS score, ODI score, and kyphotic Cobb angle immediately after the operation and at the final follow-up were significantly lower than the respective preoperative readings in both groups ($P < 0.05$). The VAS score, ODI score, and kyphotic Cobb angle showed no significant differences when comparing immediate and final follow-up results in the PKP group ($P > 0.05$). In the BCA+SSF group, VAS and ODI scores at the final follow-up were significantly lower than those immediately after the operation ($P < 0.05$). However, no significant difference was found in the kyphotic Cobb angle ($P > 0.05$). The PKP group scored significantly lower than the BCA+SSF group in VAS and ODI immediately after the operation ($P < 0.05$), but no significant difference was found in either VAS or ODI between the 2 groups at their final follow-up ($P > 0.05$). There was no significant difference in the kyphotic Cobb angle between the 2 groups immediately after the operation and at final follow-up ($P > 0.05$). The data of patients in both groups are shown in Tables 2–4.

Illustrative cases are shown in Figures 1 and 2. The final follow-up reviews revealed that the fine cement or internal fixation position yielded satisfactory radiographic results. Three patients experienced asymptomatic cement leakage in the PKP group. In the BCA+SSF group, 3 patients had asymptomatic cement leakage, one developed a urinary tract infection, one contracted pneumonia, and one experienced delayed wound healing. All of these patients recovered following conservative treatment. However, the study analysis indicated that there were no significant differences in complications between the 2

Table 2. Comparison of the VAS between 2 groups preoperatively, immediately after surgery, and at final follow-up.

Group	n	Preoperatively	Immediately after surgery	Final follow-up
PKP	32	8.1±0.8	2.8±0.8*	2.9±1.2* ^{***}
BCA+SSF	28	8.0±0.9	3.8±0.7*	2.7±1.3* ^{**}
Statistics		t=0.284, P=0.777	t=-5.132, P=0.000	t=0.611, P=0.544

* P<0.05 vs. preoperatively values; ** P<0.05 vs. immediately after surgery values; *** P>0.05 vs. immediately after surgery values. VAS – visual analog scale; PKP – percutaneous kyphoplasty; BCA+SSF – bone cement-augmented short segmental pedicle screw fixation.

Table 3. Comparison of the ODI between 2 groups preoperatively, immediately after surgery, and at final follow-up.

Group	n	Preoperatively	Immediately after surgery	Final follow-up
PKP	32	75.3±5.0	33.5±3.7*	34.4±5.0* ^{***}
BCA+SSF	28	74.4±5.1	38.3±4.8*	33.1±4.4* ^{**}
Statistics		t=0.730, P=0.469	t=-4.355, P=0.000	t=1.058, P=0.295

* P<0.05 vs. preoperatively values; ** P<0.05 vs. immediately after surgery values; *** P>0.05 vs. immediately after surgery values. ODI – Oswestry Disability Index; PKP – percutaneous kyphoplasty; BCA+SSF – bone cement-augmented short segmental pedicle screw fixation.

Table 4. Comparison of the kyphotic Cobb angle between 2 groups preoperatively, immediately after surgery, and at final follow-up

Group	n	Preoperatively	Immediately after surgery	Final follow-up
PKP	32	22.9±3.9	14.5±3.8*	15.1±4.6* ^{**}
BCA+SSF	28	22.6±5.9	13.6±3.9*	14.0±4.4* ^{**}
Statistics		t=0.253, P=0.802	t=0.927, P=0.358	t=0.974, P=0.334

* P<0.05 vs. preoperatively values; ** P>0.05 vs. immediately after surgery values. PKP – percutaneous kyphoplasty; BCA+SSF – bone cement-augmented short segmental pedicle screw fixation.

groups (P>0.05). No nerve damage was found postoperatively, and no bone cement displacement was evident during follow-up. Furthermore, there was no loosening, displacement, or fracture of internal fixation seen at the final follow-up.

In summary, these results reveal that the 2 procedures achieved similar complications, radiographic findings, and long-term clinical outcomes. However, PKP showed a superior result in early clinical outcomes, with shorter operation and hospital admission times, and decreased blood loss.

Discussion

Kümmell disease occurs more frequently as a complication of OVF along with an increasing incidence of OVF (which mostly occurs in females older than 50 years). Although most cases of OVF can be treated conservatively with bed rest, analgesics,

and a brace, at least 10% of patients develop nonunion [19]. However, this percentage may not represent the true incidence because many asymptomatic or unrecognized cases are not included. The thoracolumbar junction, particularly the T12 vertebra, is the most commonly affected vertebral segment [5,13]. A series of significant risk factors for nonunion have been reported, including the presence of a vertebral fracture in the thoracolumbar spine, the presence of a middle-column injury, and a confined high-intensity or a diffuse low-intensity area in the fractured vertebrae on T2-weighted magnetic resonance (MR) imaging [2]. Although the concept and diagnosis of Kümmell disease are ambiguous, an increasing number of cases continue to be recognized with the advancement of radiographic evaluations of vertebral status, particularly since the introduction and rise in popularity of MRI [20]. Of the available imaging techniques, radiographs are the least sensitive method for diagnosis. CT examination with coronal and sagittal reconstructed views better demonstrates IVC, but MRI is the most sensitive method for

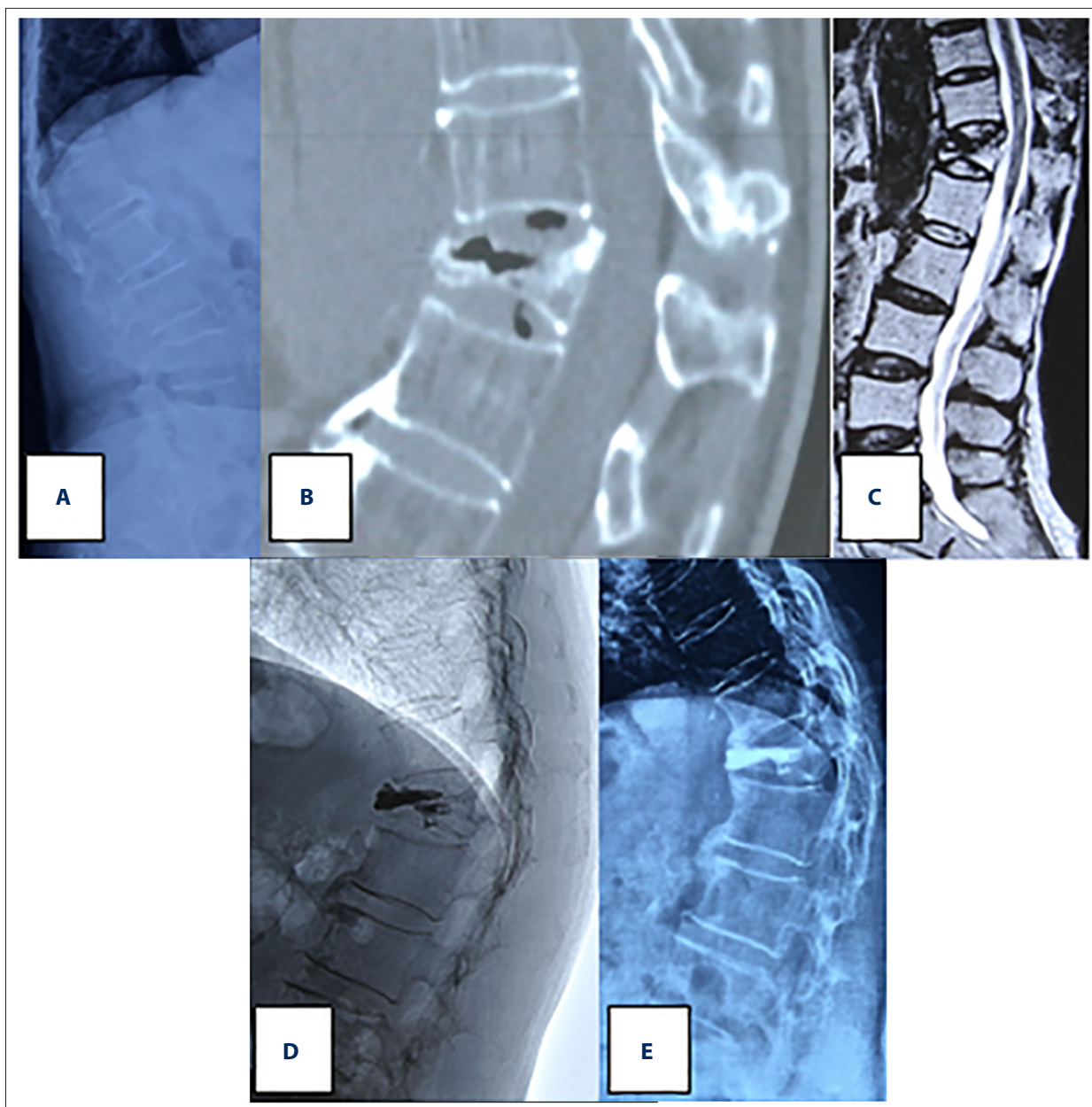


Figure 1. Female patient, aged 63 years, with back pain for 3 months, who underwent percutaneous kyphoplasty (PKP). (A–C) Preoperative lateral x-ray and CT scan showed L1 vertebral fracture with vacuum-like changes, MRI showed low signal of the necrotic area on T2-weighted images. (D, E) Postoperative x-ray showed that the cavity of intravertebral cleft was filled with bone cement, and the final follow-up review revealed fine cement position and satisfactory radiographic results.

detection of Kümmell disease due to its demonstration of soft tissue characteristics, including marrow edema and fluid within the IVC [3]. Clinically, Kümmell disease is diagnosed by a delayed collapse of the vertebra and dynamic instability that ultimately progresses to kyphosis with long-term back pain or nerve injury, in combination with noted evidence of IVC on the MR image.

There is no standard treatment and no single effective treatment for Kümmell disease at present [12,21]. In general, reports

suggest that conservative treatments are usually less effective, and that they have a risk of a high complication rate and delayed neurological deficit [21,22]. Many surgeons believe that Kümmell disease should be treated with surgical intervention. Treatment methods differ for patients with neurological deficits and those without neurological deficits. For neurologically impaired patients, the aim of surgery is to relieve cord compression, eliminate spinal instability, and restore the sagittal balance of the spine [16,17]. A variety of surgical options

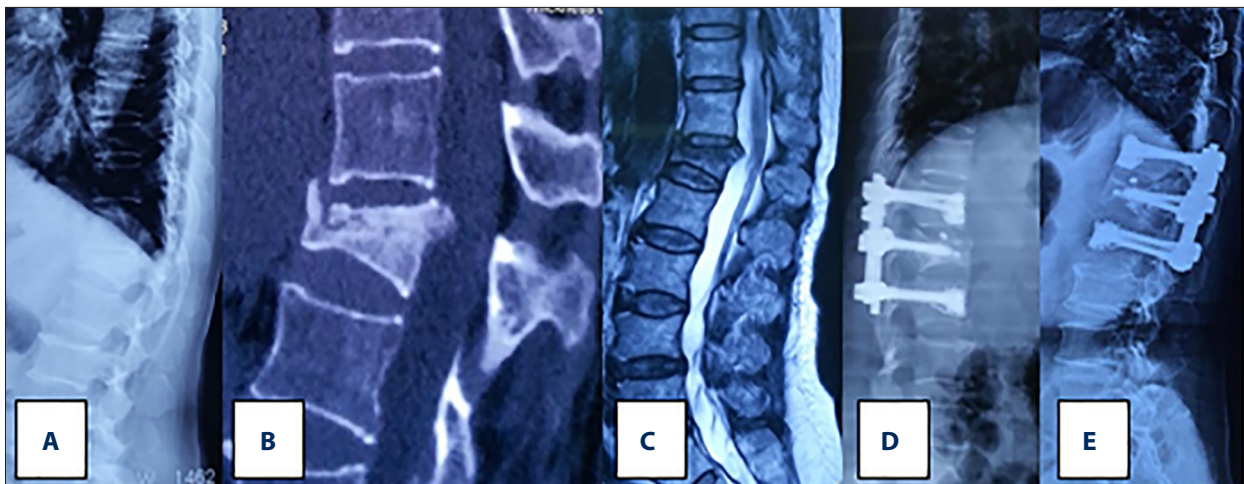


Figure 2. Female patient, aged 68 years, with back pain for 3 months, who underwent bone cement-augmented short segmental pedicle screw fixation. (A–C) Preoperative lateral x-ray and CT showed T12 vertebral fracture with intravertebral cleft, MRI showed low signal of the necrotic area on the T2-weighted images. (D, E) Postoperative and the final follow-up reviews showed fine bone cement-augmented internal fixation position and satisfactory radiographic results.

exists, including anterior-only, posterior-only, and combined anterior and posterior procedures [23–26]. For patients without neurological deficit, the purpose of surgery is to preserve movement in the diseased vertebra and to maintain the balance of the spine. Many authors have reported that PKP or PVP achieved good clinical results for Kümmell disease in these patients [10–12]. To date, PKP and PVP have been widely accepted for use in the elderly with comorbidities, because they are less invasive than traditional fixation surgery and can help patients move early. Compared to previous studies, we also achieved similar effects in terms of pain relief and functional recovery following PKP in this study.

However, there are still some PKP problems requiring further examination. Recently, delayed cement displacement and further collapse have been reported in cases of Kümmell disease treated by cement augmentation alone, along with poor bone incorporation of cement that was discovered after long-term follow-up [13–15]. A study suggested that cement augmentation can provide anterior support in collapsed vertebrae, but the supporting outcome may not be enough because of the cement spreading into the bone [27]. Therefore, displacement of the bone cement and further vertebral collapse may occur after PKP or PVP. In recent years, some researchers have recommended bone cement augmentation in combination with posterior fixation operation for this particular condition [16–18], but there have been only a few such studies. In 2011, Lee et al. reported satisfactory results for 10 patients with Kümmell disease treated with vertebroplasty in combination with short segmental fixation [17]. In 2013, another study showed that posterior decompression with short-segment fixation and fusion, combined with vertebroplasty, is an effective treatment for Kümmell disease, especially in patients who are

unable to tolerate long surgical procedures and/or massive blood loss [16]. In 2015, Park et al. also achieved satisfactory results with 10 cases of Kümmell disease and severe osteoporosis with bone cement-augmented percutaneous short-segment pedicle screw fixation [18].

In this study, the VAS score, ODI score, and kyphotic Cobb angle immediately after surgery and at the final follow-up were significantly higher than they were preoperatively in both the PKP and BCA+SSF groups ($P < 0.05$). This result shows that PKP and BCA+SSF are safe and effective treatments for patients with Kümmell disease without neurological deficits. Immediately after surgery, VAS and ODI scores in the PKP group were significantly lower than those in the BCA+SSF group, but there was no statistically significant difference in VAS and ODI scores between the groups at the final follow-up. The results in this study show that the PKP group had a better result with respect to early pain relief and the improvement of functional status than the BCA+SSF group, but the long-term effects were similar in both. This is possibly due to the BCA+SSF procedure causing greater trauma, which can affect early pain relief and functional recovery immediately after surgery. Additionally, there were no significant differences between VAS and ODI scores immediately after surgery and at the final follow-up in the PKP group ($P > 0.05$). Conversely, VAS and ODI scores at the final follow-up were significantly lower than those measured immediately after surgery in the BCA+SSF group ($P < 0.05$). These results show that BCA+SSF can effectively preserve motion segments and provide strong support and stability; hence, it can achieve satisfactory long-term clinical results.

The duration of surgery, blood loss, and hospital stay in the PKP group were significantly lower than those in the BCA+SSF

group ($P < 0.05$). These results reveal that PKP is less invasive and can be performed more safely than BCA+SSF. This is especially important for elderly patients with comorbidities. Because Kümmell disease usually occurs in adults older than 50 years, the patients in this study were older and may have had many comorbidities and severe osteoporosis; thus, complex surgical methods could not be tolerated. Three patients in the PKP group had asymptomatic cement leakage, but no other complications occurred. Among patients in the BCA+SSF group, 3 had asymptomatic cement leakage, 1 acquired a urinary tract infection, 1 contracted a pulmonary infection, and 1 experienced delayed wound healing. PKP is characterized by a lower risk for complications than internal fixation procedures in previous reports, but there was no significant difference in complications between the 2 groups in this study ($P > 0.05$). This may be related to the short follow-up time and small sample size of this study. Additionally, in this study, a mild reduction in kyphosis correction at the time of final follow-up was observed in both groups, but the differences showed no statistical significance ($P > 0.05$). The mean loss of kyphosis correction did not differ significantly from traditional posterior or anterior procedures in previous studies [17,23–26,28], although some reports have suggested that there is a risk of further kyphotic deformity in patients with severe osteoporosis [13,16,17].

References

- Kim YC, Kim YH, Ha KY: Pathomechanism of intravertebral clefts in osteoporotic compression fractures of the spine. *Spine J*, 2014; 14: 659–66
- Tsujiro T, Nakamura H, Terai H et al: Characteristic radiographic or magnetic resonance images of fresh osteoporotic vertebral fractures predicting potential risk for nonunion: A prospective multicenter study. *Spine (Phila Pa 1976)*, 2011; 36: 1229–35
- Chen GD, Lu Q, Wang GL et al: Percutaneous kyphoplasty for Kümmell disease with severe spinal canal stenosis. *Pain Physician*, 2015; 18: E1021–8
- Kim HS, Heo DH: Percutaneous pedicle screw fixation with polymethylmethacrylate augmentation for the treatment of thoracolumbar intravertebral pseudoarthrosis associated with Kümmell's osteonecrosis. *Biomed Res Int*, 2016; 2016: 3878063
- Young WF, Brown D, Kendler A, Clements D: Delayed post-traumatic osteonecrosis of a vertebral body (Kümmell's disease). *Acta Orthop Belg*, 2002; 68: 13–19
- Lee GW, Yeom JS, Kim HJ, Suh BG: A therapeutic efficacy of the transpedicular intracorporeal bone graft with short-segmental posterior instrumentation in osteonecrosis of vertebral body: A minimum 5-year follow-up study. *Spine (Phila Pa 1976)*, 2013; 38: E244–50
- Nakashima H, Imagama S, Yukawa Y et al: Comparative study of 2 surgical procedures for osteoporotic delayed vertebral collapse: Anterior and posterior combined surgery versus posterior spinal fusion with vertebroplasty. *Spine (Phila Pa 1976)*, 2015; 40: E120–26
- Pappou IP, Papadopoulos EC, Swanson AN et al: Osteoporotic vertebral fractures and collapse with intravertebral vacuum sign (Kümmell's disease). *Orthopedics*, 2008; 31: 61–66
- He D, Yu W, Chen Z et al: Pathogenesis of the intravertebral vacuum of Kümmell's disease. *Exp Ther Med*, 2016; 12: 879–82
- Huang Y, Peng M, He S et al: Clinical efficacy of percutaneous kyphoplasty at the hyperextension position for the treatment of osteoporotic Kümmell disease. *Clin Spine Surg*, 2016; 29: 161–66
- Matsuura M, Fujimoto Y, Yamada K, Nakamae T: Percutaneous vertebroplasty versus balloon kyphoplasty for osteoporotic vertebral fracture with intravertebral cleft. *Spine J*, 2014; 14: S123
- Yang H, Pan J, Wang G: A review of osteoporotic vertebral fracture non-union management. *Spine (Phila Pa 1976)*, 2014; 39: B4–6
- Laredo JD: Expert's comment concerning Grand Rounds case entitled "Kümmell's disease: Delayed post-traumatic osteonecrosis of the vertebral body" (by R. Ma, R. Chow, F. H. Shen). *Eur Spine J*, 2010; 19: 1071–72
- Wagner AL, Baskurt E: Refracture with cement extrusion following percutaneous vertebroplasty of a large interbody cleft. *Am J Neuroradiol*, 2006; 27: 230–31
- Wang HS, Kim HS, Ju CI, Kim SW: Delayed bone cement displacement following balloon kyphoplasty. *J Korean Neurosurg Soc*, 2008; 43: 212–14
- Zhang GQ, Gao YZ, Zheng J et al: Posterior decompression and short segmental pedicle screw fixation combined with vertebroplasty for Kümmell's disease with neurological deficits. *Exp Ther Med*, 2013; 5: 517–22
- Lee SH, Kim ES, Eoh W: Cement augmented anterior reconstruction with short posterior instrumentation: A less invasive surgical option for Kümmell's disease with cord compression. *J Clin Neurosci*, 2011; 18: 509–14
- Park SJ, Kim HS, Lee SK, Kim SW: Bone cement-augmented percutaneous short segment fixation: An effective treatment for Kümmell's disease? *J Korean Neurosurg Soc*, 2015; 58: 54–59
- Toyone T, Toyone T, Tanaka T et al: Changes in vertebral wedging rate between supine and standing position and its association with back pain: A prospective study in patients with osteoporotic vertebral compression fractures. *Spine (Phila Pa 1976)*, 2006; 31: 2963–66
- Chen B, Fan S, Zhao F: Percutaneous balloon kyphoplasty of osteoporotic vertebral compression fractures with intravertebral cleft. *Indian J Orthop*, 2014; 48: 53–59
- Li H, Liang CZ, Chen QX: Kümmell's disease, an uncommon and complicated spinal disorder: A review. *J Int Med Res*, 2012; 40: 406–14
- Fabbriciani G, Pirro M, Floridi P et al: Osteoanabolic therapy: A non-surgical option of treatment for Kümmell's disease? *Rheumatol Int*, 2012; 32: 1371–74
- Kanayama M, Ishida T, Hashimoto T et al: Role of major spine surgery using Kaneda anterior instrumentation for osteoporotic vertebral collapse. *J Spinal Disord Tech*, 2010; 23: 53–56

Conclusions

This study revealed that PKP and BCA+SSF can both achieve satisfactory results in treating Kümmell disease. However, in comparison with BCA+SSF, PKP had better early clinical outcomes, shorter operation and hospital admission times, and decreased blood loss, although they had similar complications, radiographic results, and long-term clinical outcomes.

Conflicts of interest

None.

24. Yang DL, Yang SD, Chen Q et al: The treatment evaluation for osteoporotic Kümmell disease by modified posterior vertebral column resection: minimum of one-year follow-up. *Med Sci Monit*, 2018; 24: 606–12
25. Wang F, Wang D, Tan B et al: Comparative study of modified posterior operation to treat Kümmell's disease. *Medicine (Baltimore)*, 2015; 94: e1595
26. Suk SI, Kim JH, Lee SM et al: Anterior-posterior surgery versus posterior closing wedge osteotomy in posttraumatic kyphosis with neurologic compromised osteoporotic fracture. *Spine (Phila Pa 1976)*, 2003; 28: 2170–75
27. Chen L, Dong R, Gu Y, Feng Y: Comparison between balloon kyphoplasty and short segmental fixation combined with vertebroplasty in the treatment of Kümmell's disease. *Pain Physician*, 2015; 18: 373–81
28. Uchida K, Kobayashi S, Matsuzaki M et al: Anterior versus posterior surgery for osteoporotic vertebral collapse with neurological deficit in the thoracolumbar spine. *Eur Spine J*, 2006; 15: 1759–67