

Simultaneous Bilateral Single-Port Radical Nephrectomies

Michael P. Herman, MD, Joseph J. Del Pizzo, MD

ABSTRACT

The management of bilateral enhancing renal masses can be technically challenging. Simultaneous bilateral laparoscopic nephrectomies in postrenal transplant patients have been previously described, but these typically require multiple port placements in addition to a hand port. Herein, we describe simultaneous bilateral single-port laparoscopic radical nephrectomies in a postrenal transplant patient.

Key Words: Bilateral nephrectomy, Single-port laparoscopic surgery, Renal neoplasms, Kidney transplantation.

INTRODUCTION

Bilateral enhancing renal masses can be technically difficult to manage. Whether to do simultaneous procedures or a staged approach is controversial, and both laparoscopic and open techniques have been described. The advent of laparoendoscopic single site surgery (LESS) has provided a new tool for minimally invasive surgeons. Here, we describe the use of LESS to perform simultaneous bilateral radical nephrectomies in a postrenal transplant patient.

CASE REPORT

The patient is a 47-year-old male with a history of end-stage renal disease due to hypertension. He underwent a living-related renal transplant in December 2008 and did well postoperatively. Two years later, he complained of testicular pain, for which he eventually received an abdominal ultrasound that showed a complex cyst in the right kidney. He denied fever, flank pain, malaise, weight loss, gross hematuria, or other constitutional symptoms. MRI demonstrated atrophic native kidneys with simple cysts as well as multiple enhancing solid tumors in both kidneys, the largest measuring 3cm x 2.8cm x 3.2cm (**Figure 1**). The right kidney measured 8.7cm x 4.2cm x 4.5cm, and the left measured 8.0cm x 4.9cm x 4.7cm. There was no family history of cancer, and the multiple cysts and enhancing lesions were felt due to acquired renal cystic disease of hemodialysis, so no additional search for familial causes was undertaken. The solid masses were most consistent with renal neoplasms, and the patient was taken to the operating room for bilateral native nephrectomies.

After the administration of general anesthesia, the patient was placed into the right lateral decubitus position with the table flexed. A 5-cm vertical periumbilical incision was made with the abdominal skin on stretch. The incision was carried down to the rectus fascia, and a 6-cm fasciotomy was created. After the peritoneum was entered, a single-port system (GelPoint, Applied Medical, Rancho Santa Margarita, CA) was used to perform a laparoscopic radical nephrectomy. Two 5-mm trocars are used as working ports with a 15-mm trocar as the camera port (**Figure 2**). A bariatric 10-mm rigid laparoscope is used with a right angle attachment for the light cord to maximize space for triangulation.

James Buchanan Brady Foundation, Department of Urology, Weill Cornell Medical College, New York, New York, USA (all authors).

Address correspondence to: Michael P. Herman, MD, Department of Urology, Weill Cornell Medical College, 525 E. 68th St., Starr 900, New York, NY 10021, USA. Telephone: (212) 746-5455, Fax: (212) 746-8207, E-mail: mih9032@nyp.org

DOI: 10.4293/108680811X13022985131499

© 2011 by JSLs, *Journal of the Society of Laparoendoscopic Surgeons*. Published by the Society of Laparoendoscopic Surgeons, Inc.

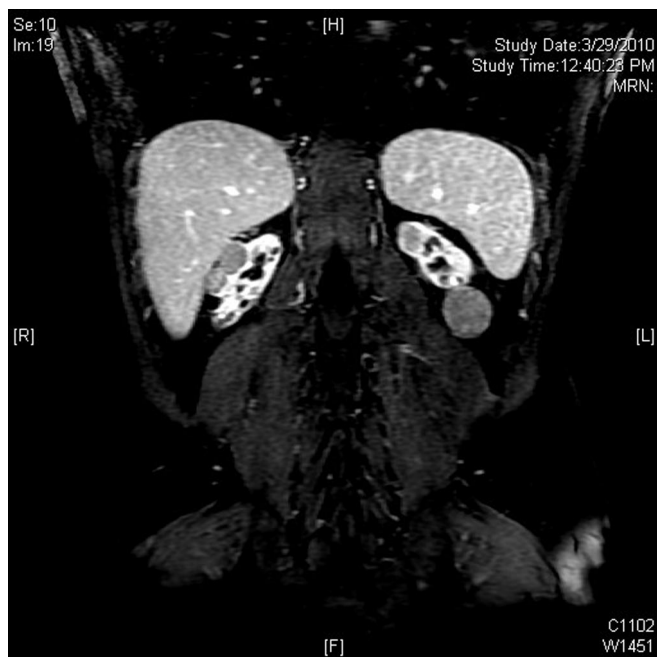

Figure 1. Coronal image from MRI of the abdomen/pelvis demonstrating atrophic native kidneys with enhancing solid tumors in both kidneys (here, 2 on the right mid-upper pole and 1 on the left upper pole), the largest measuring 3cm x 2.8cm x 3.2cm.

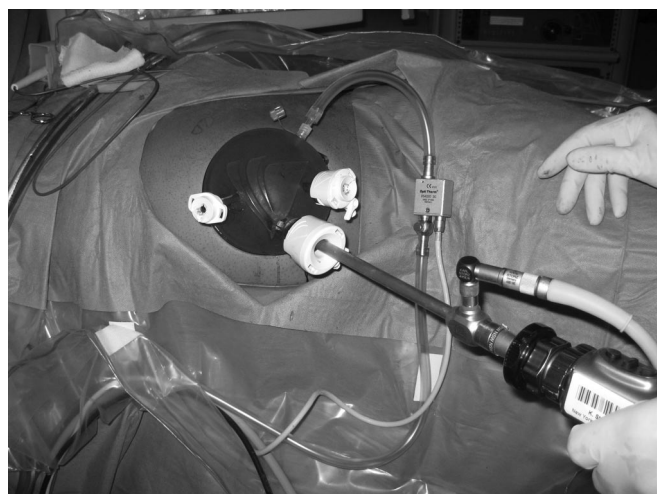


Figure 2. The single-port laparoscopic system used to perform bilateral native nephrectomies (GelPoint®, Applied Medical, Rancho Santa Margarita, CA). The two 5-mm trocars are used for working elements, and the 15-mm trocar is used as the camera port.

lation. Standard, nonarticulating laparoscopic instruments are used for the procedure.

The colon was reflected from the level of the upper sigmoid to the splenic flexure by incising the line of Toldt.

The descending colon, pancreas, and spleen were mobilized en bloc without the need for continuous retraction. The ureter and gonadal vein were identified and lifted off the psoas muscle, maintaining periureteral attachments while dissecting towards the hilum. A lumbar vein was divided between titanium clips. The renal vein was skeletonized, and the adrenal vein was divided between titanium clips, after which the adrenal gland was released from the upper pole. The renal artery was dissected down to its aortic origin and skeletonized. We replaced one of the 5-mm trocars with a 12-mm trocar to facilitate the use of a laparoscopic stapling device. The renal artery was transected using a stapling device (Multifire Endo TA 30 Stapler, Covidien, Mansfield, MA) and secured with a hemostatic clip (Hem-o-lok Ligation System, Teleflex Medical, Research Triangle Park, NC). The vein was then divided using a cutting stapling device (Multifire Endo GIA 30 Stapler, Covidien, Mansfield, MA). The ureter was identified lateral to the gonadal vein, and the same stapling device was used to divide the ureter and its surrounding adipose tissue at this level. The lateral border of the kidney was dissected from surrounding tissues, completely freeing the kidney. The kidney was placed into a laparoscopic retrieval bag. The renal hilum and spleen were checked for hemostasis. The kidney was then delivered intact through the periumbilical incision, and the GelPoint device was removed.

The incision was covered with an antimicrobial drape (3M Ioban 2 Antimicrobial Incise Drape, 3M, St. Paul, MN), and the patient was transferred from the right to the left lateral decubitus position, taking care not to disturb the drape. Once all pressure points were cushioned and the patient secured, the abdomen and flank were prepped and draped in the usual sterile fashion. At this point, the antimicrobial drape was removed and the area that had been covered was re-prepped. A right radical nephrectomy was performed in essentially identical fashion. However, to assist in retraction of the liver, an additional 5-mm trocar was placed in the superior aspect of the GelPoint system. The triangular ligament of the liver was incised by using the Harmonic scalpel. Once the liver was fully reflected, the duodenum was Kocherized using blunt dissection to expose the renal hilum.

After delivery of the right kidney and assurance of adequate hemostasis, the fascia was closed with a synthetic absorbable suture. The subcutaneous tissue was irrigated and closed, and the skin was closed with a 4-0 monofilament subcuticular closure after instillation of local anesthetic.

RESULTS

The patient tolerated the procedure without difficulty. Intraoperatively, he received 2000cc of crystalloid fluid with an estimated blood loss of 50cc. Total operative time was 123 minutes. His hospital course was unremarkable, and he was discharged home on postoperative day 2. Since then, there have been no complications, and follow-up visits demonstrate excellent cosmesis (**Figure 3**). Pathology revealed multifocal papillary type I renal cell carcinoma in both kidneys. Margins were negative, and the largest single tumor on the left measured 3cm, yielding a pathologic stage of pT1a.

DISCUSSION

Bilateral nonfamilial synchronous renal masses comprise up to 3% of patients presenting with enhancing renal masses.^{1,2} A recent analysis of the Surveillance Epidemiology and End Results (SEER) Registries Database found that 99% of patients presenting with bilateral enhancing

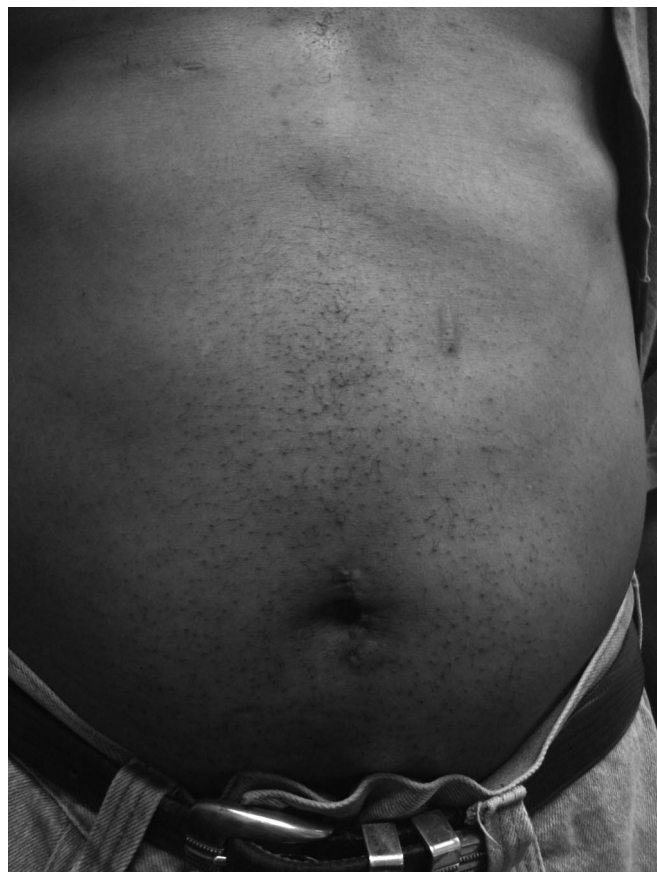

Figure 3. Cosmetic appearance of 5-cm periumbilical incision 6 weeks after surgery.

masses had bilateral renal cell carcinoma.³ A review of the Fox Chase Cancer Center registry indicated that 83% of patients presenting with bilateral masses had malignant disease in at least one renal unit, and of those patients, 95% had malignant disease in both kidneys,³ highlighting the need to consider surgical removal of all masses. The ideal management of bilateral masses is controversial, with some advocating a staged approach and others a simultaneous approach.

Herein, we present a novel management solution to the dilemmas created by bilateral renal masses. Bilateral laparoscopic nephrectomies have been described^{4,5} but have several downsides compared to single-port surgery. For traditional laparoscopy, multiple ports are required for each nephrectomy, so after performing the first nephrectomy and changing positions, additional ports need to be placed. Removing the ports and replacing them through the same site can be challenging. On the other hand, if the same ports are left *in situ* on both nephrectomies, maintaining sterility can be difficult. The single-port system is an ideal solution for these problems. No new access is required after changing positions, and maintaining sterility is simplified by easy removal and replacement of the single-port system.

Traditional laparoscopy for bilateral nephrectomy often includes a hand port for assistance in dissection as well as removal of the specimen.^{4,5} The length of the hand port is typically at least 7cm to accommodate the surgeon's hand and arm compared to the 6-cm fascial incision that can be used to perform LESS nephrectomy. Even if a hand port is not used for dissection, the kidneys need to be extracted through a larger fascial incision, either in the midline or in the suprapubic region. The single-port approach simplifies the surgery by allowing for specimen removal from the same incisions used for dissection.

We have performed 3 cases each of laparoscopic and hand-assisted laparoscopic (HAL) bilateral nephrectomies. For HAL, our experience is the same as that in the literature; namely, the hand port is at least 7cm to 8cm no matter the size of the kidneys. We have found that the procedure can be done safely with pure laparoscopy but that additional ports are necessary and a separate fascial incision and extraction site has to be created at the end of the case, resulting in a slightly longer operative time. An alternative is to place all the ports midline. This is a technically more challenging procedure than the traditional configuration, though to an extent demanding ergonomics is a feature of LESS as well. The fascial incision may be smaller with this technique, although it can be

difficult enough to remove kidneys, even atrophic ones, through the 6-cm fasciotomy we use for LESS.

Potential benefits of the single-port approach include improved pain control and cosmesis compared to traditional laparoscopy. However, these subjects have not been adequately studied. Similarly, we do not know of any definitive differences in operative time, estimated blood loss, length of stay, or complication rates between the 2 approaches, although initial reports of single-port surgery suggest it is not less safe than traditional laparoscopy.⁶⁻⁸ Additionally, there has been no economic analysis to determine the cost-effectiveness of the GelPoint device (\$525.00).

CONCLUSION

In this report of the first use of LESS for bilateral nephrectomies, we demonstrate the feasibility and safety of this technique in select patients.

References:

1. Patel MI, Simmons R, Kattan MW, et al. Long-term follow-up of bilateral sporadic renal tumors. *Urology*. 2003;61(5):921-925.
2. Richstone L, Scherr DS, Reuter VR, et al. Multifocal renal cortical tumors: frequency, associated clinicopathological features and impact on survival. *J Urol*. 2004;171(2 Pt 1):615-620.
3. Rothman J, Crispin PL, Wong YN, Al-Saleem T, Fox E, Uzzo RG. Pathologic concordance of sporadic synchronous bilateral renal masses. *Urology*. 2008;72(1):138-142.
4. Ilbeigi P, Brison D, Sadeghi-Nejad H. Synchronous bilateral laparoscopic radical nephrectomy for solid renal masses using a hybrid approach. *Urol J*. 2008;5(3):192-196.
5. Desai PJ, Castle EP, Daley SM, et al. Bilateral laparoscopic nephrectomy for significantly enlarged polycystic kidneys: a technique to optimize outcome in the largest of specimens. *BJU Int*. 2008;101(8):1019-1023.
6. Desai MM, Berger AK, Brandina R, et al. Laparoendoscopic single-site surgery: initial hundred patients. *Urology*. 2009;74(4):805-812.
7. Canes D, Berger A, Aron M, et al. Laparo-endoscopic single site (LESS) versus standard laparoscopic left donor nephrectomy: matched-pair comparison. *Eur Urol*. 2010;57(1):95-101.
8. Gimenez E LD, Wyshock JS, Charlton M, Kapur S, Del Pizzo JJ. Laparoendoscopic single site live donor nephrectomy: initial experience. *J Urol*. 2010;184(5):In press.