

Ultrasound-Guided Fine-Needle Aspiration Biopsy of Thyroid Nodules Smaller Than 5 mm in the Maximum Diameter: Assessment of Efficacy and Pathological Findings

Dong Wook Kim, MD¹
Auh Whan Park, MD¹
Eun Joo Lee, MD¹
Hye Jung Choo, MD¹
Sang Hyo Kim, MD²
Sang Hyub Lee, MD²
Jae Wook Eom, MD³

Index terms :

Thyroid, nodule
Fine-needle biopsies
Ultrasound (US)
Microcarcinoma

DOI:10.3348/kjr.2009.10.5.435

Korean J Radiol 2009; 10: 435-440

Received October 9, 2008; accepted after revision March 17, 2009.

¹Department of Radiology; ²Department of General Surgery (Thyroid and Breast Clinic); ³Department of Otorhinolaryngology-Head and Neck Surgery, Busan Paik Hospital, Inje University College of Medicine, Busan 614-735, Korea

Address reprint requests to:

Dong Wook Kim, MD, Department of Radiology, Busan Paik Hospital, Inje University College of Medicine, Busan 614-735, Korea.
Tel. (8251) 890-6549
Fax. (8251) 896-1085
e-mail: dwultra@lycos.co.kr

Objective: The aim of this study was to determine the efficacy of the use of an ultrasound-guided fine-needle aspiration biopsy (US-FNAB) to diagnose thyroid nodules smaller than 5 mm in the maximum diameter and to evaluate pathological findings of small thyroid malignancies.

Materials and Methods: From May 2007 to April 2008, we evaluated the findings of US-FNABs of small thyroid nodules less than 5 mm in the maximum diameter. The cytopathological findings were retrospectively reviewed and the diagnostic performance of the use of an US-FNAB was examined in all patients.

Results: Of 201 small thyroid nodules in 180 patients, there were 162 adequate specimens (81%). Among 180 patients, 75 patients underwent thyroid surgery and 50 malignant and 33 benign nodules were identified based on a pathological examination. All small malignant thyroid nodules were identified as papillary thyroid microcarcinomas (PTMCs). There were 34 (55%) true positive, 0 (0%) false positive, 23 (37%) true negative and five (8%) false negative results for malignancy after performing a first US-FNAB in 62 surgically confirmed nodules. The sensitivity (87%), specificity (100%), positive predictive value (100%), negative predictive value (82%), accuracy (92%), false positive rate (0%) and false negative rate (8%) for an US-FNAB were determined. In 23 patients with a primary PTMC, capsular invasion (9%, 2 of 23), a perithyroidal lymph node metastasis (30%, 7 of 23), the rate of multifocality (9%, 2 of 23) and bilaterality (4%, 1 of 23) were also determined.

Conclusion: An US-FNAB of thyroid nodules smaller than 5 mm in the maximum diameter is an effective diagnostic procedure.

An ultrasound-guided fine-needle aspiration biopsy (US-FNAB) is widely accepted as an effective, simple and safe method for the diagnosis of head and neck lesions, including thyroid nodules. A thyroid carcinoma less than 10 mm in diameter is termed as a 'microcarcinoma' and a papillary thyroid carcinoma (PTC) less than 10 mm in diameter is termed as a 'papillary thyroid microcarcinoma (PTMC)' according to a classification by the World Health Organization (1). To the best of our knowledge, there have been only a few reports that have evaluated the efficacy of an US-FNAB for small thyroid nodules less than 10 mm in the maximum diameter (2-4). If there is a guarantee regarding the high efficacy of an US-FNAB, low cost and no difficulty to perform the procedure for small thyroid nodules, routine use of US-FNABs is likely to be adopted for the diagnosis of thyroid

nodules that are smaller than 10 mm in the maximum diameter. However, no studies regarding the efficacy of an US-FNAB for large numbers of small thyroid nodules less than 5 mm in the maximum diameter have been performed and only a few reports have evaluated the use of an US-FNAB for thyroid nodules smaller than 10 mm in diameter. Nam-Goong et al. (4) have reported the efficacy of an US-FNAB for 25 small thyroid nodules less than 5 mm in diameter; the investigators determined a 64% adequacy rate for the use of an US-FNAB.

The aim of this study was to determine the efficacy of an US-FNAB to diagnose thyroid nodules smaller than 5 mm in the maximum diameter and to evaluate pathological findings for small malignant thyroid nodules.

MATERIALS AND METHODS

Patient Selection

Of thyroid nodules examined by the use of an US-FNAB at our institution from May 2007 to April 2008, small thyroid nodules less than 5 mm in the maximum diameter were included in the study. High-resolution ultrasonography (US) was performed with either an HDI 5000 (Phillips Medical Systems, Bothell, WA) or iU 22 unit (Phillips Medical Systems) using a 12–15 MHz linear probe for guidance during the US-FNAB procedure. We obtained informed written consent from all patients before performing US-FNABs and our institutional review board approved this study.

Malignant sonographic findings included microcalcifications, marked hypoechogenicity, an irregular margin and a taller-than-wide shape. The inclusion criteria for an US-

FNAB of small thyroid nodules less than 5 mm in the maximum diameter were the following. The criteria included a thyroid nodule with a likelihood of malignancy as depicted on diagnostic US ($n = 149$), a small solid thyroid nodule in the contralateral lobe in a patient with a known thyroid malignancy ($n = 41$) or the presence of a small solid nodule in patients at a high risk for having a thyroid malignancy ($n = 11$). Risk factors for a thyroid malignancy included cervical lymphadenopathy with a positive cytology for a thyroid malignancy ($n = 3$), prior head and neck irradiation ($n = 1$) and a newly developed nodule in the opposite or remaining thyroid lobe after surgery for a known thyroid malignancy ($n = 7$). A repeat US-FNAB was performed after the first biopsy whenever the cytology result was 'inadequate' or when the cytology result did not match the sonographic impression. A primary malignancy was defined as the largest malignant nodule in the thyroid and a satellite malignancy was defined as a smaller-sized, intraglandular metastatic lesion in the ipsilateral or contralateral lobe.

Fine Needle Aspiration Biopsy Technique

An experienced radiologist (seven years experience for performing an US-FNAB of thyroid nodules) performed an US-FNAB with the use of a 23-gauge needle attached to a 10-ml plastic syringe. Procedures were performed under US guidance using a perpendicular puncture and without local anesthesia. When the needle tip reached the target nodule, the needle was observed as a small echogenic spot within the nodule on the US monitor (Fig. 1). After the needle tip was placed in the appropriate area of the target nodule, sampling was commenced using the 'mixed

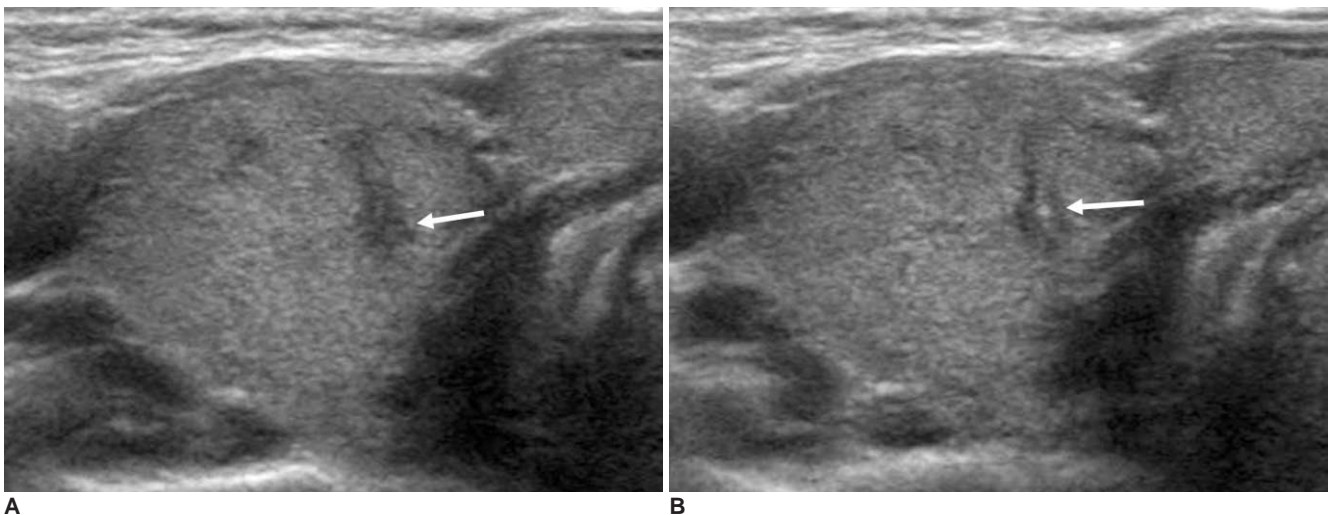


Fig. 1. Imaging findings are shown for solitary papillary thyroid microcarcinoma (approximately 3.0 mm in maximum diameter).

A. Transverse sonogram of right lobe of thyroid shows presence of markedly hypoechoic nodule (arrow) with ill-defined margin and taller-than-wide shape.

B. Transverse sonogram shows echogenic dot (arrow) within same nodule due to needle tip during US-fine needle aspiration biopsy.

sampling technique.' This technique is an individual sampling technique where the needle is moved up and down for a few seconds only by movement of the wrist of the operator and without initial aspiration under US guidance. In all cases, only one sampling by one puncture was taken from each nodule. After a sample was obtained, the specimen was mounted immediately onto a glass slide. We obtained four to six slides by performing two or three smears from each nodule. Specimens were fixed with 95% ethanol and were sent for pathological evaluation.

Cytopathological Examinations

The cytological diagnosis was classified as 'benign,' 'suspicious for a malignancy,' 'malignant,' 'indeterminate' or 'inadequate.' 'Benign' included a normal thyroid, nodular hyperplasia, lymphocytic thyroiditis or other benign conditions. 'Suspicious for a malignancy' included specimens showing clusters of atypical follicular cells with some nuclear grooves. 'Malignant' included specimens showing clusters of abnormal follicular cells with discrete nuclear grooves, intranuclear pseudoinclusions or a papillary projection. 'Indeterminate' referred to specimens showing follicular cell proliferative lesions that were indeterminate for a differential diagnosis of nodular hyperplasia, follicular neoplasm or a follicular variant of a PTC. In this study, an adequate specimen was defined as having more than six clusters of follicular thyroid cells and showing the presence of an identifiable colloid in each preparation (5); conversely, a specimen with less than six clusters of follicular thyroid cells in each slide was considered as 'inadequate.'

For each primary small malignancy, capsular invasion with tumor invasion into the thyroid capsule, a perithyroidal lymph node metastasis with tumor invasion into lymph nodes in the central neck, multifocality with an intraglandular metastasis in the ipsilateral lobe and bilaterality with an intraglandular metastatic lesion in the contralateral lobe were examined.

Diagnostic Performance

Of 201 small nodules in 180 patients, 118 small nodules in 110 patients were not removed surgically and these nodules were excluded from the determination of diagnostic indices. Of 83 nodules in 75 patients, lesions with 'benign' cytology were regarded as having a negative cytology classification for a malignancy and lesions with 'suspicious for a malignancy' or 'malignant' cytology were regarded as having a positive cytology classification for a malignancy. Lesions with an 'indeterminate' (n = 7) and 'inadequate' (n = 14) cytology as determined after the first US-FNAB were excluded in the determination of the

sensitivity, specificity, predictive value, accuracy, false positive rate and false negative rate. Ultimately, of 62 nodules in 58 patients, the sensitivity, specificity, positive predictive value, negative predictive value, accuracy, false positive rate and false negative rate for the first US-FNAB were examined.

RESULTS

Of 201 small thyroid nodules (maximum diameter range, 1.0 to 5.0 mm; mean diameter, 3.4 mm) in 180 patients (female:male = 152:28; mean age, 48.0 years; age range, 18 to 75 years), the incidence of adequate specimens was 162 (81%) after the first US-FNAB. Of 201 biopsies, the cytology was classified as 'benign' for 107 lesions (53%), 'suspicious for a malignancy' for 22 lesions (11%), 'malignant' for 16 lesions (8%), 'indeterminate' for 17 lesions (9%) and 'inadequate' for 39 lesions (19%) (Table 1).

Seventy-five patients with 86 thyroid nodules underwent thyroid surgery. Of the 75 patients, 41 patients underwent a total thyroidectomy, 21 patients underwent a lobectomy, 12 patients underwent a subtotal thyroidectomy and one patient underwent an isthmectomy. Fifty small malignant thyroid nodules in 49 patients (female:male = 44:5; mean age, 44.2 years; mean maximum diameter, 3.3 mm;

Table 1. Cytopathological Results of Thyroid Nodules Smaller Than 5 mm in Maximum Diameter

Cytology	Lesion Number (%)	Operated Lesion Number (%)	Malignant Number (%)
Benign	107 (54)	28 (34)	5 (10)
Suspicious for malignancy	22 (11)	19 (23)	19 (38)
Malignant	16 (8)	15 (18)	15 (30)
Indeterminate	17 (9)	7 (8)	4 (8)
Inadequate	39 (19)	14 (17)	7 (14)
Total	201	83	50

Table 2. Diagnostic Performance of US-Fine Needle Aspiration Biopsy on 62 Thyroid Nodules Smaller Than 5 mm in Maximum Diameter

Index	Incidence (%)
Sensitivity	34/39 (87)
Specificity	23/23 (100)
Positive predictive value	34/34 (100)
Negative predictive value	23/28 (82)
Accuracy	57/62 (92)
False negative	5/62 (8)
False positive	0 (0)

maximum diameter range, 1.0 to 5.0 mm) were identified as PTMCs based on a pathological examination and were classified as 23 (46%) primary and 27 (54%) satellite (smaller-sized PTCs that are distinguished from the largest PTC) malignancy. Thirty-three small thyroid nodules with 'benign' cytology in 33 patients showed 28 nodular hyperplasias and five PTMCs on the pathology after thyroid surgery.

Of the 23 pathologically confirmed primary malignancies, after the first US-FNAB two lesions (9%) were classified as 'benign,' eight lesions (35%) were classified as 'suspicious for a malignancy,' 10 lesions (44%) were classified as 'malignant,' two lesions (9%) were classified as 'indeterminate' and one lesion (4%) was classified as 'inadequate' based on the cytology. Of five (two benign, two indeterminate, and one inadequate) pathologically confirmed primary malignant nodules with negative cytology results after the first biopsy, four lesions were classified as 'suspicious for a malignancy' after a second biopsy and one lesion was classified as 'benign' after a second biopsy. Although one pathologically confirmed malignant nodule demonstrated negative cytology results even after two consecutive US-FNABs, the patient underwent thyroid surgery because of the high likelihood of a malignancy as found on diagnostic US.

Of the 27 pathologically confirmed satellite malignancies after the first US-FNAB, three lesions (11%) were classified as 'benign,' 10 lesions (37%) were classified as 'suspicious for a malignancy,' six lesions (22%) were classified as 'malignant,' two lesions (7%) were classified as 'indeterminate' and six lesions (22%) were classified as 'inadequate' based on the cytology. Eleven satellite malignant nodules that showed a negative cytology after the first biopsy were surgically removed without an additional biopsy as they showed a combined primary thyroid malignancy on simultaneous US-FNABs.

For the first US-FNAB of 62 nodules, there were 34 (55%) true positives, 0 (0%) false positives, 23 (37%) true negatives and five (8%) false negatives. The sensitivity (87%), specificity (100%), positive predictive value (100%), negative predictive value (82%), accuracy (92%), false positive rate (0%) and false negative rate (8%) after an US-FNAB for nodules smaller than 5 mm in the maximum diameter were determined (Table 2).

Twenty-three patients with a primary PTMC smaller than 5 mm in the maximum diameter underwent thyroid surgery. Capsular extension (9%, 2 of 23), a perithyroidal lymph node metastasis (30%, 7 of 23), multifocality (9%, 2 of 23) and bilaterality (4%, 1 of 23) were identified. Thyroid surgery for these patients included a total thyroidectomy (n = 7), a subtotal thyroidectomy (n = 4)

and a lobectomy (n = 12).

Twenty-one patients (12%, 21 of 180) experienced mild pain that persisted for several minutes during or after the biopsy, but the pain subsided spontaneously without medication. Major complications such as significant hemorrhage or a secondary infection were not observed.

DISCUSSION

US-FNAB is the least invasive, most simple and most accurate method to evaluate a thyroid nodular lesion. However, the size criterion is still controversial for thyroid nodules evaluated on an US-FNAB. The American Thyroid Association (ATA) guidelines suggest that, in general, only nodules larger than 10 mm in diameter should be evaluated as the nodules have the potential to represent a clinically significant cancer (6). Occasionally, there may also be nodules less than 10 mm in the maximum diameter that require evaluation due to suspicious US findings and/or a patient history of thyroid cancer (7). The Society of Radiologists in Ultrasound Consensus Statement suggests performing US-FNAB on thyroid nodules 10 mm or greater in the maximum diameter when the nodules exhibit microcalcifications or other US features associated with thyroid cancer, as an early diagnosis of thyroid cancer does not guarantee a decrease in recurrence or the mortality rate (8). Burman (9) also mentioned that irrespective of which suggested minimum measurement or guideline is used, the most critical requirement is to monitor these patients with periodic clinical and US examinations. However, many authorities suggest that it is important to diagnose thyroid cancer at an early stage to reduce the risk of recurrence or mortality (10, 11).

There are a few reports that have evaluated the use of an US-FNAB of thyroid nodules less than 5 mm in the maximum diameter. Nam-Goong et al. (4) found a 64% adequate sampling rate for 25 small thyroid nodules less than 5 mm in diameter, but the study did not indicate whether the maximum or minimum diameter of the nodules had been measured. Roti et al. (12) retrospectively analyzed 243 patients with pathologically confirmed PTMCs, but the investigators did not comment on the adequacy or efficacy of US-FNABs for the thyroid nodules.

In this study, the sensitivity and negative predictive value of performing an US-FNAB for the diagnosis of small thyroid nodules equal to or less than 5 mm in the maximum diameter were relatively low as compared with values obtained for other diagnostic indices; however, the specificity and positive predictive value were high. To the

best of our knowledge, these are the highest rates among previously published reports, although the sensitivity and negative predictive value of an US-FNAB for small-diameter thyroid nodules were 87% and 82%, respectively. However, five 'benign' nodules identified after the first US-FNAB were later confirmed as PTMCs after thyroid surgery and were determined as false negative cytologies (8%), but false positive cytology was not detected. This false negative rate for an US-FNAB of small thyroid nodules less than 5 mm in the maximum diameter is relatively high; however, this rate may be subject to change if non-operated nodules are surgically confirmed. The size of the five PTMCs with false negative cytology as determined after the first US-FNAB was less than 3 mm in the maximum diameter as determined on diagnostic US. Therefore, we assumed that the relatively high false negative rate was due to sampling of primarily normal tissue rather than the PTMC during the 'to-and-fro' cell acquisition.

In the present study, the incidence of capsular invasion of a PTMC smaller than 5 mm in the maximum diameter was 9% (2 of 23), which was relatively low as compared to the studies of Roti et al. (12) and Chow et al. (13). Roti et al. (12) reported that two patients (2%, 2 of 86) with thyroid cancers less than 5 mm had regional lymph node metastases, but in the present study, 23 primary PTMCs equal to or less than 5 mm in the maximum diameter showed a perithyroidal lymph node metastasis (30%, 7 of 23). We presume that the high rate of a perithyroidal lymph node metastasis in the present study might be associated with the relatively high incidence of the subcapsular location of PTMCs. Regarding the multifocality of a PTMC, Roti et al. (12) and Chow et al. (13) reported that 32% (78 of 243) and 31% (63 of 203) of patients were identified with multifocal lesions, respectively, but the investigators in both studies did not describe PTMCs less than 5 mm in the maximum diameter. Roti et al. (12) found that the incidence rate of bilaterality of a PTMC was 19% (45 of 243), but the investigators did not separately mention the bilaterality rate of a PTMC less than 5 mm in the maximum diameter. In the present study, multifocality (9%, 2 of 23) and bilaterality (4%, 1 of 23) were identified. To the best of our knowledge, no large-scale study has examined the incidence of regional lymph node metastases, multifocality and bilaterality of a PTMC less than 5 mm in the maximum diameter.

In our study, significant complications related to performing an US-FNAB were not detected in any of the patients. Several factors have been associated with a low incidence of complications with the use of the US-FNAB procedure, including one sampling with one puncture,

shortening of the procedure time, accurate targeting and watching the needle tip during the biopsy. In particular, continuous watching of the needle tip on the US monitor during the entire procedure is important in order to prevent arterial injury to the carotid or vertebral artery.

This study has several limitations. First, this study was not a large-scale study. Second, thyroid surgery for the thyroid malignancies included total, subtotal and a lobectomy and regional lymph node resection was not performed for all of the PTCs. Third, we did not consider if the presence of underlying diffuse thyroid disease influenced the outcome of the US-FNABs. Ceresini et al. (14) have suggested that in cases of underlying diffuse thyroid disease, such as thyroiditis or diffuse goiter, the outcome of an US-FNAB for small thyroid nodules might have resulted in an negative influence. Finally, our technique of performing an US-FNAB of thyroid nodules is not a standard technique.

The importance of early diagnosis of thyroid cancer in patients at low risk remains uncertain as thyroid cancers are typically slow growing and are associated with a low morbidity and mortality (6, 8, 15). However, we believe that early diagnosis of thyroid malignancies less than 5 mm in the maximum diameter by the use of diagnostic US and an US-FNAB is helpful to improve patient morbidity rates for poorly differentiated thyroid malignancies. In addition, in our study, the diagnosis of 27 satellite small PTMCs after an US-FNAB influenced the decision regarding the type of thyroid surgery (e.g., a lobectomy or total thyroidectomy).

In conclusion, an US-FNAB of thyroid nodules smaller than 5 mm in the maximum diameter is an effective diagnostic method if performed by an experienced radiologist. In the present study, primary PTMCs smaller than 5 mm in the maximum diameter had a low incidence of capsular invasion, multifocality and bilaterality, but a relatively high incidence of perithyroidal lymph node metastases.

Acknowledgements

This work was supported by the Busan Paik Hospital Imaging Research Institute.

References

1. Hedinger C, Williams ED, Sobin LH. *Histological typing of thyroid tumours. International histological classification of tumours. World Health Organization*, 2nd ed. Berlin: Springer-Verlag, 1988
2. Leenhardt L, Hejblum G, Farnic B, Fediaevsky LD, Delbot T, Le Guillouez D, et al. Indications and limits of ultrasound-guided cytology in the management of nonpalpable thyroid nodules. *J Clin Endocrinol Metab* 1999;84:24-28

3. Kim SJ, Kim EK, Park CS, Chung WY, Oh KK, Yoo HS. Ultrasound-guided fine-needle aspiration biopsy in nonpalpable thyroid nodules: is it useful in infracentimetric nodules? *Yonsei Med J* 2003;44:635-640
4. Nam-Goong IS, Kim HY, Gong G, Lee HK, Hong SJ, Kim WB, et al. Ultrasonography-guided fine-needle aspiration of thyroid incidentaloma: correlation with pathological findings. *Clin Endocrinol (Oxf)* 2004;60:21-28
5. Baloch ZW, Sack MJ, Yu GH, Livolsi VA, Gupta PK. Fine-needle aspiration of thyroid: an institutional experience. *Thyroid* 1998;8:565-569
6. Gharib H, Papini E, Valcavi R, Baskin HJ, Crescenzi A, Dottorini ME, et al. American Association of Clinical Endocrinologists and Associazione Medici Endocrinologi medical guidelines for clinical practice for the diagnosis and management of thyroid nodules. *Endocr Pract* 2006;12:63-102
7. Cooper DS, Doherty GM, Haugen BR, Kloos RT, Lee SL, Mazzaferri EL, et al. Management guidelines for patients with thyroid nodules and differentiated thyroid cancer. *Thyroid* 2006;16:109-142
8. Frates MC, Benson CB, Charboneau JW, Cibas ES, Clark OH, Coleman BG, et al. Management of thyroid nodules detected at US: Society of Radiologists in Ultrasound consensus conference statement. *Radiology* 2005;237:794-800
9. Burman KD. Micropapillary thyroid cancer: should we aspirate all nodules regardless of size? *J Clin Endocrinol Metab* 2006;91:2043-2046
10. Mazzaferri EL, Kloos RT. Clinical review 128: Current approaches to primary therapy for papillary and follicular thyroid cancer. *J Clin Endocrinol Metab* 2001;86:1447-1463
11. Baskin HJ, Duick DS. The endocrinologists' view of ultrasound guidelines for fine needle aspiration. *Thyroid* 2006;16:207-208
12. Roti E, Rossi R, Trasforini G, Bertelli F, Ambrosio MR, Busutti L, et al. Clinical and histological characteristics of papillary thyroid microcarcinoma: results of retrospective study in 243 patients. *J Clin Endocrinol Metab* 2006;91:2171-2178
13. Chow SM, Law SC, Chan JK, Au SK, Yau S, Lau WH. Papillary microcarcinoma of the thyroid-Prognostic significance of lymph node metastasis and multifocality. *Cancer* 2003;98:31-40
14. Ceresini G, Corcione L, Morganti S, Milli B, Bertone L, Prampolini R, et al. Ultrasound-guided fine-needle capillary biopsy of thyroid nodules, coupled with on-site cytologic review, improves results. *Thyroid* 2004;14:385-389
15. Ito Y, Urano T, Nakano K, Takamura Y, Miya A, Kobayashi K, et al. An observation trial without surgical treatment in patients with papillary microcarcinoma of the thyroid. *Thyroid* 2003;13:381-387