

# Outcomes of laparoscopic donor nephrectomy in the presence of multiple renal arteries

Anil Kapoor, Shahid Lambe, Ashley L. Kling<sup>1</sup>, Kevin R. Piercey, Paul J. Whelan

Department of Renal Transplant, McMaster Institute of Urology, <sup>1</sup>Department of Surgery, McMaster University, Canada

## Abstract

**Purpose:** Data of laparoscopic donor nephrectomy (LDN) with multiple renal arteries for donor and recipient outcomes were reviewed, with the aim of clarifying whether the laparoscopic approach is safe in the presence of multiple renal arteries.

**Materials and Methods:** All donor nephrectomies performed at our institution from 2004 to 2008 were reviewed retrospectively. Results were compared between LDN kidneys with multiple arteries and those with a single renal artery.

**Results:** Out of 171 donor nephrectomies, 21 (12%) were performed for kidneys with multiple renal arteries. All of the 150 (88%) donor nephrectomies in the single vessel group were performed laparoscopically. In the multiple artery group, 9 (43%) underwent an open procedure while 12 (57%) underwent a laparoscopic procedure. The warm ischemia time was longer in the multiple artery group than the single artery group, but the difference was not statistically significant ( $4.25 \pm 0.87$  min vs.  $4.12 \pm 0.95$  min, respectively). Regarding transplant recipients, the vascular anastomosis time was similar in both groups ( $30 \pm 4.6$  min vs.  $29.5 \pm 3.7$  min). The operative blood loss in the transplant recipients was significantly more in the multiple artery group compared to the single artery group ( $339 \pm 292$  ml and  $130.7 \pm 44.8$  ml, respectively;  $P=0.03$ ). The recipient renal function was similar for both the groups at postoperative day 7, 1 month, and at 1 year.

**Conclusion:** The data support the fact that the laparoscopic approach to donor nephrectomy in the presence of multiple renal arteries can be performed safely with adequate laparoscopic experience.

**Key Words:** Laparoscopic donor nephrectomy, multiple renal arteries, outcomes, single renal artery

## Address for correspondence:

Dr. Anil Kapoor, St. Joseph's Healthcare Hamilton, McMaster Institute of Urology, 50 Charlton Ave. E., Room G344, Hamilton, ON, Canada.

E-mail: akapoor@mcmaster.ca

Received: 25.10.2010, Accepted: 12.01.2011

## INTRODUCTION

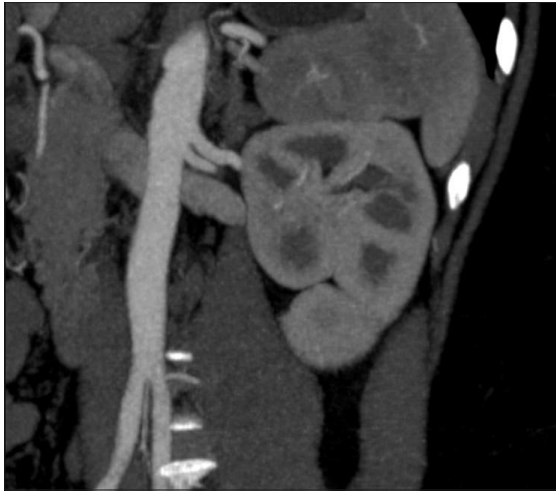
Since its first description in 1995,<sup>[1]</sup> laparoscopic donor nephrectomy (LDN) has gained widespread acceptance. The presence of multiple renal arteries in donors can pose a

challenge for the surgeon. The multiplicity of the renal artery in donors may have an adverse effect not only on the safety of donors, but also on graft outcomes. The aim of this study was to evaluate our LDN experience for donors with multiple arteries and their recipient outcomes.

## MATERIALS AND METHODS

From January 2004 to December 2008, a total of 171 patients underwent donor nephrectomy at our institution. Preoperative donor evaluation was done to evaluate medical, surgical, and psychosocial suitability for living donation. Imaging studies for assessing the renal vascular anatomy were done by three-dimensional computed tomography scanning [Figure 1]. LDN

Access this article online	
Quick Response Code:	Website: www.urologyannals.com
	DOI: 10.4103/0974-7796.82169



**Figure 1:** Preoperative computed tomography angiogram showing left kidney with two renal arteries

was performed using operative technique as described.

### Operative procedure

After anesthetic induction and Foley placement, a Pfannenstiel incision was marked 3–4 cm cephalad to the pubic bone. The patient was positioned in a “flank-up” position (with 45° tilt to horizontal). The patient was then secured with adhesive tapes, ensuring adequate padding on the bony prominences. A “bean bag” was also used to keep the patient in the desired position. The table was then flexed. Pneumoperitoneum was established by placing an infraumbilical Veress needle. The trocars were placed as follows: A 10-mm Optiview trocar (Ethicon EndoSurgery, Cincinnati, OH, USA) was used for the camera at the lateral border of the rectus muscle in the midclavicular line, 4–5 cm superiorly and laterally to umbilicus. A 5-mm port, a few centimeters below the costal margin, was used for the dissecting forceps while another 10-mm port was placed for the suction cautery lateral to the umbilicus and at an adequate distance to the camera port.

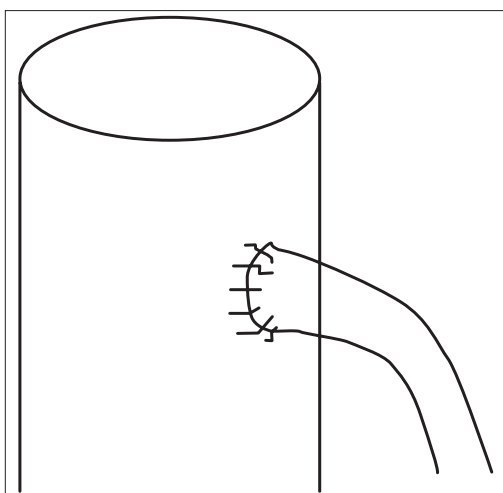
After adequate port placement, the descending colon and the splenic flexure were mobilized. The ureter was then identified and mobilized up to the pelvic brim, ensuring that the periureteric sheath was intact. The gonadal, adrenal, and lumbar tributaries of the renal vein were identified, clipped, and cut. Attention was then turned toward the upper pole, where Gerota’s fascia was incised and the adrenal gland was dissected off the upper pole of the kidney. The kidney was also freed laterally. The renal vein was mobilized completely and a right-angled dissector was placed behind the renal vein to ensure that it was completely freed all around. The renal artery was exposed and dissected for an adequate length until the aorta. Any secondary renal arteries were also dissected carefully until the aorta. The kidney was thus completely mobilized all around, leaving only vascular structures attached at the hilum.

A small modified Pfannenstiel incision was then made (muscle-splitting). The peritoneum was left intact, through which a 12-mm port with a specimen bag was passed into the abdomen. This closed specimen bag also aids in retracting the structures medial to the hilum, thus ensuring proper exposure. The ureter was clipped near the iliac vessels and cut. At this point, an additional 5-mm port was inserted laterally to aid in retracting the kidney laterally. The renal artery was occluded with three metal clips and sharply cut above the clips. The renal vein was secured with a vascular stapler; the lateral retraction of the kidney at this point allows the surgeon to gain length on the renal vein. The kidney was retrieved through the Pfannenstiel incision using the specimen bag and handed over for irrigation. After closing the peritoneal rent with 2-0 polyglactin and ensuring a good pneumoperitoneum, the renal hilar structures were visualized. Laparoscopic inspection was done at a low level of pneumoperitoneum to check for hemostasis. A Carter-Thomason device was used for closing the 10-mm ports with 1 polyglactin. The Pfannenstiel extraction incision was closed using 1 polyglactin for the fascia. The skin incision was then approximated using staples or a subcuticular suture.

The recipients underwent the transplantation procedure using the standard extraperitoneal approach with end-to-side anastomosis of donor renal vessels to recipient external iliac vessels. We routinely perform the bench reconstruction prior to the recipient procedure so this had no bearing on the operative time for the recipients. In the case of size discrepancy between the multiple renal arteries, the smaller vessel was end-to-side anastomosed using interrupted 6-0 prolene sutures to the larger sized artery [Figure 2]. If the arteries were of equal caliber, then both were joined together in a double-barrel fashion [Figure 3]. The charts were reviewed retrospectively for all LDNs and their recipients. The donors and recipients were categorized into two groups according to the number of arteries in the donors (one or two). Donor outcomes were evaluated for warm ischemia time, estimated blood loss, and complication rates, while recipients were evaluated for estimated blood loss, vascular anastomosis time, and postoperative creatinine at 1 week, 1 month, and 1 year. Recipients also underwent a renal scan (TcDTPA) at postoperative day 1. Statistical analysis was done using the two-tailed Student’s *t*-test and Fisher’s exact test. A *P* value < 0.05 was considered statistically significant.

### RESULTS

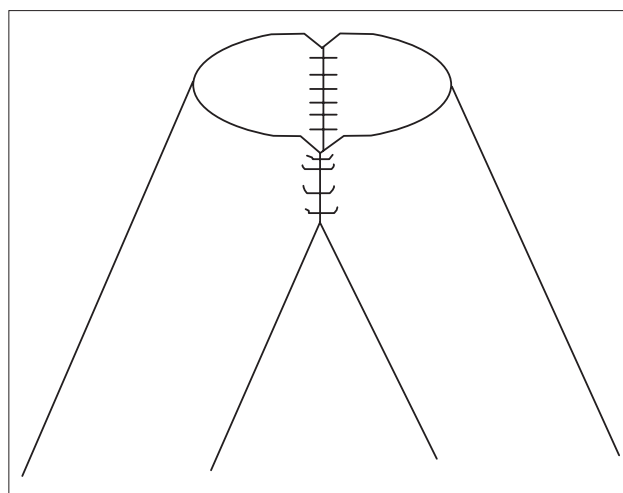
Of the 171 donor nephrectomies, 21 (12%) were performed for kidneys with multiple arteries. Out of the 150 (88%) donor nephrectomies in the single vessel group, all were performed laparoscopically. In the multiple artery group (21), 9 (43%) underwent an open right procedure, while 12 (57%) underwent the procedure laparoscopically. The nine patients



**Figure 2:** End-to-side vascular reconstruction

in the multiple artery group underwent open right donor nephrectomy due to the fact that on preoperative imaging these patients were found to have three left renal arteries and two right renal arteries. The laparoscopic procedure was not attempted in these patients as this was done on the right side and maximal venous length could be gained. Of the 12 patients who underwent laparoscopic left donor nephrectomy, 10 patients had bilateral double renal arteries and 2 patients had three right renal arteries with two left renal arteries on preoperative imaging [Table 1]. There were no conversions to the open procedure in this group. Of the 21 patients in the multiple vessel group, 52% were males while 48% were females. In the single vessel group, out of 150 patients 54% were males while 46% were females.

The results were compared between LDN kidneys with a single artery and multiple renal arteries [Table 2]. In the donors, the operative time was  $182 \pm 25$  min in the single artery group while it was  $184 \pm 18$  min in the multiple artery group. The warm ischemia time was longer in the multiple artery group but the difference was not statistically significant ( $4.25 \pm 0.87$  min and  $4.12 \pm 0.95$  min, respectively). There were no complications reported in the donors. In the recipients, the vascular anastomosis time was similar in both the groups ( $29.5 \pm 3.7$  min and  $30 \pm 4.6$  min, single artery and multiple arteries groups respectively). The operative blood loss in the transplant recipients was significantly more in the multiple artery group compared to the single artery group ( $339 \pm 292$  ml and  $130.7 \pm 44.8$  ml, respectively;  $P=0.03$ ). The recipient renal function was similar for both the groups single artery and multiple arteries groups at postoperative day 7 ( $112.7 \pm 30.3$   $\mu\text{mol/l}$  and  $118.83 \pm 30.54$   $\mu\text{mol/l}$ ), at 1 month ( $114.22 \pm 28.39$   $\mu\text{mol/l}$  and  $110.33 \pm 18.06$   $\mu\text{mol/l}$ ), and at 1 year ( $117.1 \pm 40.5$   $\mu\text{mol/l}$  and  $123.83 \pm 29.74$   $\mu\text{mol/l}$ ). The renal



**Figure 3:** Double-barrel vascular reconstruction

**Table 1: Number of arteries in the multiple vessel group (n=21)**

	Open right donor nephrectomy (n=9)	Laparoscopic left donor nephrectomy (n=12)
Preoperative imaging	3 left renal arteries, 2 right renal arteries	Bilateral double renal arteries (n=10) 2 left renal arteries, 3 right renal arteries (n=2)

**Table 2: Donor and recipient outcomes in laparoscopic donor nephrectomy (LDN) with single and multiple renal arteries**

		Single artery (n=150)	Multiple artery (n=12)	P value
Donor outcome	Mean warm ischemia time (min)	4.12±0.95	4.25±0.87	0.65
	Mean operative time (min)	182±25	184±18	0.56
Recipient outcome	Mean blood loss (ml)	130.73	339.58	0.03
	Mean vascular anastomosis time (min)	29.5±3.7	30±4.6	0.73
	Mean creatinine, 1 week ( $\mu\text{mol/l}$ )	112.76	118.83	0.52
	Mean creatinine, 1 month ( $\mu\text{mol/l}$ )	114.22	110.33	0.51
	Mean creatinine, 1 year ( $\mu\text{mol/l}$ )	117.11	123.83	0.48

scan (TcDTPA) of recipients with multiple renal arteries showed global perfusion of the graft, adequate function, and excretion. Intraoperative complications were seen in two recipients with multiple renal arteries. One patient had thrombosis of the lower pole vessel which required exploration and embolectomy using a Fogarty balloon. One patient had bleeding from the vascular anastomosis of the two renal arteries which required further sutures with 6.0 prolene. Two recipients in the multiple artery group had postoperative medical complications (one antibody-mediated rejection and one acute rejection). No intraoperative complications occurred in the recipient group with a single renal artery. Postoperative complications occurred in 8 of 150 recipients with a single renal artery, of which 6 were medical (3 acute

rejection, 2 antibody-mediated rejection, and 1 BK virus nephropathy) and 2 were surgical (2 wound infections).

## DISCUSSION

LDN has a substantial learning curve; however, with increasing experience it has advanced to involve more complex procedures.<sup>[2]</sup> LDN of kidneys with multiple arteries poses a unique challenge to the surgeon as it often requires complex procurement and reconstruction strategies. The incidence of unilateral multiple renal arteries in this study was 12%, which is less than that described in the literature (18–30%).<sup>[3]</sup> Also, the left kidney has been described to have a significantly higher rate of multiple arteries.<sup>[4,5]</sup> The presence of multiple renal arteries in LDN is thus not an uncommon clinical problem. Surgeons, especially those still gaining experience, are reluctant to harvest a kidney with multiple arteries. Vascular complications that have been described for multiple renal arteries include graft thrombosis, renal artery stenosis, and increased risk of renovascular hypertension.<sup>[6]</sup> In this study, one recipient in the multiple artery group had thrombosis of the lower pole vessel which required exploration and embolectomy, and this patient went on to have an uneventful recovery. Ureteric complications like ureteral necrosis and pelvicalyceal fistulas have been described in recipients with multiple renal arteries.<sup>[7]</sup> No such complications were seen here. In this analysis, no significant perioperative morbidity was seen in laparoscopic donors of single or multiple renal arteries. In one study, the warm ischemia time was higher in cases with multiple renal arteries,<sup>[8]</sup> while other studies have shown no difference.<sup>[9,10]</sup> The warm ischemia time, though slightly longer in our LDN multiple artery group, was not statistically significant. However, the estimated blood loss for recipients was significantly higher in cases with multiple renal arteries. This could be attributed to the additional blood loss from the vascular reconstruction between the multiple renal arteries. Several studies have reported the ability to use kidneys with multiple renal arteries harvested by the laparoscopic approach [Table 3].<sup>[11-14]</sup> The experience described here also confirms the findings of other studies showing a similar graft function and 1-year graft survival rates of kidneys with multiple renal arteries. Thus, it is suggested that the presence of multiple renal arteries should not exclude the possibility of using the left kidney for LDN. Although short and intermediate follow-ups show comparable results for graft functioning, a longer follow-up is warranted to assess potential late complications.

In this study, the warm ischemia time was not increased in donors with multiple renal arteries compared to donors with

**Table 3: Laparoscopic donor nephrectomy series for multiple renal arteries**

Author	Year	No. of cases	Graft survival at 1 year (%)
Fettouh <sup>[12]</sup>	2008	79	93
Hsu <sup>[11]</sup>	2003	76	91
Troppmann <sup>[13]</sup>	2001	21	93
Current study	2010	12	100
Oh <sup>[14]</sup>	2003	11	100

a single renal artery. Outcomes were also similar between recipients of multiple renal arteries compared to single artery transplants.

## REFERENCES

1. Ratner LE, Ciseck LJ, Moore RG, Cigarroa FG, Kaufman HS, Kavoussi LR. Laparoscopic live donor nephrectomy. *Transplantation* 1995;60:1047-9.
2. Fabrizio MD, Ratner LE, Montgomery RA, Kavoussi LR. Laparoscopic live donor nephrectomy. *Urol Clin North Am* 1999;26:247-56.
3. Husted TL, Hanaway MJ, Thomas MJ, Woodle ES, Buell JF. Laparoscopic right living donor nephrectomy. *Transplant Proc* 2005;37:631-2.
4. Flechner SM, Sandler CM, Houston GK, Van Buren CT, Lorber MI, Kahan BD. 100 living-related kidney donor evaluations using digital subtraction angiography. *Transplantation* 1985;40:675-8.
5. Reis RH, Esenther G. Variations in the pattern of renal vessels and their relations to the pattern of posterior vena cava in man. *Am J Anat* 1959;104:295-318.
6. Giessing M, Deger S, Turk I, Schönberger B, Budde K, Loening SA. Laparoscopic donor nephrectomy in Germany. *Transplant Proc* 2002;34:3099-102.
7. Roza AM, Perloff LJ, Najj A, Grossman RA, Barker CF. Living-related donors with bilateral multiple renal arteries: a twenty-year experience. *Transplantation* 1988;47:397-9.
8. Loughlin KR, Tilney NL, Richie JP. Urologic complications in 718 renal transplant patients. *Surgery* 1984;95:297-302.
9. Carter JT, Freise CE, McTaggart RA, Mahanty HD, Kang SM, Chan SH, et al. Laparoscopic procurement of kidneys with multiple renal arteries is associated with increased ureteral complications in the recipient. *Am J Transplant* 2005;5:1312-8.
10. Gürkan A, Kaçar S, Başak K, Varilsüha C, Karaca C. Do multiple renal arteries restrict laparoscopic donor nephrectomy? *Transplant Proc* 2004;36:105-7.
11. Hsu TH, Su LM, Ratner LE, Trock BJ, Kavoussi LR. Impact of renal artery multiplicity on outcomes of renal donors and recipients in laparoscopic donor nephrectomy. *Urology* 2003;61:323-7.
12. Fettouh HA. Laparoscopic donor nephrectomy in the presence of vascular anomalies: evaluation of outcome. *J Endourol* 2008;22:77-81.
13. Troppmann C, Wiesmann K, McVicar JP, Wolfe, BM, Perez, RV. Increased transplantation of kidneys with multiple renal arteries in the laparoscopic live donor nephrectomy era: surgical technique and surgical and nonsurgical donor and recipient outcomes. *Arch Surg* 2004;136:897-907.
14. Oh HK, Hawasli A, Cousins G. Management of renal allografts with multiple renal arteries resulting from laparoscopic living donor nephrectomy. *Clin Transplant* 2003;17:353-6.

**How to cite this article:** Kapoor A, Lambe S, Kling AL, Piercey KR, Whelan PJ. Outcomes of laparoscopic donor nephrectomy in the presence of multiple renal arteries. *Urol Ann* 2011;3:62-5.

**Source of Support:** Nil, **Conflict of Interest:** None.