

Received: 2019.07.18

Accepted: 2019.10.31

Available online: 2020.01.24

Published: 2020.02.18

Thrombolysis in Postoperative Pulmonary Embolism Following Liver Transplantation: A Case Report

Authors' Contribution:

Study Design A
Data Collection B
Statistical Analysis C
Data Interpretation D
Manuscript Preparation E
Literature Search F
Funds Collection G

ABCDDEFG 1 **Thamer H. Al-Ghamdi**
AB 2 **Anwar Jarrad**
AB 3 **Abdalla Younes Bashir**
AB 4 **Thomas Lorf**
ABCG 3 **Aiman Obed**

1 Department of Surgery, Faculty of Medicine, Al Baha University, Al Baha, Saudi Arabia
2 Hepatology, Gastroenterology and Hepatobiliary/Transplant Unit, Jordan Hospital, Amman, Jordan
3 Department of General and Transplant Surgery, Jordan Hospital, Amman, Jordan
4 Department of General, Visceral and Pediatric Surgery, University Medical Center Göttingen, Göttingen, Germany

Corresponding Author: Thamer H. Al-Ghamdi, e-mail: tthaker@bu.edu.sa

Conflict of interest: None declared

Patient: Male, 55-year-old
Final Diagnosis: Severe pulmonary embolism after liver transplantation
Symptoms: Sudden shortness of breath in the second post operative day
Medication: Anticoagulant
Clinical Procedure: Liver transplantation
Specialty: Transplantology

Objective: Unusual or unexpected effect of treatment

Background: Postoperative pulmonary embolism following liver transplantations is still one of the most fatal complications, especially during the early postoperative phase. The use of a thrombolytic agent such as the recombinant tissue-type plasminogen activator (rtPA) is considered a contraindication early after major abdominal surgery such as liver transplantation. However, thrombolysis after major surgery in the early postoperative period carries a substantial risk of surgical site hemorrhage.

Case Report: A 55-year-old patient presented with a hepatic mass diagnosed as a combined cholangio/hepatocellular carcinoma. Following the criteria of the University of San Francisco, California (UCSF) for liver transplantation, the case was selected for liver transplantation. The patient received neoadjuvant therapy. After the liver transplantation, on the second postoperative day, an acute, severe dyspnea with sudden onset occurred on the surgical ward. A computed tomography angiography showed a drawn-out embolus, which sprawled into both pulmonary main arteries and occluded them subtotally. A thrombolysis with rtPA was started. Within the first 60 minutes of administration of rtPA, the circulation stabilized effectively, so that epinephrine could be tapered down to zero and the patient was promptly extubated.

About 6 hours after administration of rtPA, a sudden and pronounced bleeding via one of the intraperitoneal drains occurred, hemoglobin concentration dropped from 9.7 g/dL to 6.4 g/dL. After immediate re-laparotomy, circulation and hemoglobin concentration were absolutely stable.

Conclusions: Even with anticipated high risk of bleeding, thrombolysis with rtPA can be used as a life-savings treatment in a case of pulmonary embolism after liver transplantation.

MeSH Keywords: Liver Transplantation • Pulmonary Embolism • Tissue Plasminogen Activator

Full-text PDF: <https://www.amjcaserep.com/abstract/index/idArt/918857>



1495



1



1



22



Background

The rate of ischemic stroke increases throughout postoperative time; with an estimated rate of about 2.9% for every patient who experiences general surgery [1]. Many patients who experience noncarotid, noncardiac surgery have an expanded risk for stroke [1]. Stroke in the postoperative period may be attributed to some underlying comorbid conditions instead of analgesic or surgical complications. In addition, tissue injury and immobilization may lead to an elaboration of thrombogenic factors which contribute to a procoagulant state that has the highest risk for stroke [2]. Haphazard use of the anticoagulants for prevention of stroke before surgery may give rise to an increase the incidence of stroke in the perioperative days.

During the postoperative period, the treatment of stroke can be difficult as treatment with thrombolysis agents, especially those of intravenous route, is contraindicated for 2 weeks following surgery [3]. Intra-arterial thrombolysis agents administered via the intra-arterial route may be a viable option for postoperative stroke patients, but there is limited data on this [4,5].

One of the thrombolytic agents administered via the intravenous (IV) route is the recombinant tissue-type plasminogen activator (rtPA), which if given within the 4-hour window would improve the outcome of patients with acute ischemic stroke [6,7]. Many contraindications for the use rtPA that have been reported, such as diabetes mellitus, previous stroke, stroke occurred in the last 3 months, age over 80 years, and if the stroke score (as determined by National Institute of Health Stroke Scale) is 25 [8,9]. However, the clinical relevance of some contraindications is still controversial due to the lack of available information. One of these contraindications is the use of thrombolytic agents in the management of postoperative stroke patients [10,11]. It is thought that IV administration in the postoperative period carries a significant risk of surgical site hemorrhage. The incidence of deep vein thrombosis (DVT) throughout the hospital stay is higher than in the general population. This higher rate is because of several risk factors that occur in hospitalized patients. The most important risk factors are tumors, cardiovascular disorder, and surgery itself. Because surgery is a general risk factor, postoperative patients are at an increased risk of developing DVT.

Our patient was suffering from a tumor and received preoperative chemotherapy and later a liver graft, so he had a clear risk for development of thromboembolism. He received immediately postoperative heparin for thromboembolism prophylaxis.

Case Report

The ethical approval for this study was granted by the ethical committee and a written consent was obtained from the patient for publication of this case study. The 55-year-old patient had a single right lobe lesion of 6 cm in diameter and was referred to the Hepato-biliary Surgery Department and diagnosed as cholangiocellular carcinoma (CCC)/hepatocellular carcinoma (HCC). Based on the criteria of the University of San Francisco, California (UCSF), the case was selected for liver transplantation. According to our Tumor Board recommendation, the patient received Gemzar and rapamycin. Early anti-thrombotic prophylaxis after the liver transplantation was carried out with heparin perfusion, with aPTT of 45–55 seconds.

On the second postoperative day, an acute, severe dyspnea with sudden onset occurred when the patient was on the surgical ward. The medical emergency team assessed the patient, applied oxygen in a dose of 12 L/minute via face mask and transferred the patient back to the intensive care unit (ICU).

On ICU admission, adverse clinical signs were profound cyanosis, dyspnea, and tachypnea with a respiratory rate of 36 breaths per minute. Auscultation revealed vesicular breath, slightly attenuated over the right lung. The pulse was weak, tachycardia and regular.

The patient was connected to non-invasive monitoring using electrocardiogram (ECG and SpO₂), and the patient was supplied with an arterial catheter to assess circulation and blood gases. ECG showed a sinus tachycardia with a heart rate of 134 beats per minute, the arterial blood pressure was 79/47 mmHg and central venous pressure was 11 mmHg. As both hypotension and tachycardia persisted after rapid infusion of 1000 mL crystalloid infusion, the arterial blood pressure was stabilized with epinephrine (up to 15 µg/min) and norepinephrine (up to 5 µg/min).

Chest x-ray showed a pronounced pleural effusion on the right side which was verified by sonography. A pleural catheter was placed immediately and drained 1200 mL in about 30 minutes, but oxygenation did not improve substantially, and tachypnea persisted. Arterial blood gas analysis showed a severely disturbed oxygenation (paO₂ 58 mmHg at 12 L/minutes oxygen via face mask), but normocapnia (paCO₂ 36 mmHg). Non-invasive ventilation was attempted but failed due to progredient confusion of the patient. Because the patient was close to respiratory decompensation, he was intubated and ventilated mechanically (BIPAP, P_{insp} 22 cmH₂O, PEEP 10 cmH₂O, FiO₂ 1.0), but paO₂ only increased to 93 mmHg. Sedation was carried out with 3 mg/kg/h propofol. Parameters of blood gases are summarized in (Table 1).

Table 1. Changing of blood gas analyses after Intensive Care Unit (ICU) admission, intubation and start of rt-PA-lysis.

	ICU admission	After intubation	60 minutes after rt-PA
Respiratory pattern	Spontaneous breathing 12 L/min oxygen via face mask	BIPAP, FiO ₂ =1.0 P _{insp} =22 cmH ₂ O PEEP=10 cmH ₂ O	BIPAP, FiO ₂ =0.45 P _{insp} =20 cmH ₂ O PEEP=7 cmH ₂ O
paO ₂ (mmHg)	58	93	239
paCO ₂ (mmHg)	36	34	44
pH	7.43	7.47	7.33
Oxygen saturation (%)	94	100	100
PaO ₂ /FiO ₂ (mmHg)	n.a.	93	531
HCO ₃ ⁻ (mmol/L)	23.9	24.7	23.2
Base excess (mmol/L)	-0.4	1.0	-2.7
Lactate (mmol/L)	1.6	2.0	5.8

At this point, a transthoracic echocardiography was performed and showed remarkable dilated right ventricle and atrium. In combination with elevated d-dimers (8.04 mg/L), pulmonary lung embolism was suspected to be the cause of severe circulatory and respiratory failure. A computed tomography angiography was performed immediately and showed a drawn-out embolus, which sprawled into both pulmonary main arteries and occluded them subtotally (Figure 1). Because high doses of catecholamines were still necessary to stabilize circulation, and oxygenation was also compromised severely, a thrombolysis with rtPA was started: 10 mg were given as bolus followed by continuous application of 90 mg over 90 minutes. To avoid the formation of further emboli, 600 IU/hour heparin were administered intravenously. Femoral and iliac veins were investigated using Doppler sonography, but no thrombosis could be found.

Within the first 60 minutes of administration of rtPA, the circulation stabilized effectively, so that inotrope therapy with epinephrine could be tapered down to zero. Oxygenation also improved rapidly. Table 1 shows the course of blood gas analyses. Though the excellent gas exchange allowed for extubation, it was planned to continue mechanical ventilation until the next morning to recreate the respiratory system.

About 6 hours after administration of rtPA, a sudden and pronounced bleeding via one of the intraperitoneal drains occurred, and hemoglobin concentration dropped from 9.7 g/dL to 6.4 g/dL. Two units of packed cells were transfused, and re-laparotomy was done immediately. A small lymphatic artery was identified as the bleeding source and ligated sufficiently; careful inspection of the entire operation site revealed no other bleeding source. Postoperatively the drains remained free of blood; circulation and hemoglobin concentration were absolutely stable.

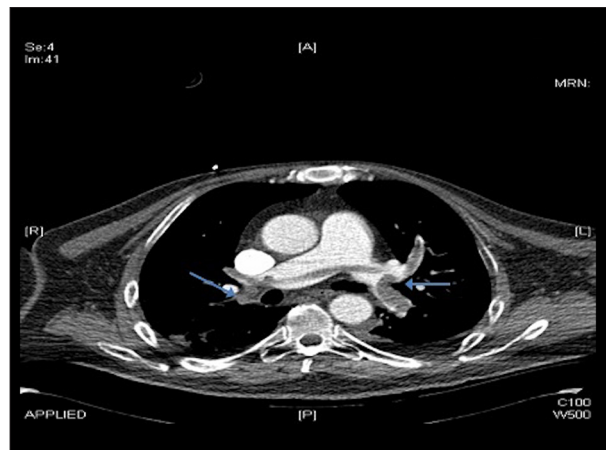


Figure 1. Computed tomography angiography showed both pulmonary arteries are occluded subtotally by a single, drawn-out embolus. Blue arrows indicate the bilateral pulmonary embolism.

Sedation with propofol was stopped the next morning and the patient was extubated without any problems. Gas exchange and circulation remained absolutely stable; no signs of bleeding occurred. Also, liver function was not affected in any way. For safety reasons, the patient was observed for 3 further days in the ICU and then transferred back to the surgical ward.

Discussion

Many criteria are used for considering a liver transplantation [12]; an expanded criteria of the UCSF was proposed by Yao et al. [13] in 2001. The UCSF criteria provides the basis for selection of cases for liver transplantation and the criteria include the presence of a single lesion of diameter ≤6.5 cm or

2 to 3 lesions each ≤ 4.5 cm with a total maximum diameter ≤ 8 cm. So, the presenting case was selected for liver transplantation according to the presence of multiple lesions of 7 cm in total diameter.

In this present case, the use of rtPA in the management of pulmonary embolism that could be expected following liver transplantation due to hypercoagulable state [14,15], was considered a novel process as no studies have referred to this approach previously. Despite occurrence of hemorrhage at 6 hours after administration of rtPA, the lysis of the embolus occurred, and the patient's condition improved. This encouraged us to appreciate that the selection of rtPA administration was a life-saving medication. The rtPA administration needs close monitoring to observe the adverse complications, listed in literature for rtPA as hemorrhage especially at the site of operation. In the postoperative period, poorly cross-linked fibrin at the surgical site could act as a binding site for thrombolytics, disrupting hemostasis and leading to bleeding [16].

Regarding several other center reports of the occurrence of hemorrhage on using the rtPA post-operatively, the Food and Drug Administration uses quotes for "recent major operation",

in addition European restrictions use quotes for "operation within the past 3 months" as a contraindication [17,18]. There are many studies assessing thrombotic risks in cirrhotic patients and in the post-transplantation period [19–21].

In general cancer patients have a 5-fold to 7-fold increased risk of developing venous thromboembolism. In addition, there is more and more evidence suggest that rapamycin promote thrombosis [22].

Conclusions

Despite the high risk of expected hemorrhage in these situations, rtPA administrations as a thrombolytic agent for pulmonary embolism that may occur after liver transplantation can be life-saving. Close monitoring must be done to observe the complications, especially bleeding at the site of surgery. Early and rapid management of such complications are essential.

Conflict of interest

None.

References:

1. The NINDS rt-PA Stroke Study Group: Tissue plasminogen activator for acute ischemic stroke. *N Engl J Med*, 1995; 333: 1581–87
2. Katzan IL, Furlan AJ, Lloyd LE et al: Use of tissue-type plasminogen activator for acute ischemic stroke: The Cleveland area experience. *JAMA*, 2000; 283: 1151–58
3. Riopelle RJ, Howse DC, Bolton C et al: Regional access to acute ischemic stroke intervention. *Stroke*, 2001; 32: 652–55
4. Smith M, Doliszny K, Shahar E et al: Delayed hospital arrival for acute stroke: The Minnesota Stroke Survey. *Ann Intern Med*, 1998; 129: 190–96
5. Barber PA, Zhang J, Demchuk AM et al: Why are stroke patients excluded from alteplase therapy? An analysis of patient eligibility. *Neurology*, 2001; 56: 1015–20
6. Emberson J, Lees KR, Lyden P et al., Stroke Thrombolysis Trialists' Collaborative Group: Effect of treatment delay, age, and stroke severity on the effects of intravenous thrombolysis with alteplase for acute ischaemic stroke: A meta-analysis of individual patient data from randomised trials. *Lancet*, 2014; 384: 1929–35
7. Frey JL: Recombinant tissue plasminogen activator (rtPA) for stroke. The perspective at 8 years. *Neurologist*, 2005; 11(2): 123–33
8. Okuda D, Flaster M, Frey J, Sivakumar K: Arterial thrombosis induced by IVIg and its treatment with tPA. *Neurology*, 2003; 60(11): 1825–26
9. Demaerschalk BM, Kleindorfer DO, Adeyoye OM et al., American Heart Association Stroke Council and Council on Epidemiology and Prevention: Scientific rationale for the inclusion and exclusion criteria for intravenous alteplase in acute ischemic stroke: A statement for healthcare professionals from the American Heart Association/American Stroke Association. *Stroke*, 2016; 47: 581–641
10. Meretoja A, Putaala J, Tatlisumak T et al: Off-label thrombolysis is not associated with poor outcome in patients with stroke. *Stroke*, 2010; 41: 1450–58
11. Guillan M, Alonso-Canovas A, Garcia-Caldentey J et al: Off-label intravenous thrombolysis in acute stroke. *Eur J Neurol*, 2012; 19: 390–94
12. Figueras J, Ibañez L, Ramos E et al: Selection criteria for liver transplantation in early-stage hepatocellular carcinoma with cirrhosis: Results of a multicenter study. *Liver Transpl*, 2001; 7: 877–83
13. Yao FY, Ferrell L, Bass NM et al: Liver transplantation for hepatocellular carcinoma: Expansion of the tumor size limits does not adversely impact survival. *Hepatology*, 2001; 33: 1394–403
14. Cherian TP, Chiu K, Gunson B et al: Pulmonary thromboembolism in liver transplantation: A retrospective review of the first 25 years. *Transpl Int*, 2010; 23(11): 1113–19
15. Giakoustidis A, Cherian TP, Antoniadis N, Giakoustidis D: Combined cardiac surgery and liver transplantation: Three decades of worldwide results. *J Gastrointest Liver Dis*, 2011; 20(4): 415–21
16. Molina JE, Hunter DW, Yedlicka JW, Cerra FB: Thrombolytic therapy for postoperative pulmonary embolism. *Am J Surg*, 1992; 163: 375–81
17. Moazami N, Smedira NG, McCarthy PM et al: Safety and efficacy of intra-arterial thrombolysis for perioperative stroke after cardiac operation. *Ann Thorac Surg*, 2001; 72: 1933–37; discussion 1937
18. Kasner SE, Villar-Cordova CE, Tong D, Grotta JC: Hemopericardium and cardiac tamponade after thrombolysis for acute ischemic stroke. *Neurology*, 1998; 50: 1857–59
19. Feltracco P, Barbieri S, Cillo U et al: Perioperative thrombotic complications in liver transplantation. *World J Gastroenterol*, 2015; 21: 8004–13
20. Qi X, Dai J, Jia J et al: Association between portal vein thrombosis and survival of liver transplant recipients: A systematic review and meta-analysis of observational studies. *J Gastrointest Liver Dis*, 2015; 24: 51–59, 4 p following 59
21. Mukerji AN, Karachristos A, Maloo M et al: Do post-liver transplant patients need thromboprophylactic anticoagulation? *Clin Appl Thromb Hemost*, 2014; 20: 673–77
22. Ma Q, Zhou Y, Nie X et al: Rapamycin affects tissue plasminogen activator and plasminogen activator inhibitor 1 expression: A potential prothrombotic mechanism of drug-eluting stents. *Angiology*, 2012; 15: 330–35