

Teaching Case

Successful Radiation Therapy for Breast Cancer in a Patient With Hereditary Coproporphyrria

Thomas Pennix, BA,^a Gregory Azzam, MD, PhD,^{a,b} and Stuart E. Samuels, MD, PhD^{a,b,*}

^aDepartment of Radiation Oncology, University of Miami Miller School of Medicine, Miami, Florida and ^bDepartment of Radiation Oncology, Sylvester Comprehensive Cancer Center, Miami, Florida

Received 10 March 2020; revised 7 July 2020; accepted 8 July 2020



Introduction

Porphyrias are a family of disorders resulting from multiple enzymatic defects along the heme synthesis pathway. Altogether, 9 types of porphyrias have an estimated overall prevalence of 1 in 50,000 within the U.S. population. Classifications of porphyrias are hepatic or erythropoietic depending on the site of the deficient enzyme, and acute or chronic, referring to the duration of symptoms. Hereditary coproporphyrria (HC) is an acute hepatic porphyria resulting from an autosomal dominant mutation in the coproporphyrinogen oxidase liver enzyme. HC presents with neurovisceral symptoms that manifest in rapid onset attacks.^{1,2} Neurologic symptoms likely arise owing to accumulation of precursors from an ineffective synthesis of protoporphyrinogen. Patients with porphyrias should also avoid numerous medications that can trigger attacks.³ As an acute porphyria, HC is associated with severe photosensitivity. These issues raise concerns over the use of radiation therapy (RT) when treating a patient with porphyria.⁴ Owing to the rarity of porphyrias, there is scarce literature addressing this topic. Here, we report on a patient with HC who received RT for her stage IA, estrogen receptor/progesterone receptor (ER/PR)-positive, HER-2-negative invasive ductal carcinoma (IDC) and report the results of a literature review to help contextualize the case.

Case Presentation

A 54-year-old African American female patient with a past medical history of diabetes mellitus presented with a 1-cm irregular spiculated mass below the nipple that was originally discovered by mammogram and confirmed by ultrasound. Biopsy and histologic staining the same month revealed an ER/PR-positive, HER-2-negative moderately differentiated IDC. A thorough examination and history were notable for HC, and she was asymptomatic from both her cancer and HC upon presentation. She had previously been symptomatic with photosensitivity and skin lesions before her HC diagnosis and experienced intermittent attacks of acute abdominal pain requiring hospitalizations at the ages of 9 and 20. She was finally diagnosed with HC in her early 30s after an attack that was exacerbated by medications when a 24-hour urine sample demonstrated an elevated coproporphyrin of 186 (n < 155) and an elevated total porphyrin of 205 (n = 12-190). Since then, she has controlled her HC symptoms well through a strict diet and minimizing sun exposure. Her last documented porphyritic event occurred approximately 1 year before her presentation with breast cancer, when she experienced hallucinations, back pain, and myalgias that were likely caused by the medication cyclopentolate that she received for acute anterior uveitis.

Owing to photosensitivity concerns, the patient was recommended total mastectomy. However, the patient elected for breast conservation via lumpectomy followed by RT. She underwent a partial mastectomy of the right breast and pathology revealed a multifocal moderately differentiated IDC,

Sources of support: This work had no specific funding.

Disclosures: none.

* Corresponding author: Stuart E. Samuels, MD, PhD; E-mail: ssamuels@med.miami.edu

<https://doi.org/10.1016/j.adro.2020.07.005>

2452-1094/© 2020 The Authors. Published by Elsevier Inc. on behalf of American Society for Radiation Oncology. This is an open access article under the CC BY-NC-ND license (<http://creativecommons.org/licenses/by-nc-nd/4.0/>).

Nottingham grade II with nuclear pleomorphism score 2, mitotic rate score 1 (≤ 3 mitoses per mm^2), and glandular (acinar)/tubular differentiation score 3. Two foci of tumor 1.7 cm and 1.5 cm in size were identified, and extensive ductal carcinoma in situ was also present. The surgical margins were free of tumor with the closest margins <0.1 cm from IDC and 0.2 cm from ductal carcinoma in situ. Three sentinel nodes were collected and found to be negative for tumor. Histology showed ER positivity with $>50\%$ nuclear staining and PR positivity with 1% to 10% nuclear staining. HER-2 staining was negative.

The patient recovered well after surgery without any complications. Ongoing pain management without narcotic medications was achieved immediately after surgery. Follow up 2 weeks later showed a well-healing surgical incision without erythema or drainage, and she was scheduled for RT to begin 2 months after her surgery.

RT Planning and Delivery

RT was planned using the Eclipse treatment planning software. Treatment was delivered on a Varian 21Ex Linear Accelerator. Treatment was delivered with

3-dimensional conformal RT using field-in-field technique with deep inspiration breath hold. She was simulated in a supine position with her legs extended and arms extended above her head with use of a wing board to aid in reproducible positioning. The patient has pendulous breasts and thus was treated in a Chabner RT support bra. The prescription dose was 46 Gy in 23 fractions to the entire right breast with a sequential boost of 14 Gy in 7 fractions to the lumpectomy cavity for a total of 30 fractions. Hypofractionation was not used in this patient owing to the concern of higher dose per fraction treatments exacerbating a porphyritic attack. Her Oncotype Dx Score was 10, thus she was not offered chemotherapy. Despite ER/PR positivity, she declined adjuvant hormone therapy owing to her history of porphyria and potential side effects, as it is known that porphyritic attacks can be triggered by hormonal fluctuations. A mean dose of 40.8 cGy was delivered to the heart, 18.6 cGy to the left lung, 264.2 cGy to the right lung, and 20.4 cGy to the spinal cord. The tumor bed target volume received a maximum dose of 64.91 Gy, and the right breast received a mean dose of 53.45 Gy. The isodose lines and dose volume histogram are shown in Figure 1.

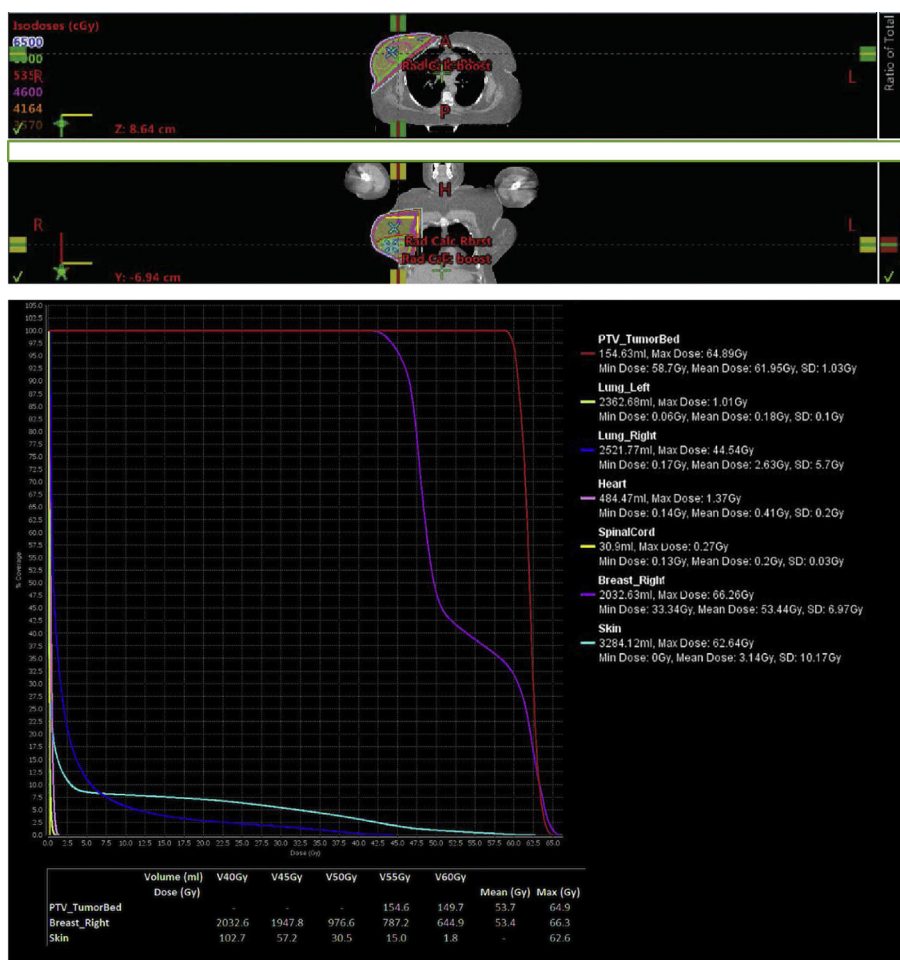


Figure 1 Eclipse treatment planning with isodose lines and dose volume histogram.

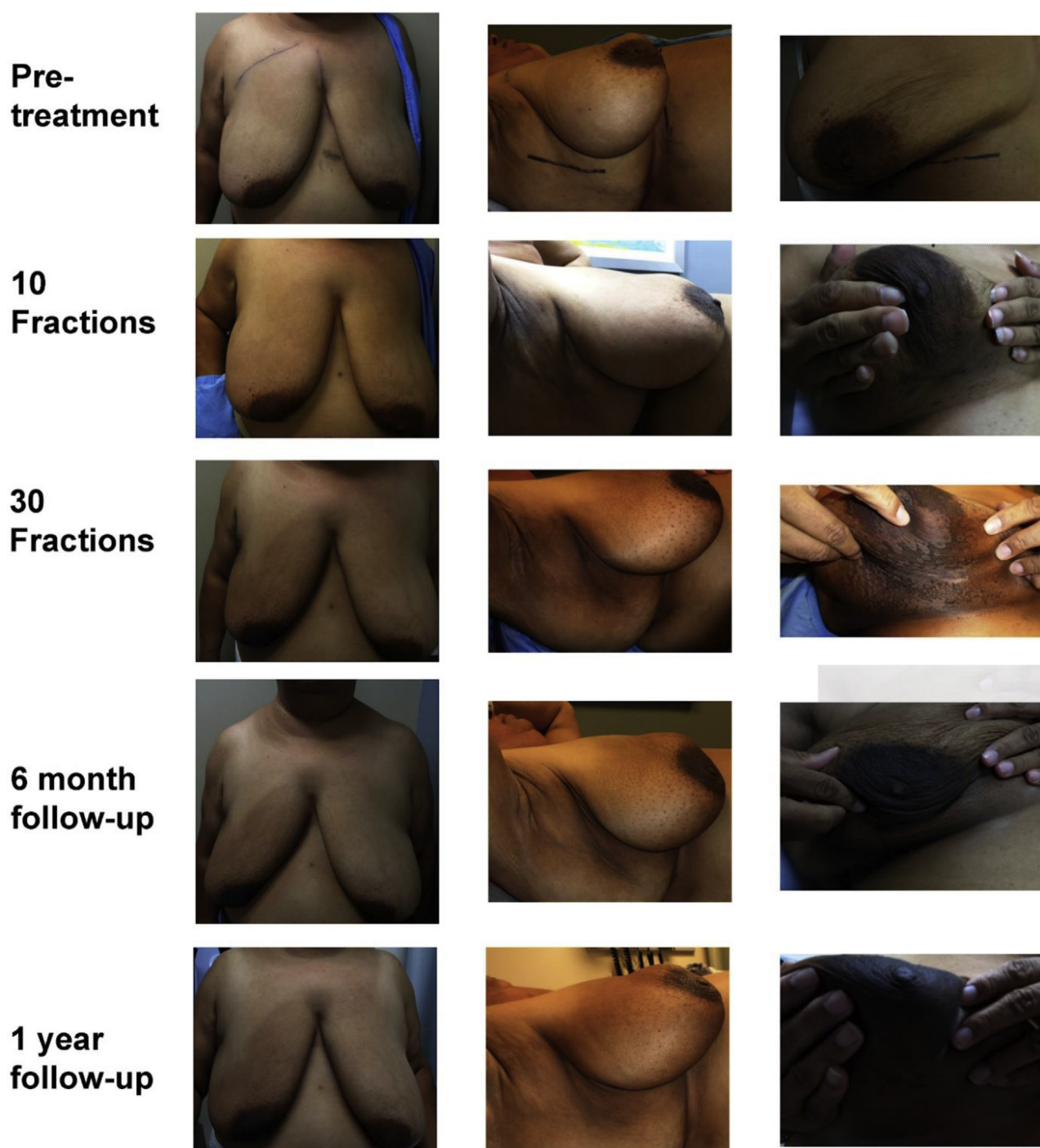


Figure 2 Photographic record of the breasts before, during, and after radiation therapy. No significant breast/skin toxicity was seen during or after radiation therapy.

She developed moderate skin erythema and a small amount of moist desquamation that developed around the axillary incision site (Common Terminology Criteria for Adverse Events [CTCAE] v4.0, grade 2). She described pain in the axilla that she rated as moderate to severe (CTCAE v4.0, grade 2-3), which was greater than anticipated and out of proportion to physical examination findings. She also experienced fatigue that limited her

usual activities of daily living, and she was only able to work part time (CTCAE v4.0, grade 2). Follow-up 14 months after RT showed normal skin toxicities without unexpected complications and no abnormal skin lumps (CTCAE v4.0, grade 1 hyperpigmentation and lymphedema, see Fig 2). She noted that her fatigue no longer affected her ability to work (CTCAE v4.0, grade 1) and continued to have hypersensitivity of the right axilla,

Table 1 Summary of case studies of patients with porphyric syndromes treated with radiation therapy

Reference (author, year)	Patient demographics	Site	Dose	Side effects
Schaffer et al, ⁵ 2001	70 male, PCT	Pelvis	51 Gy	Acute: Normal erythema
Maughan et al, ⁶ 1979	PCT	Whole brain	32.5 Gy	N/A
Maughan et al, ⁶ 1979	PCT	Abdomen, inguinal, paratracheal, scalene regions	Multiple sites, dose unreported	N/A
Rhomberg and Offner, ⁷ 2005	PCT	Brain	60 Gy	Brain necrosis and worsening porphyria
Rhomberg and Offner, ⁷ 2005	PCT	Brain	38 Gy	Tumor necrosis and worsening porphyria
Gunn et al, ¹⁰ 2010	50 y/o man, PCT	Lower lip and bilateral upper neck	70 Gy to lower lip 50 Gy to bilateral upper neck (level I/II)	Acute: Mucositis, moist desquamation Late: Severe fibrotic changes and hypopigmentation, skin sclerosis, and fibrosis
Russo and Braseth, ¹¹ 2017	56 y/o white man, PCT	Right neck	35 IMRT fractions at 4 dose bins: 55 Gy-L nondissected neck 60 Gy-uninvolved dissected R neck 66 Gy-extracapsular extension areas of R neck 70 Gy-R tonsillar tumor beds	Acute: Dysphagia and taste changes, oral candidiasis
Schaffer et al, ⁵ 2001	48 female, AIP	Chest wall, brain, and mediastinum	60 Gy chest wall 50 Gy mediastinum 48 Gy brain	Acute: Normal erythema
Kristiansen and Langkjer, ⁹ 2006	42 y/o woman, AIP	Spine L4-S1	8 Gy	N/A
Scarlett et al, ⁸ 1995	43 y/o white woman, VP	Upper L breast	60 Gy to left chest 50 Gy to left supraclavicular fossa 20 Gy boost	Acute: Marked skin erythema, moist desquamation
Current article	55 y/o woman, HC	Right breast	60 Gy	Acute: Mild/moderate radiation dermatitis, moderate fatigue, moderate to severe axillary pain Late: Mild fatigue, mild skin hyperpigmentation, mild lymphedema, mild axillary pain

Abbreviations: AIP = acute intermittent porphyria; HC = hereditary coproporphyrria; IMRT = intensity modulated radiation therapy; PCT = porphyria cutanea tarda; VP = variegate porphyria.

breast, and inframammary fold within the normal range post-RT. Eighteen months after completing RT, her mammography was normal.

Discussion and Literature Review

We report a case of the safe use of adjuvant RT for a patient with breast cancer and HC, notable only for a potentially exaggerated acute pain response in the skin over her treated breast and axilla. Follow-up 1 year after

completing RT suggests dramatic improvement of the noted hypersensitivity and pain in her breast and axilla to normal after surgery and adjuvant RT. Overall, this case supports the majority of scarce available literature displaying the safe use of RT for patients with porphyria and cancer, and is the only such example specific to HC to our knowledge. Most of the available literature reports on patients with porphyria cutanea tarda (PCT), which does not present with neurologic attacks, but shares the photosensitive features. A list of the case reports can be found in [Table 1](#) and is summarized below.

Schaffer et al⁵ reported 2 cases of patients with porphyria receiving RT; a 48-year-old woman with acute intermittent porphyria and a 70-year-old man with PCT. The first patient with acute intermittent porphyria presented with left breast cancer, for which she received a radiation dose of 60 Gy to the left chest wall, and again received doses of 46 and 50 Gy to her head and mediastinum, respectively, for metastases a year later. The second patient with PCT presented with bladder cancer, for which he received a radiation dose of 51 Gy to the pelvis. Neither patient displayed abnormal acute or chronic reactions, or suffered acute porphyric attacks during treatment, leading to the conclusion that RT was a safe and reasonable choice for patients with porphyria.

Maughan et al⁶ reported 2 cases of patients with PCT receiving RT, 1 male and 1 female. The male patient received 32 radiation treatments to the abdomen, inguinal, paratracheal, and scalene areas for IIIB Hodgkin lymphoma, and the female patient received 32.5 Gy to the brain for metastases from renal lymphoma. There are no significant reported side effects, indicating no increased toxicity with the use of RT in patients with porphyria.

Rhomberg and Offner⁷ report 2 cases with both patients having PCT and glioblastomas for which they received 60 and 38 Gy to the brain, respectively. The patient receiving 60 Gy died 7 months after treatment and was noted to have extensive brain necrosis as well as worsening porphyria symptoms on autopsy. The patient that received 38 Gy died 1.5 months after treatment and was also found to have extensive tumor necrosis and worsening porphyria. These results lead to the conclusion that RT may be an aggravating factor in porphyria, and should be used with care in such patients.

Scarlett et al⁸ report on a 43-year-old woman with variegate porphyria who received 60 Gy to the left chest, 50 Gy to the left supraclavicular fossa, and 20 Gy boost 1 month later for a left-sided breast cancer. Acute, mild paresthesias were the only reported side effects, with no other immediate or long-term symptoms. The case provides further evidence that RT can be used in patients with porphyria without a clinically significant effect.

Kristiansen and Langkjer⁹ report on a 42-year-old woman with acute intermittent porphyria who received RT to the spine (L4-S1) for metastases from a ductal carcinoma of her right breast. The patient died 2 years after treatment as a result of progressive cancer, but showed no acute porphyric reactions or abnormal symptoms from the RT she received, with the conclusion that there was no interaction between the patient's porphyria and use of RT.

Gunn et al¹⁰ reported on the case of a 50-year-old man with PCT who received 70 Gy to the lower lip and 50 Gy to the bilateral upper neck area for the treatment of a lower lip squamous cell carcinoma. Six months after treatment, the patient developed severe soft tissue pain in his lower face and upper neck with progressive soft tissue

fibrosis and hypopigmentation in the areas of treatment. The restriction of adverse reactions to only the areas of RT administration led the authors to conclude that RT can exacerbate porphyric symptoms, and should be used cautiously or not at all for superficial cancers in patients with porphyria.

Russo and Braseth¹¹ report on a 56-year-old man with PCT and oropharyngeal cancer who received 56, 60, 66, and 70 Gy to the head and neck. Acute erythema and dermatitis within normal ranges were noted, with no abnormal acute or chronic symptoms related to the patient's porphyria. The report ends with the cautious support of RT in patients with porphyria.

In our patient, well-tolerated adjuvant RT was delivered to the right breast of a patient with HC without the patient developing any acute abnormal reactions to treatment aside from perhaps increased pain over what may be considered routine. At 1 year post-RT, the patient reported hypersensitivity of the skin over the axilla and skin of the right breast, although this is a common long-term side effect for patients who undergo breast-conserving surgery followed by radiation. At 1 year post-RT, she has ongoing mild fatigue that improved after radiation but never returned to baseline. She has not experienced an acute exacerbation of HC since RT (as of 18 months after completion). In her past crisis, she experienced severe abdominal pains and elevated blood counts but not fatigue. Therefore, fatigue may be a late adverse outcome after RT, but it is uncertain whether her fatigue was influenced by HC. Certainly, 1 limitation of this case report is the relatively short-term follow-up window at the time of our reporting, as it is possible she may develop late adverse skin reactions (hyperpigmentation, lymphedema, fibrosis, contracture) beyond what is considered routine.

Conclusions

The lack of any significantly acute side effects from our presented case supports the cautious use of RT in patients with porphyria. Longer-term follow-up is still needed to ensure the patient does not present with significant late outcomes, and the patient will be closely followed to monitor any new side effects. These present findings, combined with a review of the available literature, provide evidence for the effective use of RT in patients with porphyria, but with particular caution due to the limited data.

References

1. Fernandes J, Van den Berghe G, Saudubray JM, Walter JH. *Inborn Metabolic Diseases Diagnosis and Treatment*. Berlin: Springer Medizin Verlag Heidelberg; 2006. Available from: <https://doi.org/10.1007/978-3-540-28785-8>.
2. Simon NG, Herkes GK. The neurologic manifestations of the acute porphyrias. *J Clin Neurosci*. 2001;18:1147-1153.

3. Dietzen DJ, Bennett MJ, Wong EC. American Association for Clinical Chemistry. *Biochemical and Molecular Basis of Pediatric Disease*. 4th Ed. Washington, DC: AACCC Press; 2010.
4. Foran SE, Ábel G. Guide to porphyrias: A historical and clinical perspective. *Path Patterns Rev*. 2003;119:S86-S93.
5. Schaffer M, Schaffer PM, Panzer M, Wilkowski R, Duhmke E. Porphyrins associated with malignant tumors: Results of treatment with ionizing irradiation. *Onkologie*. 2001;24:170-172.
6. Maughan WZ, Muller SA, Perry HO. Porphyrin cutanea tarda associated with lymphoma. *Acta Derm Venereol*. 1979;59:55-58.
7. Rhomberg W, Offner FA. Porphyrin and radiotherapy: Yet a constellation of risk? *Strahlenther Onkol*. 2005;181:401-404.
8. Scarlett JD, Corry J, Jeal PN. Cytotoxic chemotherapy and radiotherapy in a patient with breast cancer and variegate porphyria (VP). *Aust NZ J Med*. 1995;25:742-743.
9. Kristiansen C, Langkjær ST. Treatment and treatment considerations in a patient with advanced breast cancer and acute intermittent porphyria. *Acta Oncol*. 2006;45:337-339.
10. Gunn GB, Anderson KE, Patel AJ, et al. Severe radiation therapy-related soft tissue toxicity in a patient with porphyria cutanea tarda: A literature review. *Head Neck*. 2010;32:1112-1117.
11. Russo JK, Braseth A. Radiation and chemotherapy with no excessive toxicity in a patient with human papillomavirus-related tonsillar cancer and porphyria cutanea tarda: Case report and literature review. *Head Neck-J Sci Spec*. 2017;39:E102-E109.