

## Case Report

# Successful Outcome of Triangle Tilt as Revision Surgery in a Pediatric Obstetric Brachial Plexus Patient with Multiple Previous Operations

**Rahul K. Nath, Vishnu Halthore, and Chandra Somasundaram**

*Texas Nerve and Paralysis Institute, 6400 Fannin Street, Houston, TX 77030, USA*

Correspondence should be addressed to Rahul K. Nath; [drnath@drnathmedical.com](mailto:drnath@drnathmedical.com)

Received 27 August 2014; Revised 3 November 2014; Accepted 4 November 2014; Published 23 November 2014

Academic Editor: Cheng-Yu Long

Copyright © 2014 Rahul K. Nath et al. This is an open access article distributed under the Creative Commons Attribution License, which permits unrestricted use, distribution, and reproduction in any medium, provided the original work is properly cited.

*Introduction.* Obstetric brachial plexus injury (OBPI) occurs during the process of labor and childbirth. OBPI has been reported to be associated with shoulder dystocia, macrosomia, and breech delivery. Its occurrence in uncomplicated delivery is possible as well. *Case Presentation.* The patient in the present report is a 6.5-year-old girl, who suffered a severe brachial plexus injury at birth and had many reconstructive surgical procedures at an outside brachial plexus center before presenting to us. *Discussion.* The traditional surgical treatments by other surgical groups were unsuccessful and therefore the patient came to our clinic for further treatment. She had triangle tilt surgery with us, as a salvage procedure. *Conclusion.* The OBPI patient in this study clearly showed noticeable clinical and functional improvements after triangle tilt surgical management. The posture of the arm at rest was greatly improved to a more normal position, and hand to mouth movement was improved as well. Triangle tilt surgery should be conducted as a first choice treatment for medial rotation contracture of the shoulder in OBPI patients.

## 1. Introduction

Obstetric brachial plexus injury (OBPI) occurs during the process of labor and childbirth. OBPI has been reported to be associated with shoulder dystocia, [1–3] macrosomia [3, 4], and breech delivery [5]. Its occurrence in uncomplicated delivery is not uncommon [6–8]. Most injured infants recover upper extremity function spontaneously [9, 10]. However, roughly one in 5 affected infants tends to retain persistent limb deficits, never recover full function, and develop permanent injuries [11]. The most commonly affected nerve roots of the brachial plexus are C5–6, with or without injury to the other roots, affecting any or all of the C5–T1 nerve roots. C8–T1 roots are rarely affected [12]. Persistent C5 nerve damage in these patients leads to muscle imbalances and bony deformities at the shoulder joint. Significant shoulder secondary deformities that follow include medial rotation contracture and elbow flexion contracture [12].

Many traditional procedures have been described to treat obstetric brachial plexus deformity [13–16]. Here, we report

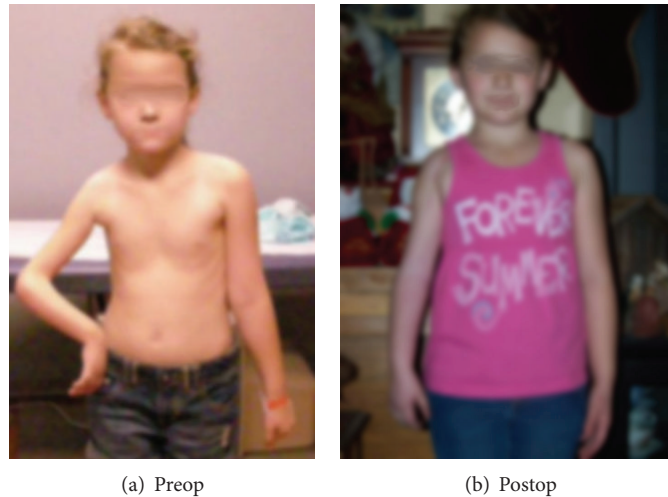
the clinical outcome of one OBPI pediatric patient, who had undergone the triangle tilt surgical procedure as a salvage procedure at our institution [17–24].

## 2. The Triangle Tilt Surgical Procedure

The triangle tilt is an established novel osseous surgical procedure, consisting of osteotomy of the clavicle at the junction of the middle and outer thirds, osteotomy of the acromion at its junction with the spine of the scapula, osteotomy of the superomedial angle of the scapula, anterior shoulder capsule, and soft tissue releases and splinting of the limb in adduction, 5° of external rotation, and full forearm supination [17–24]. These individual procedures together release the distal acromioclavicular triangle and allow it to reorient itself in a more neutral position into the glenoid fossa. Further, this operative technique addresses the SHEAR [25] deformity and its central influence in the pathophysiology of the medial rotation contracture (MRC) and the shoulder deformity.

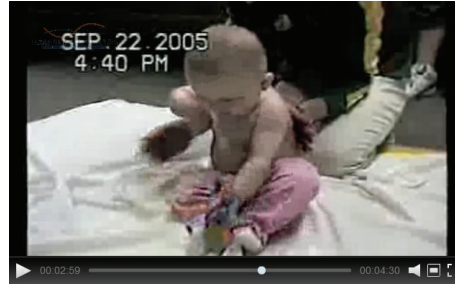

FIGURE 1: The patient (8 months old) with severe obstetric brachial plexus injury with bent elbow, shorter arm with internal rotation of the shoulder.



(a) Preop

(b) Postop

FIGURE 2: Clinical photograph of the patient after multiple surgeries at an outside hospital but before triangle tilt surgery (a) and 2 months after triangle tilt surgery (b), showing significant improvement in resting arm posture.

### 3. Case Presentation

The patient in the present report is a 6.5-year-old girl who was born with right side brachial plexus injury (C5–C8), weighing 9 lb 13 oz. She did not have a documented history of shoulder dystocia and was delivered normally without the use of any instruments. There was no finger movement at birth. The patient initially presented to us when she was 8 months old with severe obstetric brachial plexus injury (Figure 1). She had a flexed elbow, a shorter arm with medial rotation of the shoulder. We recommended triangle tilt surgery for the medial rotation of the shoulder with contracture and flexed elbow. Nerve transfer or nerve graft surgeries were not recommended [26]. Instead, the child was referred to another surgeon by her insurance company for treatment, where she underwent the following operations over 5+ years' time:

- (1) brachial plexus decompression,
- (2) shoulder joint reduction,
- (3) decompression of subacromial space,
- (4) subscapularis lengthening,
- (5) glenohumeral joint ligament releases,
- (6) latissimus dorsi tendon transfer,

- (7) teres major tendon transfer,
- (8) end-to-side axillary nerve to triceps nerve transfer,
- (9) end-to-side axillary nerve to radial nerve transfer,
- (10) derotational humeral osteotomy,
- (11) biceps to triceps tendon transfer using cadaver donor graft,
- (12) elbow lengthening with cadaver donor graft.

This patient had persistent internal rotation deformity (among many other ongoing problems) related, by preoperative clinical examination and radiological studies, to an elevated scapula with forward rotation (Figure 4), the SHEAR deformity [25]. This placed the humerus into an internally rotated position in the glenohumeral joint and, therefore, resulted in the abnormal posture prior to surgery. The patient's findings specifically indicated treatment with triangle tilt surgery [17–24] at our clinic. The senior author (RKN) performed the surgical procedures. The post-triangle tilt pictures of the patient are presented in Figures 2(b), 3(b), and 3(c).

Procedures performed on this patient are as follows:

- (1) scapular osteotomy,

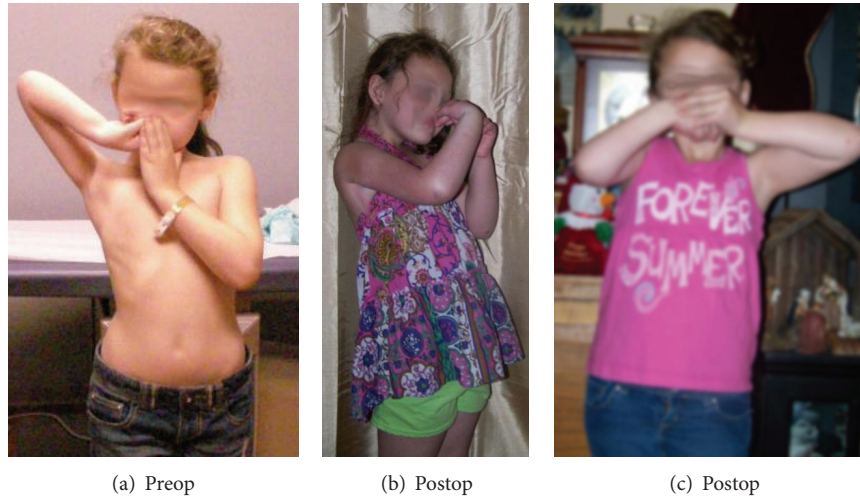

FIGURE 3: Functional movement picture of the patient after multiple surgeries at an outside hospital but before triangle tilt surgery (a) and 2 months after triangle tilt surgery (b), showing improvement in hand to mouth movement.

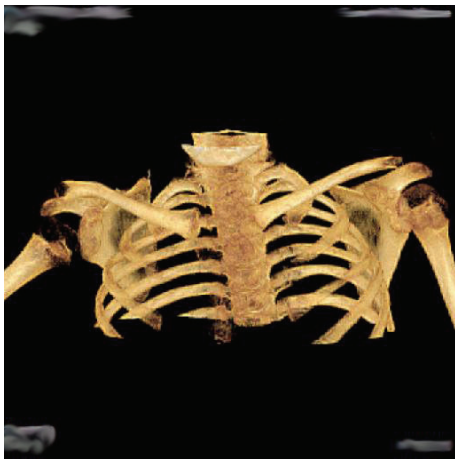

FIGURE 4: Radiological picture of the patient after multiple surgeries at an outside hospital but before triangle tilt surgery, showing SHEAR deformity [25].

- (2) spinous process/acromion process osteotomy,
- (3) bone graft; acromion process,
- (4) anterior glenohumeral capsule release and subscapularis tendon release,
- (5) pectoralis major and minor release,
- (6) subscapularis tendon transfer,
- (7) clavicle osteotomy.

#### 4. Discussion

The outcome of all the above surgeries at the outside institution was poor. There was no change in the clinical picture and the patient had significant functional issues, with no improvement in physical deformities (Figures 2(a) and 3(a)). The use

of cadaver donor graft may have complicated the surgical outcome. A published study has shown that cadaver tissue failed in 23% of patients younger than 40 in ligament reconstructive surgeries [27], questioning their reliability in children. Further, the potential for communicable disease transmission in a young child is concerning. The child was discharged from care at the age of 6.5 years from the outside institution and eventually came to us for treatment.

Two months following triangle tilt surgery, initial post-SARO images showed neutral position of the affected shoulder and significant improvement in overall arm and shoulder position. The shoulder appeared congruent and the arm was straight (Figure 2(b)). The girl was able to perform much improved hand to mouth movements postoperatively (Figures 3(b) and 3(c)). We do not have follow-up pictures for other functional movements.

#### 5. Conclusion

The OBPI patient in this study clearly showed noticeable clinical and functional improvements after triangle tilt surgical management. The posture of the arm at rest was greatly improved to a more normal position, and hand to mouth movement was improved as well. Triangle tilt surgery should be conducted as a first choice treatment for medial rotation contracture of the shoulder in OBPI patients.

#### Consent

Written informed consent was obtained from the patient for publication and accompanying images. A copy of the written consent is available for review on request.

#### Conflict of Interests

The authors report that there is no conflict of interests.

## References

- [1] R. Jelsema, "Decreased brachial plexus palsy after institution of shoulder dystocia protocol," *American Journal of Obstetrics and Gynecology*, vol. 206, no. 5, p. e3, 2012.
- [2] D. M. Dines, R. F. Warren, A. Inglis, and H. Pavlov, "The coracoid impingement syndrome," *Journal of Bone and Joint Surgery B*, vol. 72, no. 2, pp. 314–316, 1990.
- [3] M. Mollberg, H. Hagberg, B. Bager, H. Lilja, and L. Ladfors, "High birthweight and shoulder dystocia: the strongest risk factors for obstetrical brachial plexus palsy in a Swedish population-based study," *Acta Obstetrica et Gynecologica Scandinavica*, vol. 84, no. 7, pp. 654–659, 2005.
- [4] M. A. Alsammani and S. R. Ahmed, "Fetal and maternal outcomes in pregnancies complicated with fetal macrosomia," *North American Journal of Medical Sciences*, vol. 4, no. 6, pp. 283–286, 2012.
- [5] M. M. Al-Qattan, "Obstetric brachial plexus palsy associated with breech delivery," *Annals of Plastic Surgery*, vol. 51, no. 3, pp. 257–264, 2003.
- [6] B. Backe, E. B. Magnussen, O. J. Johansen, G. Sellaeg, and H. Russwurm, "Obstetric brachial plexus palsy: a birth injury not explained by the known risk factors," *Acta Obstetrica et Gynecologica Scandinavica*, vol. 87, no. 10, pp. 1027–1032, 2008.
- [7] R. K. Nath, N. Kumar, M. B. Avila et al., "Risk factors at birth for permanent obstetric brachial plexus injury and associated osseous deformities," *ISRN Pediatrics*, vol. 2012, Article ID 307039, 7 pages, 2012.
- [8] M. S. Kreitzer, "Severe brachial plexus palsy in women without shoulder dystocia," *Obstetrics and Gynecology*, vol. 121, no. 3, pp. 685–686, 2013.
- [9] A. F. Hoeksma, A. M. Ter Steeg, R. G. Nelissen, W. J. Van Ouwkerk, G. J. Lankhorst, and B. A. De Jong, "Neurological recovery in obstetric brachial plexus injuries: an historical cohort study," *Developmental Medicine and Child Neurology*, vol. 46, no. 2, pp. 76–83, 2004.
- [10] A.-L. Lagerkvist, U. Johansson, A. Johansson, B. Bager, and P. Uvebrant, "Obstetric brachial plexus palsy: a prospective, population-based study of incidence, recovery, and residual impairment at 18 months of age," *Developmental Medicine and Child Neurology*, vol. 52, no. 6, pp. 529–534, 2010.
- [11] W. Pondaag, G. J. van Dijk, and M. J. A. Malessy, "Obstetric brachial plexus palsy," *Developmental Medicine and Child Neurology*, vol. 52, no. 6, p. 502, 2010.
- [12] R. K. Nath, *Obstetric Brachial Plexus Injuries-Erb's Palsy: The Nath Method of Diagnosis and Treatment*, VBW Publishing, College Station, Tex, USA, 2007.
- [13] M. M. Hoffer and G. J. Phipps, "Closed reduction and tendon transfer for treatment of dislocation of the glenohumeral joint secondary to brachial plexus birth palsy," *Journal of Bone and Joint Surgery A*, vol. 80, no. 7, pp. 997–1001, 1998.
- [14] M. L. Pearl, "Arthroscopic release of shoulder contracture secondary to birth palsy: an early report on findings and surgical technique," *Arthroscopy—Journal of Arthroscopic and Related Surgery*, vol. 19, no. 6, pp. 577–582, 2003.
- [15] D. I. Pedowitz, B. Gibson, G. R. Williams, and S. H. Kozin, "Arthroscopic treatment of posterior glenohumeral joint subluxation resulting from brachial plexus birth palsy," *Journal of Shoulder and Elbow Surgery*, vol. 16, no. 1, pp. 6–13, 2007.
- [16] S. B. S. Kambhampati, R. Birch, C. Cobiella, and L. Chen, "Posterior subluxation and dislocation of the shoulder in obstetric brachial plexus palsy," *Journal of Bone and Joint Surgery B*, vol. 88, no. 2, pp. 213–219, 2006.
- [17] R. K. Nath, A. B. Lyons, S. E. Melcher, and M. Paizi, "Surgical correction of the medial rotation contracture in obstetric brachial plexus palsy," *Journal of Bone and Joint Surgery—Series B*, vol. 89, no. 12, pp. 1638–1644, 2007.
- [18] R. K. Nath, S. E. Melcher, and M. Paizi, "Surgical correction of unsuccessful derotational humeral osteotomy in obstetric brachial plexus palsy: evidence of the significance of scapular deformity in the pathophysiology of the medial rotation contracture," *Journal of Brachial Plexus and Peripheral Nerve Injury*, vol. 1, no. 1, article 9, 2006.
- [19] R. K. Nath, A. Amrani, S. E. Melcher, and M. G. Eichhorn, "Triangle tilt surgery in an older pediatric patient with obstetric brachial plexus injury," *ePlasty*, vol. 9, article e26, 2009.
- [20] R. K. Nath, X. Liu, S. E. Melcher, and J. Fan, "Long-term outcomes of triangle tilt surgery for obstetric brachial plexus injury," *Pediatric Surgery International*, vol. 26, no. 4, pp. 393–399, 2010.
- [21] R. K. Nath, C. Somasundaram, S. E. Melcher, M. Bala, and M. J. Wentz, "Arm rotated medially with supination—the ARMS variant: description of its surgical correction," *BMC Musculoskeletal Disorders*, vol. 10, article 32, 2009.
- [22] R. K. Nath, A. Amrani, S. E. Melcher, M. J. Wentz, and M. Paizi, "Surgical normalization of the shoulder joint in obstetric brachial plexus injury," *Annals of Plastic Surgery*, vol. 65, no. 4, pp. 411–417, 2010.
- [23] R. K. Nath, M. B. Avila, and P. Karicherla, "Triangle tilt surgery as salvage procedure for failed shoulder surgery in obstetric brachial plexus injury," *Pediatric Surgery International*, vol. 26, no. 9, pp. 913–918, 2010.
- [24] R. K. Nath, C. Somasundaram, and F. Mahmooduddin, "Comparing functional outcome of triangle tilt surgery performed before versus after two years of age," *The Open Orthopaedics Journal*, vol. 5, pp. 59–62, 2011.
- [25] R. K. Nath and M. Paizi, "Scapular deformity in obstetric brachial plexus palsy: a new finding," *Surgical and Radiologic Anatomy*, vol. 29, no. 2, pp. 133–140, 2007.
- [26] R. K. Nath and X. Liu, "Nerve reconstruction in patients with obstetric brachial plexus injury results in worsening of glenohumeral deformity: a case-control study of 75 patients," *Journal of Bone and Joint Surgery—Series B*, vol. 91, no. 5, pp. 649–654, 2009.
- [27] American Orthopaedic Society for Sports Medicine, "News release," in *Proceedings of the American Orthopaedic Society for Sports Medicine's Annual Meeting*, American Academy of Orthopaedic Surgeons, Orlando, Fla, USA, July 2008.