

# Recurrent Orbital Cavernous Hemangioma due to Overlooked Multiple Tumors

Abbas Bagheri, MD; Sakineh Khandan, MD; Hossein Salour, MD  
Maryam Aletaha, MD; Alireza Abrishami, MD

*Ophthalmic Research Center, Shahid Beheshti University of Medical Sciences, Tehran, Iran*

**Purpose:** To report late recurrence of orbital cavernous hemangioma in a patient ten years after complete resection of the primary tumor.

**Case Report:** A 32-year-old woman with a history of progressive visual loss and proptosis underwent lateral orbitotomy for resection of a large cavernous hemangioma. Ten years later, proptosis recurred and the patient developed progressive ocular deviation. Imaging studies were in favor of a recurrent cavernous hemangioma and the tumor was excised via the previous incision site. Reassessment of previous orbital images suggested the presence of two separate tumors, only one of which had been excised at the time of initial surgery.

**Conclusion:** Recurrent orbital cavernous hemangioma may follow incomplete excision of multiple orbital lesions with gradual growth of unidentified residual tumors. Accordingly, when an encapsulated cavernous hemangioma is removed, exploration is recommended to rule out multiple lesions.

**Keywords:** Cavernous Hemangioma; Multiple Orbital Tumors; Recurrent Orbital Tumors

*J Ophthalmic Vis Res* 2012; 7 (3): 244-247.

**Correspondence to:** Abbas Bagheri, MD. Professor of Ophthalmology, Labbafinejad Medical Center, Paidarfard St., Boostan 9 St., Pasdaran, Tehran 16666, Iran; Tel: +98 (21) 2258 5952, Fax: +98 (21) 2259 0607; e-mail: abbasbagheri@yahoo.com

**Received:** December, 2011

**Accepted:** June 10, 2012

## INTRODUCTION

Cavernous hemangioma is the most common primary benign tumor of the orbit in adults.<sup>1</sup> Bilateral and multiple cavernous hemangiomas are rare. The most prevalent complaint with these lesions is progressive painless proptosis.<sup>2,3</sup>

Incompletely resected cavernous hemangiomas have previously been described and a few cases of multiple uni- or bilateral cavernous hemangiomas of the orbit have been reported. Recurrent cavernous hemangiomas have been described in association with systemic tumors, however tumor recurrence due to multiplicity of the primary lesion has not been reported.<sup>4-12</sup>

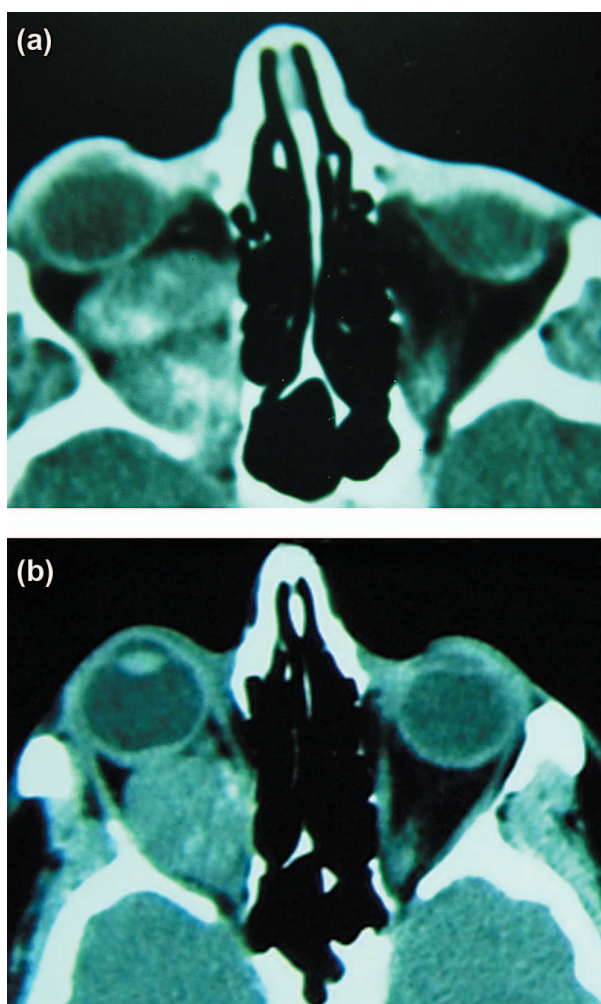
Herein, we report recurrence of orbital cavernous hemangioma in a middle-aged woman 10 years after apparently complete resection of the primary tumor; the cause seemed to be overlooking multiple primary cavernous hemangiomas and continuous growth of the missed lesion.

## CASE REPORT

A 32-year-old woman presented with gradually decreasing vision and progressive hyperopia of several months' duration in 1999. Best corrected visual acuity (BCVA) was 20/200 and 20/15 with optical correction of +4.5 diopters (D) and plano in her right and left eyes, respectively. There was

1+ relative afferent pupillary defect (RAPD) in the right eye. Hertel exophthalmometry revealed 6 millimeters (mm) of proptosis in the right eye (readings were 25 mm for the right eye and 19 mm for the left eye) with no limitation in eye movements. Fundus examination disclosed right optic disc edema. Orbital computed tomography (CT) scan with contrast revealed a large septated intraconal mass lesion in the right orbit displacing the optic nerve superiorly (Fig. 1a). Magnetic resonance imaging (MRI) was not performed at that point.

With an initial impression of orbital cavernous hemangioma, the patient underwent lateral orbitotomy and an encapsulated mass was



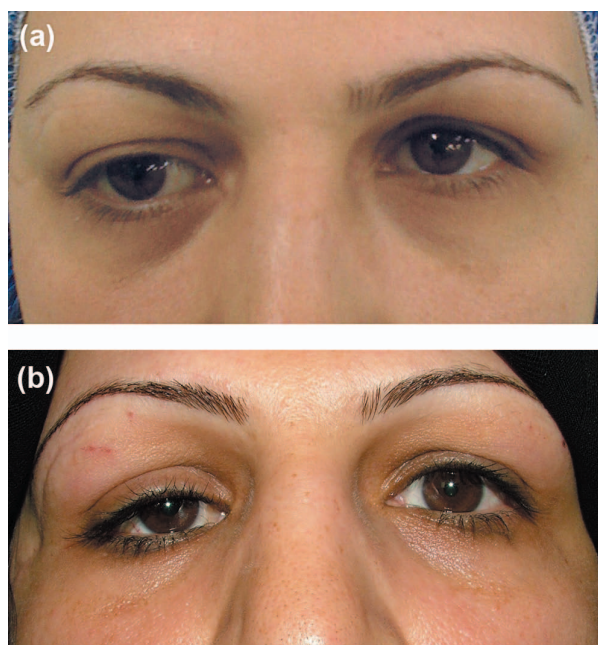
**Figure 1.** Contrast enhanced axial computed tomography (CT) scan of the orbit at initial presentation; two separate tumors are suspected (a). Axial CT scan of the orbit prior to the second operation demonstrates an enhancing mass lesion within the right intraconal space; note the site of previous osteotomy (b).

completely excised. Histopathologic examination confirmed the presumptive diagnosis.

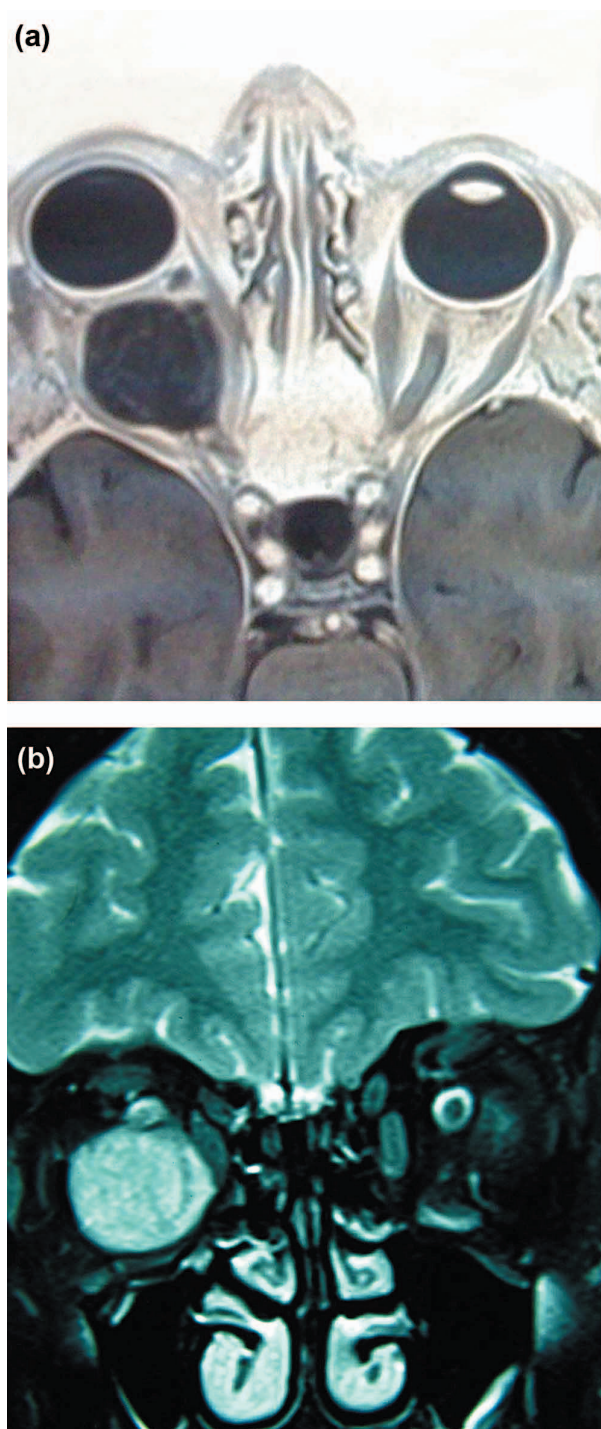
Ten years later, the patient presented with recurrent proptosis of the right eye together with downward displacement of the globe. BCVA in the right eye was counting fingers at 2 meters with 3+ RAPD. External examination revealed 9 mm of proptosis together with hypoglobus and exotropia in the right eye (Fig. 2a). In addition, limitation of upward gaze was noted. Orbital CT scan revealed a soft tissue mass in the intraconal space engulfing the optic nerve (Fig. 1b). Contrast-enhanced MRI demonstrated a smooth intraconal mass lesion which was hypointense on T<sub>1</sub>-weighted images and hyperintense on T<sub>2</sub>-weighted images, compressing and displacing the optic nerve superonasally (Figs. 3a and 3b).

Right lateral orbitotomy was performed through the previous incision and an elliptical strawberry-like encapsulated mass lesion was completely excised. Light microscopy confirmed the tumor to be a cavernous hemangioma.

One month after the operation, proptosis, limited motility and hypoglobus had improved, but visual acuity was limited to counting fingers at 3 meters in the right eye (Fig. 2b).



**Figure 2.** Proptosis and hypoglobus of the right eye at second presentation; note the scar of the previous surgery (a). Appearance of the patient one month after reoperation shows improved proptosis and globe displacement (b).



**Figure 3.** Orbital MRI before the second operation shows an enhancing mass in the right intraconal space; axial section (a), coronal section (b).

## DISCUSSION

Cavernous hemangioma is an acquired vascular tumor which develops as a result of proliferation of capillaries over an extended period of time

together with enlargement of vascular channels and appearance of a smooth muscle wall.<sup>1-3</sup> Due to its low neoplastic potential, this tumor is thought to be the result of hamartomatous growth of vestigial vascular remnants under the influence of local hemodynamic abnormalities.<sup>2</sup>

Tumor recurrence following resection may occur in three contexts: continuous growth of an incompletely resected tumor, growth of an overlooked tumor which had been present in the neighborhood of the previously resected lesion, and finally appearance of a new tumor.

Henderson et al reported a 43-year-old man whose cavernous hemangioma was incompletely resected and followed for 18 years with serial CT scans.<sup>4</sup> The tumor showed a protracted course of growth followed by a short period of arrest and finally involution with resolution of proptosis. In a report by Yan and Wu, only three cases of recurrence secondary to incomplete resection were reported.<sup>3</sup> In contrast, Harris and Jacobiec reported no recurrence in cases who had undergone incomplete tumor resection.<sup>2</sup> The presence of a complete capsule around the primary tumor in the patient reported herein speaks against the possibility of regrowth from incomplete resection.

Reports of multiple and recurrent cavernous hemangiomas generally fall in two categories; one includes sporadic or non-syndromal tumors with no systemic involvement,<sup>5-10</sup> and the second comprises of systemic syndromes such as the blue rubber bleb nevus syndrome or Maffuci's syndrome.<sup>11,12</sup>

In the study by Yan and Wu, four patients had multiple tumors in one orbit.<sup>3</sup> In the report by Harris and Jakobiec, a 36-year-old woman had 5 tumors in one orbit.<sup>2</sup> Wolin et al reported accidental detection of two separate cavernous hemangiomas in the right orbit of a 48-year-old woman.<sup>5</sup> Bhattacharjee et al reported multiple extra- and intraconal orbital cavernous hemangiomas in the right orbit of a 7-year-old boy which were incompletely resected.<sup>6</sup> Some cases of bilateral orbital cavernous hemangiomas have also been reported.<sup>7-9</sup> Sullivan et al<sup>10</sup> reported a 41-year-old woman with multiple bilateral cavernous hemangiomas without systemic involvement while Chang

et al<sup>11</sup> reported multiple bilateral cavernous hemangiomas associated with the blue rubber bleb nevus syndrome.

Recurrences have been less frequently reported. Harris and Jakobiec reported a patient who had a new tumor in the same orbit many years after complete resection of the first tumor.<sup>2</sup> Limawararut et al reported a 35-year-old woman with multiple intraconal cavernous hemangiomas in the right orbit which were completely removed, but 15 years later multiple cavernous hemangiomas recurred in the same orbit and systemic evaluation demonstrated cavernous hemangioma in the liver and a schwannoma in one of the thoracic vertebrae.<sup>12</sup>

Two probable mechanisms may explain the condition in our patient. One is the presence of a tiny coincidental tumor which was missed during the initial operation and became symptomatic after some years. The second probability is the appearance of a new cavernous hemangioma at the same site. Based on reassessment of old CT scans, the most probable explanation for this scenario is the coexistence of two separate tumors, the larger of which was resected while the smaller one was missed and continued to grow. The size of multiple orbital tumors can be very different which supports the theory that recurrence is truly secondary to missed small tumors not noticed by radiologists and surgeons.<sup>10,12</sup>

In conclusion, when large septated multilobulated orbital tumors are encountered on imaging, the possibility of multiple tumors must be considered and cautiously explored during surgery to prevent reoperations. MRI may help in the diagnosis of multiple tumors.

#### Conflicts of Interest

None.

#### REFERENCES

1. Shields JA, Shields CL, Scartozzi R. Survey of 1264 patients with orbital tumors and simulating lesions: The 2002 Montgomery Lecture, part 1. *Ophthalmology* 2004;111:997-1008.
2. Harris GJ, Jakobiec FA. Cavernous hemangioma of the orbit. *J Neurosurg* 1979;51:219-228.
3. Yan J, Wu Z. Cavernous hemangioma of the orbit: analysis of 214 cases. *Orbit* 2004;23:33-40.
4. Henderson JW, Farrow GM, Garrity JA. Clinical course of an incompletely removed cavernous hemangioma of the orbit. *Ophthalmology* 1990;97:625-628.
5. Wolin MJ, Holds JB, Anderson RL, Mamalis N. Multiple orbital tumors were cavernous hemangioma. *Ann ophthalmol* 1990;22:426-428.
6. Bhattacharjee K, Bhattacharjee H, Deka A. Acute progressive multiple cavernous hemangiomas of orbit in a child - a case report. *Orbit* 2007;26:117-119.
7. Fries PD, Char DH. Bilateral orbital cavernous haemangiomas. *Br J Ophthalmol* 1988;72:871-873.
8. Ohbayashi M, Tomita K, Agawa S, Sichijo F, Shinno K, Matsumoto K. Multiple cavernous hemangiomas of the orbits. *Surg Neurol* 1988;29:32-34.
9. Shields JA, Hogan RN, Shields CL, Eagle RC Jr, Kennedy RH, Singh AD. Bilateral cavernous haemangiomas of the orbit. *Br J Ophthalmol* 2000;84:928.
10. Sullivan TJ, Aylward GW, Wright JE, Moseley IF, Garner A. Bilateral multiple cavernous haemangiomas of the orbit. *Br J Ophthalmol* 1992;76:627-629.
11. Chang EL, Rubin PA. Bilateral multifocal hemangiomas of the orbit in the blue rubber bleb nevus syndrome. *Ophthalmology* 2002;109:537-541.
12. Limawararut V, Davis G, Crompton J, Leibovitch I, Selva D. Recurrent multiple cavernous hemangiomas of the orbit in association with systemic tumors. *Am J Ophthalmol* 2006;141:943-945.