

Application of Orthodontic Immediate Force on Dental Implants: Histomorphologic and Histomorphometric Assessment

Mansour Rismanchian, Sayed Hamid Raji¹, Sayed Mohammad Razavi², Danesh Teimouri Rick³, Amin Davoudi⁴

Department of Prosthodontics, ²Oral and Maxillofacial Pathology, Dental Implants Research Center, School of Dentistry, ¹Department of Orthodontics, Dental Research Center, School of Dentistry, Isfahan University of Medical Sciences, ⁴Department of Prosthodontics, Dental Students Research Committee, School of Dentistry, Isfahan University of Medical Sciences, Isfahan, ³Department of Prosthodontist, Private Practice, Tavana Dental Clinic, Rasht, Iran

Abstract

Aims: Application of force to implants is helpful, especially in orthodontic-implant therapies. The aim of this study was a histomorphologic and histomorphometric evaluation of peri-implant bone after immediate orthodontic and orthopedic forces comparing them with a control group. **Materials and Methods:** Eighteen dental titanium implants were inserted in the premolar region of three dogs. Implants were divided into three groups: (1) group with immediate orthodontic force of 300 NC, (2) group with immediate orthopedic force of 600 NC, and (3) control group. Implants were explanted with adequate amount of surrounding bone after 3 months and bone-implant contact (BIC), amount of lamellar bone (LB), amount of woven bone (WB), amount of inflammatory connective tissue, and the rate of the movement were investigated. ANOVA, *t*-test, paired *t*-test, and Pearson's test were used to analyze the data using SPSS software version 16 at a significant level of 0.05. **Results:** Based on BIC, amount of lamellar and WB and the amount of inflammatory connective tissue, there was no significant difference between the three groups (300 centinewton (CN), 600–CN, and control group) ($P > 0.05$). In the 300–CN and 600–CN groups, the rate of movement was reported 0.41 and 0.94 with no significant differences ($P = 0.38$). **Conclusion:** 300–CN and 600–CN immediate static loads do not interfere with osseointegration phenomenon and it does not decrease the amount of BIC and LB. Implants can be moved by preserving osseointegration, and this movement is in direct relation with the amount of applied force.

Keywords: Bone-implant contact, dental implants, orthodontic immediate force, osseointegration

INTRODUCTION

Optimal implant location is an important therapeutic goal in implant dentistry which leads to an ideal occlusion and esthetic.^[1] Application of force to implants is helpful, especially in orthodontic-implant therapies. This treatment plan is growing among middle-aged patients, those who require tooth replacement and tooth location correction, and patients with anatomical limitations who receive misplaced implants and need to have their implants location corrected due to biomechanical and esthetic reasons.^[1] In some cases, due to biomechanical and anatomical limitations, the proper angulation of implants is compromised. To reach an appropriate prosthetic treatment outcome, angulation correction by applying orthodontic forces is required for misplaced implants.

Some studies state that immediate forces on implants lead to fibrous tissue formation around them, rather than direct bone contact,^[2,3] which is critical for a successful implant treatment.^[4] This theory arises from the idea that the necrotic bone, which surrounds newly placed implants, is not able to bear forces and to apply functional loads, new bone should be replaced;^[2,4,5] however, recent studies demonstrate that immediate force will not necessarily cause fibrous tissue formation,^[6] and it even stimulates the formation of a

Address for correspondence: Dr. Danesh Teimouri Rick,
Tavana Dental Clinic, Rasht, Iran.
E-mail: teimouririck@yahoo.com

This is an open access article distributed under the terms of the Creative Commons Attribution-NonCommercial-ShareAlike 3.0 License, which allows others to remix, tweak, and build upon the work non-commercially, as long as the author is credited and the new creations are licensed under the identical terms.

For reprints contact: reprints@medknow.com

How to cite this article: Rismanchian M, Raji SH, Razavi SM, Rick DT, Davoudi A. Application of orthodontic immediate force on dental implants: Histomorphologic and histomorphometric assessment. *Ann Maxillofac Surg* 2017;7:11-7.

Access this article online

Quick Response Code:



Website:
www.amsjournal.com

DOI:
10.4103/ams.ams_35_15

mature lamellar bone (LB) which is resistant to forces.^[4,7] Today, scientists believe that implants with an appropriate initial stability can receive immediate forces.^[8,9] In a study by Oyonarte *et al.*, it was shown that implants, which were planted to provide an orthodontic anchorage, were moved due to applied forces exactly after primary osseointegration and the osseointegration condition did not change. Moreover, bone density and bone height were greater at the site of force application.^[10] Crismani *et al.* in his study on implants which were planted in palate, showed that 400-centinewton (CN) orthodontic force one week after implantation, led to 90% success rate, and increase in stability after 12 weeks.^[11] Turley *et al.* investigated the bone remodeling around 42 maxillary and mandibular implants of 6 dogs, showing higher rates for implants with orthodontic forces.^[12] Now, the question is that will a direct contact between bone and implants occur if forces are applied before osseointegration? will this contact be the same at both tension and pressure sides? And can we move the implants with preservation of osseointegration? The present study was designed to histomorphologically and histomorphometrically assess the peri-implant bone following an application of immediate orthodontic and orthopedic forces and compare it with the control group.

MATERIALS AND METHODS

Preparation of dogs

In this interventional and experimental study, three Iranian mixed-breed healthy dogs weighing around 25 kg and aged 2–3 years were involved.

First, to prevent probable cross infection of diseases, all dogs were vaccinated (the vaccines included: rabies, influenza, hepatitis, leptospirosis, and distemper), then 10 mg ketamine vials and 0.15 mg Rampon (Alfasan, Woerden, The Netherlands) were injected intramuscularly to prepare appropriate anesthesia. To continue anesthetic procedures, Isoflurane (Baxter, IL, USA) was used, and dextrose saline serum (Mahban Darou, Tehran, Iran) was used to balance electrolytes.

Lateral cephalometric radiographies were taken from maxilla and mandible of dogs. Impressions were taken from upper and lower jaws using polyvinyl siloxane (Asia Chemi Teb Co., Tabriz, Iran, under the license of Coltene-Switzerland) to make special trays. Dogs' mouths were rinsed by chlorhexidine (Shahr darou Laboratories, Tehran, Iran). According to the Helsinki declaration, first to fourth premolars were extracted. For each quadrant of the dogs' mouth, 2 cartridges of lidocaine (Mahban Darou, Tehran, Iran) were used to reduce bleeding.

Implants insertion

Three months after, tooth extraction and proper bone healing, the dogs were anesthetized, following mentioned procedures. In addition, silicone impressions were taken from each quadrant to provide surgical stents for placing implants as parallel as possible to each other. To ensure appropriate healing of extraction sites, periapical and lateral cephalograms were

taken. ITI implants (with 10 mm length and 4.1 mm diameter) with SLA surface (Institut Straumann AG, Basel, Switzerland) were provided.

After appropriate healing of the extraction site with intact bone formation, crestal incision was performed, and then periosteum was retracted by periosteal elevator. Bone was prepared in the implants site by 2.3 mm diameter round burs (round bur; stainless steel, Institut Straumann, Basel, Switzerland). Implants site preparation was done by following 4-step procedure:

1. Cortical bone was perforated by starter surgical bur with 1.4 mm diameter
2. 2.2 mm diameter pilot drill was used (pilot drill 1, short, Ø2.2 mm, length 33 mm, stainless steel, Institut Straumann, Basel, Switzerland)
3. 2.8 mm diameter pilot drill was used (pilot drill 2, short, Ø2.8 mm, Length 33 mm, stainless steel, Institut Straumann, Basel, Switzerland)
4. In the final step, twist drill with 3.5 mm diameter was used (twist drill 1, short, Ø3.5 mm, length 33 mm, stainless steel, Institut Straumann, Basel, Switzerland).

The burs were used according to manufacturer instruction, and the speed was 800 rounds/min. For all of these procedures, physiological serum was used as a coolant agent.

Alignment pins (Ø2.2 mm, length 28 mm, titanium, Institut Straumann, Basel, Switzerland) and prepared surgical stents were used to make sure that the implants were placed parallel. The distance between two implants from the control group was at least 2 cm.

Insertion torque was recorded using a torque wrench (Drehmoment Ratsche, 20–60 Ncm, Dr Dental AG, Gommiswald, Switzerland) and implant stability quotient was calculated by means of Osstell (Integration Diagnostic, Svedalen, Sweden) in buccolingual and mesiodistal aspects. Before screwing the abutments, impressions of implants were taken by Open Tray Technique. To record the distance between implants (of both case and control groups), transfer copings were attached to them as abutments, followed by measuring the distance using a digital caliper (Mitutoyo, Kanagawa, Japan) with 0.01 mm accuracy. Each measurement was repeated twice, and the mean amount was considered. To make sure that the bone around each screw would not interfere with the bone around adjacent screw, 20 mm distance was considered between screws. After placing the three implants in each quadrant (in the site of extracted first to fourth premolars), periapical radiographs were prepared for the analysis of the bone and bone resorption. In addition, vertical height from shoulder of the implant to crest of bone was measured in mesial and distal aspects.

Orthodontic force application

To apply forces to implants, implants mounts were not removed. Immediately after placement of the implants, Ni-Ti coil springs (Sentalloy, GAC, Central Islip, NY, USA) were

attached to the middle part of 6 implants' mounts by means of 0.012" ligature wires, in the way that the springs were stretched 20 mm (to have 300-CN force).

Six hundred centinewton force was applied to other 6 implants. Since appropriate Ni-Ti coil springs which apply 600-CN force were not found, 2 springs similar to those with 300-CN force were used simultaneously. It has been stated that applied force to the implant should be at minimum of 300-CN and maximum of 600-CN to make deformation of cortical and trabecular bone without significant necrosis.^[13]

Last 6 implants were considered as control group, and they were not loaded.

Postoperative care

After the operation, dogs received an intramuscular ampule of Penicillin G Benzathine/Procaine Sodium 2:1:1 (Jaber-Pharma, Tehran, Iran) and a neutralized Sulfonamide (Pentrizole) (Jaber-Pharma, Tehran, Iran) 1cc/kg. To keep the dog's oral health in an optimum condition, 0.12% chlorhexidine mouth rinse and brushing were used weekly. The dogs were fed with cooked ground chicken once a day from the day after the operation on.

Changes follow-up

Six weeks after surgery, following anesthetizing the dogs, their mouths were rinsed using brush and chlorhexidine, springs were detached, and their force was rechecked. Furthermore, the stability of implants was assessed at this stage. Any loose implants were removed and replaced with a mini-implant on each side to continue the force application. After preparing and checking periapical radiographs, the springs were attached again. We have to mention that the springs were replaced only if deformation occurred. Twelve weeks after surgery, apical radiographs were provided in addition to final lateral cephalometric radiographs. Then, implants and springs were cleaned using chlorhexidine and brush, and the forces were checked followed by removing the springs. Afterward, the distances between implants were remeasured intraorally, by the same researchers, using the same unit. At this stage also, the measurements were repeated twice and the mean amount was considered.

Sterile techniques were considered during all procedures.

Extracting the specimens

Trephine burs with 10 mm diameter were used, to cut implants with adequate amount of bone out.

Histological preparation

Extracted specimens were kept in a glutaraldehyde solution for 6 h. Embedded in series of graded alcohol, they were dehydrated and mounted precisely in a self-cured transparent acrylic resin (Meliudent; Heraeus kulzer, Berkshire, UK). Ground sections were then prepared, using Microtome (Accutom-50, Stuers, Copenhagen, Denmark). Sections were made along implants' frontal axis and in mesiodistal dimension with approximate 250–350 μ m thickness. The specimens were then thinned to

100-150 μ m using an abrasive. Following immersion of the specimens in glutaraldehyde (24 h), graded alcohol (50%, 60%, 70%, 80%, 90, and 100% concentrations; each for 2 h) and Eksikator including calcium and chlorine and covering the specimens with gold, the specimens were studied under electron microscope. Micrographs were provided with $\times 50$, $\times 200$ and $\times 1600$ magnification (Zeiss, Jena, Germany) from mesial and distal (4 micrographs altogether).

Statistical analysis

ANOVA, *t*-test, paired *t*-test, and Pearson's test were used to analyze the data using SPSS software version 16 (IBM corporation, NY, USA) at a significant level of 0.05.

Ethical considerations

Ethical approval was granted by the Torabinejad Dental Research Center with ID number of 287243. All procedures were conducted strictly in accordance with ethical standards and with the last update of the Helsinki declaration. The maintenance and care of the animals complied with the ethical guidelines of the Torabinejad Dental Research Center, Isfahan University of Medical Sciences, Isfahan, Iran. To preserve dogs' chewing ability, their main posterior teeth (counted as molars) were not extracted. In this study, dogs were not euthanized after the procedures.

RESULTS

One of the implants with 300-CN force and two of them with 600-CN forces were excluded from the study because of getting loose with no sign of inflammation or infection. In addition, one implant in control group was excluded because of bone damage during explanting the implant. Altogether, 5 implants with 300-CN, 4 implants with 600-CN, and 5 control implants remained. In this study, total bone-implant contact (BIC), total woven and LB, inflammatory and connective tissues were investigated separately at the tension and pressure sites [Figure 1].

Furthermore, to simplify the understanding of the evaluated criteria, abbreviations were used which are presented at Table 1.

Bone-implant contact

Mean total percentage of BIC (ToBIC) was $81.62\% \pm 13.62\%$ for 600-CN group, 79.80 ± 9.25 for 300-CN group, and 71.98 ± 13.5 for control group [Table 2]. The mean ToBIC, BIC at tension side and pressure side were not significantly different among the studied groups (300-CN, 600-CN, and control) ($P > 0.05$).

Peri-implant lamellar bone

The mean percentage of total LB within 2 mm around implants was 62.40 ± 1.94 for control group, 62.10 ± 2.10 for 300-CN group, and 59.43 ± 2.63 for 600-CN group [Table 3]. Mean percentage of peri-implant LB at pressure side (PLB) for control group, 300-CN group, and 600-CN group was 62.40 ± 2.30 , 62.60 ± 3.36 and 60.12 ± 2.17 , respectively.

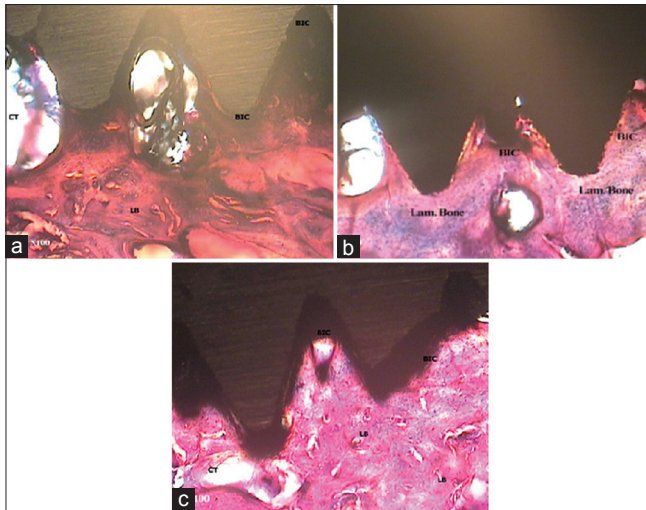


Figure 1: Histopathological observation of bone-implant contact and surrounded tissues among different groups (600-CN [a], 300-CN [b], and control [c]) at $\times 100$ magnification after 12 weeks applying orthodontic forces

Mean percentage of peri-implant LB at tension side (TLB) was 62.40 ± 2.30 , 61.60 ± 1.51 and 58.75 ± 3.20 for mentioned groups, respectively. The mean TLB and PLB did not show significant differences among groups (300-CN, 600-CN, and control) ($P > 0.05$).

Peri-implant woven bone

Mean percentage of total peri-implant woven bone within 2 mm around implant for control group, 300-CN group, and 600-CN group was 31.93 ± 0.68 , 31.4 ± 3.13 , and 33.31 ± 0.80 , respectively [Table 4]. The mean TLB and PLB had not significant differences among groups (300-CN, 600-CN, and control) ($P > 0.05$).

Connective and inflammatory tissue around implant

Mean amount of connective and inflammatory tissues (CITs) within 2 mm around the implants were measured [Table 5]. No significant difference was observed among groups for each observed criteria (all $P > 0.05$).

Implants movement

Mean rate of orthodontic movement of implants was 0.41 ± 0.41 mm/12 week in 300-CN group and was 0.94 ± 0.90 mm/12 weeks in 600-CN was. Mann–Whitney test revealed no significant differences in the mean rate of implants movement between two groups (600-CN and 300-CN) ($P = 0.38$); however, the movement rate of 600-CN and 300-CN implants was significantly different in both groups from the control group ($P < 0.05$).

DISCUSSION

Recent studies have shown that immediate prosthetic forces which are applied on dental implants not only lower the risk of fibrous tissue formation but also stimulate the formation of mature LB which is resistant against destructive forces.^[4,6,7] On the other hand, it is also possible to apply forces to

Table 1: The abbreviations with proper definitions used in the study

Abbreviation	Definition
CN	Centimeter newton
ISQ	Implant stability quotient measured by Osstell
SLA	Sandblasted, large grit, and acid-etched implants
LB	Lamellar bone
WB	Woven bone
BIC	Bone-implant contact
ImpM	Implant movement
ToBIC	Total percentage of bone-implant contact
TBIC	Bone-implant contact at tension side
PBIC	Bone-implant contact at pressure side
ToLB	Total percentage of observed lamellar bone at 2 mm surrounded bone of implant
ToWB	Total percentage of observed woven bone at 2 mm surrounded bone of implant
PWB	Woven bone at pressure side
TWB	Woven bone at tension side
PLB	Lamellar bone at pressure side
TLB	Lamellar bone at tension side
ToCIT	Total percentage of connective and inflammatory tissues around the implant
PCIT	Connective and inflammatory tissues around the implant at pressure side
TCIT	Connective and inflammatory tissues around the implant at tension side

Table 2: Statistical indexes of total bone-implant contact (%), bone-implant contact at tension side, and bone-implant contact at pressure side of 300-CN, 600-CN, and control groups after 12 weeks

Group	Mean \pm SD	Minimum	Maximum	P
ToBIC				
300-CN	79.80 \pm 9.25	70.00	91.00	0.460
600-CN	81.62 \pm 13.62	66.50	94.00	
Control	71.98 \pm 13.50	59.50	91.75	
PBIC				
300-CN	80.40 \pm 8.64	73.00	92.00	0.354
600-CN	81.62 \pm 13.88	66.00	95.00	
Control	70.86 \pm 13.35	58.00	90.00	
TBIC				
300-CN	79.20 \pm 10.23	67.00	90.00	0.578
600-CN	81.62 \pm 13.40	67.00	93.00	
Control	73.10 \pm 13.67	61.00	93.50	

SD=Standard deviation; ToBIC=Total percentage of bone-implant contact; PBIC=Pressure side bone-implant contact; TBIC=Tension side bone-implant contact

mini-implants. Therefore, if we apply orthodontic forces to dental implants and their surrounding bone behaves as there was only an immediate prosthetic loading without orthodontic forces, the quality of prosthetic treatments will significantly improve.

In the present study, a number of criteria, including BIC, lamellar and WB formation, fibrous tissue formation and

Table 3: Statistical indexes for lamellar bone around implant (%) within 2 mm, total, at pressure side, and at tension side after 12 weeks

Group	Mean±SD	Minimum	Maximum	P
ToLB				
300-CN	62.10±2.10	59.50	64.50	0.143
600-CN	59.43±2.63	55.50	61.00	
Control	62.40±1.94	60.50	65.50	
PLB				
300-CN	62.60±3.36	59.00	67.00	0.365
600-CN	60.12±2.17	57.00	62.00	
Control	62.40±2.30	60.00	65.00	
TLB				
300-CN	61.60±1.51	60.00	63.00	0.100
600-CN	58.75±3.20	54.00	61.00	
Control	62.40±2.30	60.00	66.00	

ToLB=Total percentage of observed lamellar bone; PLB=Lamellar bone at pressure side; TLB=Lamellar bone at tension side; SD=Standard deviation

Table 4: Statistical indexes for woven bone around implant (%) within 2 mm, total, at pressure side, and at tension side after 12 weeks

Group	Mean±SD	Minimum	Maximum	P
ToWB				
300-CN	31.40±3.13	26.00	33.50	0.373
600-CN	33.31±0.80	32.50	34.00	
Control	31.93±0.68	31.00	32.65	
PWB				
300-CN	30.50±3.57	24.50	33.00	0.340
600-CN	32.87±0.62	32.00	33.50	
Control	31.86±1.32	30.00	33.00	
TWB				
300-CN	32.30±2.72	27.50	34.00	0.423
600-CN	33.75±2.06	32.00	36.00	
Control	32.00±0.70	31.00	33.00	

ToWB=Total percentage of observed woven bone; PWB=Woven bone at pressure side; TWB=Woven bone at tension side; SD=Standard deviation

inflammation around implants and also their movements were investigated.

During the study, one of the implants with 300-CN and two of them with 600-CN forces were excluded from the study due to loss of integrity. There was no infection or inflammation around implants, thus the failure can be attributed to the occlusal functional overload, like one implant in Oyonarte's *et al.* study on dogs which was excluded due to same reason.^[14] This finding was consistent with former researches which were conducted on monkeys.^[15,16] In the present study, BIC was not significantly different among groups ($P > 0.05$) and mean values of BIC in the group with 600-CN force were higher than other groups. Oyonarte *et al.* also did not find any significant differences in BIC between control group and implants that had undergone 100 g force for 5 weeks followed by 300 g force for 17 weeks.^[14] Meslen *et al.* in their study, where they had placed 10 implants in 6 monkeys for 11 weeks and applied 100-CN,

200-CN, and 300-CN forces, found that mean BIC was 60.7% at the pressure side and 60.5% at tension side and 58.6% for the control group. No significant difference was observed among the groups.^[17] Satio *et al.* placed 18 Brenmark implants in 4 dogs, and 200 gr forces were applied for 24–32 weeks. In that study also, mean BIC was about 65%, and no difference existed among studied groups.^[18] Wehrbein *et al.* placed 10 implants in premolar area and palate of a dog, each with 10 mm length and 4 mm diameter. The implants underwent 200 gr forces for 26 weeks after an eight-week healing period. Microscopic investigations revealed that no difference was present between studied groups. In addition, it was proved that orthodontic force had even induced bone formation at pressure side.^[19] In the study by Rismanchian *et al.*, 12 implants were placed in mandibles of three dogs, in the way that prosthetic nonfunctional force was applied for 6 implants, and the rest of them kept unloaded beneath the gingiva. In the mentioned study also, BIC was 51.33% and 44.4% for case and control groups, respectively; however, there was no significant difference between them.^[20]

Although BIC rates vary among different studies, they are in accordance with the present study, indicating not only there is no significant difference between control group and case groups but also there is no difference between tension and pressure sides. The difference between BIC is partly due to types of implants, duration of applied force, and also forces intensity since bone integrity is dependent on duration, frequency, type and distribution of force, and stress integrity.^[21] Moreover, in our study, orthodontic and orthopedic forces were applied immediately after implant placement, which can also imply for the different BIC rates compared to the previous studies. In a study by Degidi *et al.* where they investigated the bone remodeling after immediate loading, it was demonstrated that no difference exists between loaded and unloaded implants in terms of bone remodeling; however, higher amounts of LB were found around loaded implants.^[22]

On the other hand, it has been declared that immediate loading can increase the alveolar bone density around implant.^[23] Rismanchian *et al.*, who placed 12 implants in mandibles of 3 dogs followed by immediate loading, demonstrated that no difference exists between osseointegration of loaded and unloaded implants and that formation of lamellar and WB is the same in both groups.^[24]

In the present study also, there was no difference between the groups in terms of formation of lamellar and WB which is consistent with the previous studies, but LB formation in control group was the highest and in 600-CN group was the lowest. This inconsistency with former researches could be attributed to the intensity and type of the force which was applied because mechanical stresses and strains are correlated to bone remodeling.^[25]

The first type of bone formed in orthodontic responses is WB.^[26] This may explain the higher percentage of WB formation in the 600-CN group compared to other groups.

Table 5: Statistical indexes for amount of connective and inflammatory tissues (%) around implant within 2 mm, total, at pressure side and at tension side after 12 weeks

Group	Mean±SD	Minimum	Maximum	P
ToCIT				
300-CN	6.50±1.90	4.50	9.50	0.465
600-CN	7.31±2.30	5.00	10.50	
Control	5.67±1.57	3.50	7.00	
PCIT				
300-CN	6.90±1.74	5.00	8.50	0.627
600-CN	7.12±2.65	5.00	11.00	
Control	5.74±2.52	3.00	9.00	
TCIT				
300-CN	6.10±2.65	4.00	10.50	0.519
600-CN	7.50±2.08	5.00	10.00	
Control	5.60 ± 2.50	2.00	9.00	

TCIT=Connective and inflammatory tissues around the implant at tension side; PCIT=Connective and inflammatory tissues around the implant at pressure side; ToCIT=Total percentage of connective and inflammatory tissues; SD=Standard deviation

In the present study, implants with 300- and 600-CN force moved 0.41 mm and 0.94 mm, respectively. In the study by Oyonarte *et al.*, porous and machined implants which underwent 100 g force for 5 weeks and 300 g for 17 weeks moved 0.12 mm and 0.515 mm, respectively.^[14] In Majzoub's *et al.* study, one of the 20 implants which were placed in rabbit's calvaria with 150 g-force moved 0.5 mm. These results show that the amount of implants' movements depends on numerous criteria.^[26]

In the present study, there was no significant difference among the three groups in terms of CIT formation; however, the mean amount of CIT in the 600-CN group was more than two other groups. It indicates that applying immediate orthodontic and orthopedic force after implant placement will not threaten implants' success rate. To actualize the idea of applying immediate static forces to dental implants in humans, it is necessary to conduct more studies and investigate criteria such as diameter and length of implants, rate of resistant force, and different periods of force application. Moreover, it is recommended to investigate the bone response to force application by means of fluorescent markers and microradiographs which are capable of detecting bone remodeling after different periods.

CONCLUSION

With limitations of this study, it can be concluded that immediate static loading with 300-CN and 600-CN might not interfere with the osseointegration procedure and might not decrease BIC and LB rates. The results of the study also demonstrated that it is possible to slightly move implants by applying static forces without tampering with osseointegration. However, more studies are suggested to provide more precise and determinant decision.

Financial support and sponsorship

Nil.

Conflicts of interest

There are no conflicts of interest.

REFERENCES

- Mankani N, Chowdhary R, Patil BA, Nagaraj E, Madalli P. Osseointegrated dental implants in growing children: A literature review. *J Oral Implantol* 2014;40:627-31.
- Iijima M, Nakagaki S, Yasuda Y, Handa K, Koike T, Muguruma T, *et al.* Effect of immediate loading on the biomechanical properties of bone surrounding the miniscrew implants. *Eur J Orthod* 2013;35:577-82.
- Ledermann PD, Schenk RK, Buser D. Long-lasting osseointegration of immediately loaded, bar-connected TPS screws after 12 years of function: A histologic case report of a 95-year-old patient. *Int J Periodontics Restorative Dent* 1998;18:552-63.
- Valderrama P, Bornstein MM, Jones AA, Wilson TG, Higginbottom FL, Cochran DL. Effects of implant design on marginal bone changes around early loaded, chemically modified, sandblasted acid-etched-surfaced implants: A histologic analysis in dogs. *J Periodontol* 2011;82:1025-34.
- Brånemark PI. Osseointegration and its experimental background. *J Prosthet Dent* 1983;50:399-410.
- Gapski R, Wang HL, Mascarenhas P, Lang NP. Critical review of immediate implant loading. *Clin Oral Implants Res* 2003;14:515-27.
- Meyer U, Wiesmann HP, Fillies T, Joos U. Early tissue reaction at the interface of immediately loaded dental implants. *Int J Oral Maxillofac Implants* 2003;18:489-99.
- Piattelli A, Corigliano M, Scarano A, Costigliola G, Paolantonio M. Immediate loading of titanium plasma-sprayed implants: An histologic analysis in monkeys. *J Periodontol* 1998;69:321-7.
- Zubery Y, Bichacho N, Moses O, Tal H. Immediate loading of modular transitional implants: A histologic and histomorphometric study in dogs. *Int J Periodontics Restorative Dent* 1999;19:343-53.
- Oyonarte R, Pilliar RM, Deporter D, Woodside DG. Peri-implant bone response to orthodontic loading: Part 1. A histomorphometric study of the effects of implant surface design. *Am J Orthod Dentofacial Orthop* 2005;128:173-81.
- Crismani AG, Bernhart T, Schwarz K, Celar AG, Bantleon HP, Watzek G. Ninety percent success in palatal implants loaded 1 week after placement: A clinical evaluation by resonance frequency analysis. *Clin Oral Implants Res* 2006;17:445-50.
- Turley PK, Kean C, Schur J, Stefanac J, Gray J, Hennes J, *et al.* Orthodontic force application to titanium endosseous implants. *Angle Orthod* 1988;58:151-62.
- Gedrange T, Bourauel C, Köbel C, Harzer W. Three-dimensional analysis of endosseous palatal implants and bones after vertical, horizontal, and diagonal force application. *Eur J Orthod* 2003;25:109-15.
- Oyonarte R, Pilliar RM, Deporter D, Woodside DG. Peri-implant bone response to orthodontic loading: Part 2. Implant surface geometry and its effect on regional bone remodeling. *Am J Orthod Dentofacial Orthop* 2005;128:182-9.
- Isidor F. Loss of osseointegration caused by occlusal load of oral implants. A clinical and radiographic study in monkeys. *Clin Oral Implants Res* 1996;7:143-52.
- Miyata T, Kobayashi Y, Araki H, Ohto T, Shin K. The influence of controlled occlusal overload on peri-implant tissue. Part 3: A histologic study in monkeys. *Int J Oral Maxillofac Implants* 2000;15:425-31.
- Melsen B, Costa A. Immediate loading of implants used for orthodontic anchorage. *Clin Orthod Res* 2000;3:23-8.
- Saito S, Sugimoto N, Morohashi T, Ozeki M, Kurabayashi H, Shimizu H, *et al.* Endosseous titanium implants as anchors for mesiodistal tooth movement in the beagle dog. *Am J Orthod Dentofacial Orthop* 2000;118:601-7.
- Wehrbein H, Glatzmaier J, Yildirim M. Orthodontic anchorage capacity of short titanium screw implants in the maxilla. An experimental study in the dog. *Clin Oral Implants Res* 1997;8:131-41.

20. Rismanchian M, Attar BM, Razavi SM, Shamsabad AN, Rezaei M. Dental implants immediate loading versus the standard 2-staged protocol: An experimental study in dogs. *J Oral Implantol* 2012;38:3-10.
21. Turner CH. Three rules for bone adaptation to mechanical stimuli. *Bone* 1998;23:399-407.
22. Degidi M, Scarano A, Piattelli M, Perrotti V, Piattelli A. Bone remodeling in immediately loaded and unloaded titanium dental implants: A histologic and histomorphometric study in humans. *J Oral Implantol* 2005;31:18-24.
23. Ghanavati F, Shayegh SS, Rahimi H, Sharifi D, Ghanavati F, Khalessheh N, *et al.* The effects of loading time on osseointegration and new bone formation around dental implants: A histologic and histomorphometric study in dogs. *J Periodontol* 2006;77:1701-7.
24. Rismanchian M, Bajoghli F, Gholamreza T, Razavi M. Dental implants: Early versus standard two-stage loading (animal study). *J Oral Implantol* 2014;40:84-93.
25. Chang HN, Garetto LP, Potter RH, Katona TR, Lee CH, Roberts WE. Angiogenesis and osteogenesis in an orthopedically expanded suture. *Am J Orthod Dentofacial Orthop* 1997;111:382-90.
26. Majzoub Z, Finotti M, Miotti F, Giardino R, Aldini NN, Cordioli G. Bone response to orthodontic loading of endosseous implants in the rabbit calvaria: Early continuous distalizing forces. *Eur J Orthod* 1999;21:223-30.