

## MAJOR PAPER

# Relationship between Contrast Enhancement of the Perivascular Space in the Basal Ganglia and Endolymphatic Volume Ratio

Toshio Ohashi<sup>1</sup>, Shinji Naganawa<sup>2\*</sup>, Toshio Katagiri<sup>1</sup>, and Kayao Kuno<sup>3</sup>

**Purpose:** We routinely obtain the endolymphatic hydrops (EH) image using heavily T<sub>2</sub>-weighted three dimensional-fluid attenuated inversion recovery (hT<sub>2</sub>w-3D-FLAIR) imaging at 4 hours after intravenous administration of a single-dose of gadolinium-based contrast media (IV-SD-GBCM). While repeating the examination, we speculated that the contrast enhancement of the perivascular space (PVS) in the basal ganglia might be related to the degree of EH. Therefore, the purpose of this study was to investigate the relationship between the endolymphatic volume ratio (%EL<sub>volume</sub>) and the signal intensity of the PVS (SI-PVS).

**Materials and Methods:** In 20 patients with a suspicion of EH, a heavily T<sub>2</sub>-weighted 3D-turbo spin echo sequence for MR cisternography (MRC) and an hT<sub>2</sub>w-3D-FLAIR as a positive perilymph image (PPI) were obtained at 4 hours after IV-SD-GBCM. The %EL<sub>volume</sub> of the cochlea and the vestibule were measured on the previously reported HYDROPS2-Mi2 image. The PVS in the basal ganglia was segmented on MRC using a region-growing method. The PVS regions were copied and pasted onto the PPI, and the SI-PVS was measured. The larger value of the right and the left ears was employed as the %EL<sub>volume</sub>, and the weighted average of both sides was employed as the SI-PVS. The correlation between the %EL<sub>volume</sub> and the SI-PVS was evaluated.

**Result:** There was a strong negative linear correlation between the %EL<sub>volume</sub> of the cochlea and the SI-PVS ( $r = -0.743$ ,  $P < 0.001$ ); however, there was no significant correlation between the %EL<sub>volume</sub> of the vestibule and the SI-PVS ( $r = -0.267$ ,  $P = 0.256$ ).

**Conclusion:** There was a strong negative correlation between the cochlear %EL<sub>volume</sub> and the SI-PVS. Contrast enhancement of PVS might be a biomarker of EH.

**Key words:** magnetic resonance imaging, perivascular space, endolymphatic hydrops, glymphatic system

## Introduction

T<sub>2</sub>-weighted three dimensional-fluid attenuated inversion recovery (T<sub>2</sub>w-3D-FLAIR) imaging has high sensitivity to low concentrations of gadolinium compared with conventional T<sub>1</sub>-weighted imaging.<sup>1</sup> Additionally, heavily T<sub>2</sub>w-3D-FLAIR (hT<sub>2</sub>w-3D-FLAIR) imaging is more sensitive to

diluted gadolinium in fluid than conventional 3D-FLAIR.<sup>2,3</sup> Utilizing these characteristics, the method to visualize endolymphatic hydrops (EH) was developed.<sup>4</sup> Because only a single dose of gadolinium-based contrast media (GBCM) is required, the method has undergone rapid and widespread clinical application.<sup>5</sup>

In addition, a recent study using hT<sub>2</sub>w-3D-FLAIR imaging confirmed that the perivascular space (PVS) in the basal ganglia is enhanced 4 hours after intravenous administration of a single-dose of GBCM (IV-SD-GBCM) on hT<sub>2</sub>w-3D-FLAIR imaging in human subjects without renal insufficiency.<sup>6</sup> In our hospital, we routinely obtain the EH image at 4 hours after IV-SD-GBCM, and measure the volume of the endolymphatic space quantitatively in accordance with our previously reported study.<sup>7-9</sup> While repeating the evaluation for EH, we noticed that the signal intensity of the PVS (SI-PVS) showed various values on the hT<sub>2</sub>w-3D-FLAIR image at 4 hours after IV-SD-GBCM, and

<sup>1</sup>Department of Radiology, Kamiida Daiichi General Hospital, Aichi, Japan

<sup>2</sup>Department of Radiology, Nagoya University Graduate School of Medicine, 65 Tsurumai-cho, Showa-ku, Nagoya, Aichi 466-8550, Japan

<sup>3</sup>Department of Otorhinolaryngology, Kamiida Daiichi General Hospital, Aichi, Japan

\*Corresponding author, Phone: +81-52-744-2327, Fax: +81-52-744-2335, E-mail: naganawa@med.nagoya-u.ac.jp

©2017 Japanese Society for Magnetic Resonance in Medicine

This work is licensed under a Creative Commons Attribution-NonCommercial-NoDerivatives International License.

Received: January 10, 2017 | Accepted: May 10, 2017

hypothesized that the variation in the SI-PVS might be related to the degree of EH. A fluid pathway in the brain that is similar to the lymphatic system in the body, termed the “glymphatic” system, has been proposed.<sup>10</sup> PVS is the entry site of the glymphatic system.<sup>10</sup> Fluid and solute homeostasis in the brain are maintained due to this glymphatic system, and the PVS is the key organ to maintain the process. Previous study referred to the potential relationship between contrast enhancement of PVS and the glymphatic system.<sup>6</sup> Therefore, it has a clinical significance to assess the relationship between the SI-PVS and the degree of EH. However, this relationship has not been reported previously. The purpose of this study was to investigate the relationship between the volume of the endolymphatic space and the SI-PVS.

## Materials and Methods

### Patients and MR imaging

Twenty patients (5 men, 15 women; aged 41 to 80 years, median 64) who underwent MR examination from April 1, 2013 through January 31, 2014 to assess clinically suspected EH were enrolled. The diagnosis of Meniere’s disease (MD) was based on the guidelines of the American Academy of Ophthalmology and Otolaryngology-Head and Neck Surgery (AAO-HNS). Table 1 details the patient characteristics.

All images were obtained on a 3T MR scanner (MAGNETOM Skyra, Siemens Healthcare, Erlangen, Germany) using a 32 channel-phased array head coil.

MR scanning was performed at 4 hours after IV-SD-GBCM (0.2 ml/kg body weight or 0.1 mmol/kg body weight) of gadoteridol (Gd-HP-DO3A; ProHance, Eisai, Tokyo, Japan) to evaluate the degree of EH. The estimated glomerular filtration rate (eGFR) of all patients exceeded 60 ml/min/1.73 m<sup>2</sup>. According to the previously reported protocol used for the evaluation of EH in our institution,<sup>8</sup> the patients underwent a heavily T<sub>2</sub>-weighted 3D-turbo spin echo

**Table 1.** Patient characteristics

Characteristics (n = 20)		Value
Age (year)	Median	64
	Range	41–80
Sex	Male	5
	Female	15
Grading of endolymphatic hydrops (n = 40)		
Cochlea	No hydrops	16
	Mild	14
	Significant	10
Vestibule	No hydrops	21
	Mild	11
	Significant	8

Grading of endolymphatic hydrops is based on Nakashima T, et al.<sup>7</sup>

**Table 2.** Pulse sequence parameters

Parameter	MR cisternography (MRC)	Heavily T <sub>2</sub> -weighted 3D-FLAIR (PPI)
Sequence type	SPACE with restore pulse	SPACE with inversion pulse
Repetition time (ms)	4400	9000
Echo time (ms)	544	544
Inversion time (ms)	NA	2250
Fat suppression	CHESS	CHESS
Flip angle (degree)	90/initial 180 decrease to constant 120	90/initial 180 decrease to constant 120
Section thickness/gap (mm)	1.0/0.0	1.0/0.0
Pixel size (mm)	0.5 × 0.5	0.5 × 0.5
Number of slices	104	104
Echo train length	173	173
Field of view (mm)	165 × 196	165 × 196
Matrix size	324 × 384	324 × 384
Parallel imaging/acceel. Factor	GRAPPA/2	GRAPPA/2
Band width (Hz/Px)	434	434
Number of excitations	1.8	4
Scan time (min)	3.4	15.2

PPI, positive perilymph image; SPACE, sampling perfection with application-optimized contrasts using different flip angle evolutions; NA, not applicable; CHESS, chemical shift selective; GRAPPA, generalized auto-calibrating partially parallel acquisition.

sequence for MR cisternography (MRC) and hT<sub>2</sub>w-3D-FLAIR imaging with a 2250 msec inversion time for the positive perilymph image (PPI). The slice thickness, field of view, resolution and slice position were aligned in both images. The voxel size was 0.5 × 0.5 × 1.0 mm<sup>3</sup>. The slice was set parallel to the anterior commissure (AC)-posterior commissure (PC) line in the axial section. The details of the scan parameters are listed in Table 2. The medical ethics committee of our hospital approved this retrospective study and waived informed consent.

### Volume and SI measurement

The following method for volume quantification is identical to our previously reported method.<sup>8,9</sup> The HYbrid of Reversed image Of MR cisternography and positive Perilymph Signal by heavily T<sub>2</sub>-weighted 3D-FLAIR-Multiplied with heavily T<sub>2</sub>-weighted MR cisternography (HYDROPS2-Mi2) images were generated as follows: HYDROPS2-Mi2 = (PPI – 0.04 × MRC) × MRC.

Two radiological technologists with 14 years and 7 years of experience in MR imaging manually drew the ROI along the boundary of the cochlea and the vestibule on all

slices of the MRC. The ROIs from the MRC were copied and pasted onto the HYDROPS2-Mi2 image (Fig. 1). Regarding all voxels within the ROIs as total lymph and voxels with a negative value within the ROIs as endolymph, we counted the number of total lymph and endolymph voxels on all slices of HYDROPS2-Mi2 image and measured the percentage of the volume of endolymphatic space in the total lymphatic space (the endolymphatic volume ratio [%EL<sub>volume</sub>]) of the cochlea and the vestibule on HYDROPS2-Mi2 image. The %EL<sub>volume</sub> was defined as: %EL<sub>volume</sub> = (sum of the number of negative voxels for the endolymph in the ROIs of all slices divided by the total number of voxels in the ROIs of all slices) × 100. A free DICOM viewer (OsiriX image software, version 5.8 32bit; downloadable at <http://www.osirix-viewer.com/>) was used for generating HYDROPS2-Mi2 image and counting the number of voxels.<sup>9</sup>

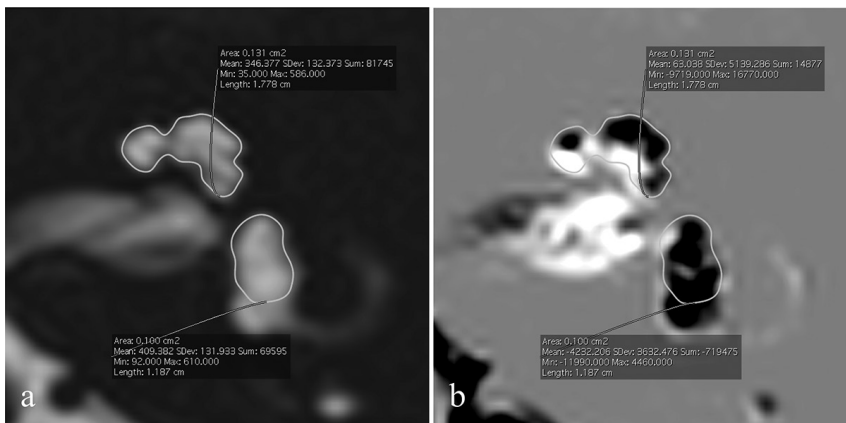
Thereafter, the volume of PVS (Vol-PVS) and the SI-PVS were measured. The PVS in the basal ganglia was segmented using the region-growing method from the OsiriX functions. The initial seed points were placed in the PVS of the bilateral basal ganglia in the middle slice of the MRC that contained both the AC and the PC. The PVS connecting to the initial regions was segmented in succession toward the cranial and caudal slices (typically 7–9 slices), and the Vol-PVS was

measured. Then, the rest of the PVS that was not connected to the initial region was ignored. The initial seed points were placed in all PVS where the size was greater than 1 mm<sup>2</sup>. The threshold of the SI was set to full width at half maximum of the fully fluid containing voxels. The PVS regions on the MRC were copied and pasted onto the PPI and the SI-PVS was measured (Fig. 2). Although we did not obtain pre-contrast images, according to the previous studies including pre-contrast measurements,<sup>6,11</sup> we considered that the pre-contrast PVS had very little SI on hT<sub>2</sub>w-3D-FLAIR images.

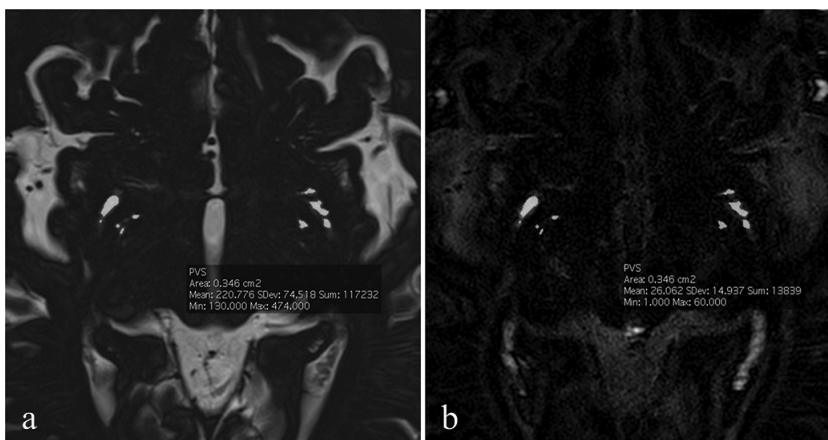
And then, we measured the signal intensity of ambient cistern (SI-Amb). The circular ROIs of 3 mm diameter were set within the bilateral ambient cistern excluding the posterior cerebral artery on the MRC. The ROIs on the MRC were copied and pasted onto the PPI and the SI-Amb was measured.

### Statistical analyses

The larger value of the right and the left ears was employed as the %EL<sub>volume</sub>, and the weighted average of both sides was employed as the SI-PVS. The intra-class correlation coefficient between the measurements by the two observers was obtained for the %EL<sub>volume</sub> of the cochlea, the %EL<sub>volume</sub> of the vestibule, the Vol-PVS, the SI-PVS, and the SI-Amb. We employed the mean of the two observers for all measurements. The correlations between the cochlear or the



**Fig. 1** An example of the ROI for volume measurements. The ROI was drawn along the boundary of the cochlea and the vestibule manually on magnetic resonance cisternography (MRC) (a). The ROI was copied and pasted onto the HYbrid of Reversed image Of MR cisternography and positive Perilymph Signal by heavily T<sub>2</sub>-weighted 3D-FLAIR-Multiplied with heavily T<sub>2</sub>-weighted MR cisternography (HYDROPS2-Mi2) (b).



**Fig. 2** An example of the ROI placement for the signal intensity measurement. The ROI of the perivascular space in the basal ganglia was segmented using a region-growing method on magnetic resonance cisternography (MRC) (a). The ROI was copied and pasted onto the positive perilymph image (PPI) (b).

vestibular %EL<sub>volume</sub> and the SI-PVS were evaluated by a Pearson correlation coefficient. The correlations between the Vol-PVS or the SI-Amb and SI-PVS were evaluated by a Pearson correlation coefficient. A linear regression line was calculated by simple regression analysis. R software (version 3.3.2, downloadable at <https://www.R-project.org/>) was used for the statistical analyses.

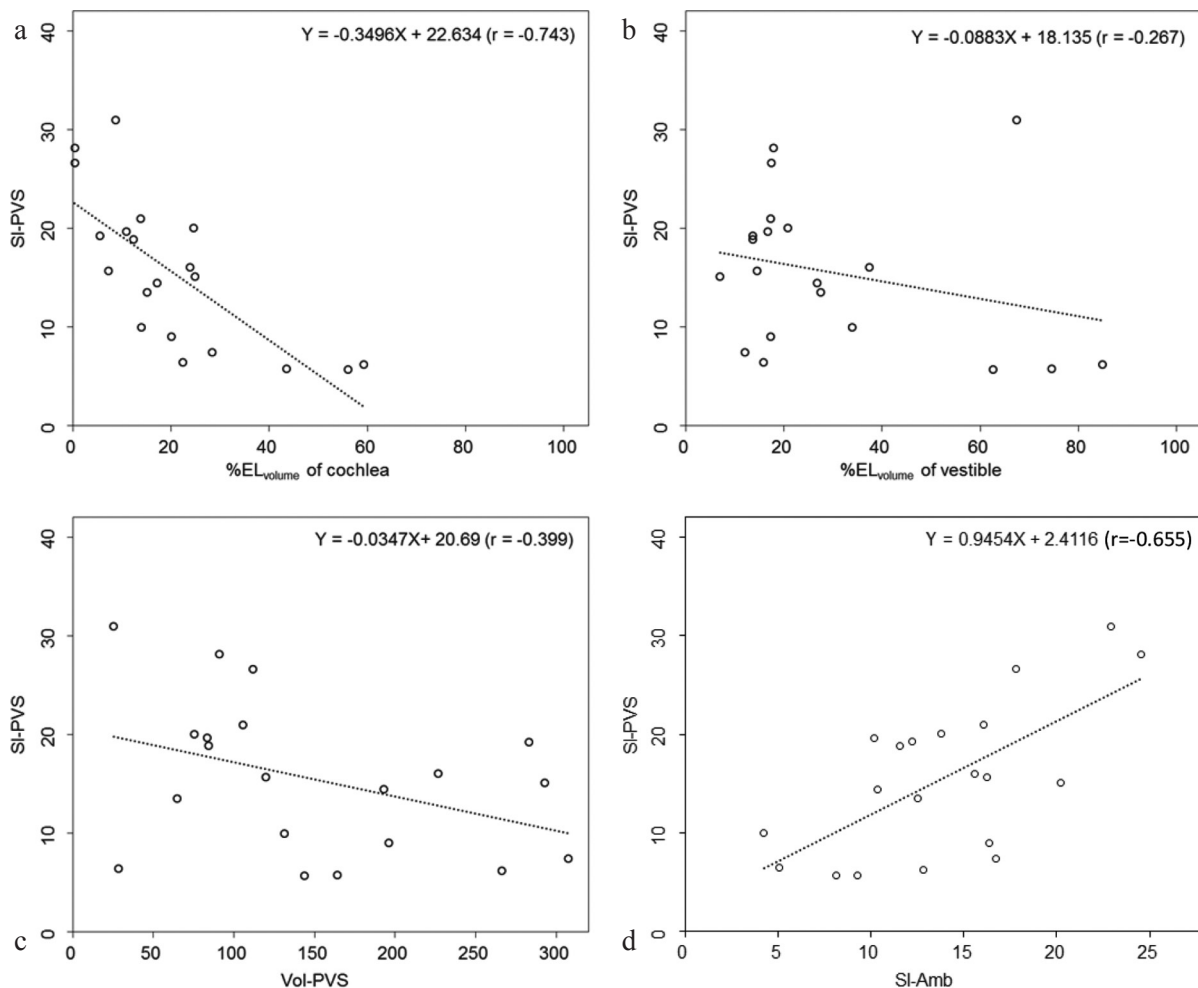
## Results

The intra-class correlation coefficient between the measurements by the two observers was 0.996 for the %EL<sub>volume</sub> of the cochlea, 0.989 for the %EL<sub>volume</sub> of the vestibule, 0.994 for the Vol-PVS, 0.998 for the SI-PVS, 0.982 for the SI-Amb. Figure 3a shows the relationship between the %EL<sub>volume</sub> of the cochlea and the SI-PVS. There was a strong negative linear correlation between the measurements. The Pearson correlation coefficient ( $r$ ) was  $-0.743$  ( $P < 0.001$ ). Figure 3b shows the relationship between the %EL<sub>volume</sub> of the vestibule and the SI-PVS. There was no significant correlation

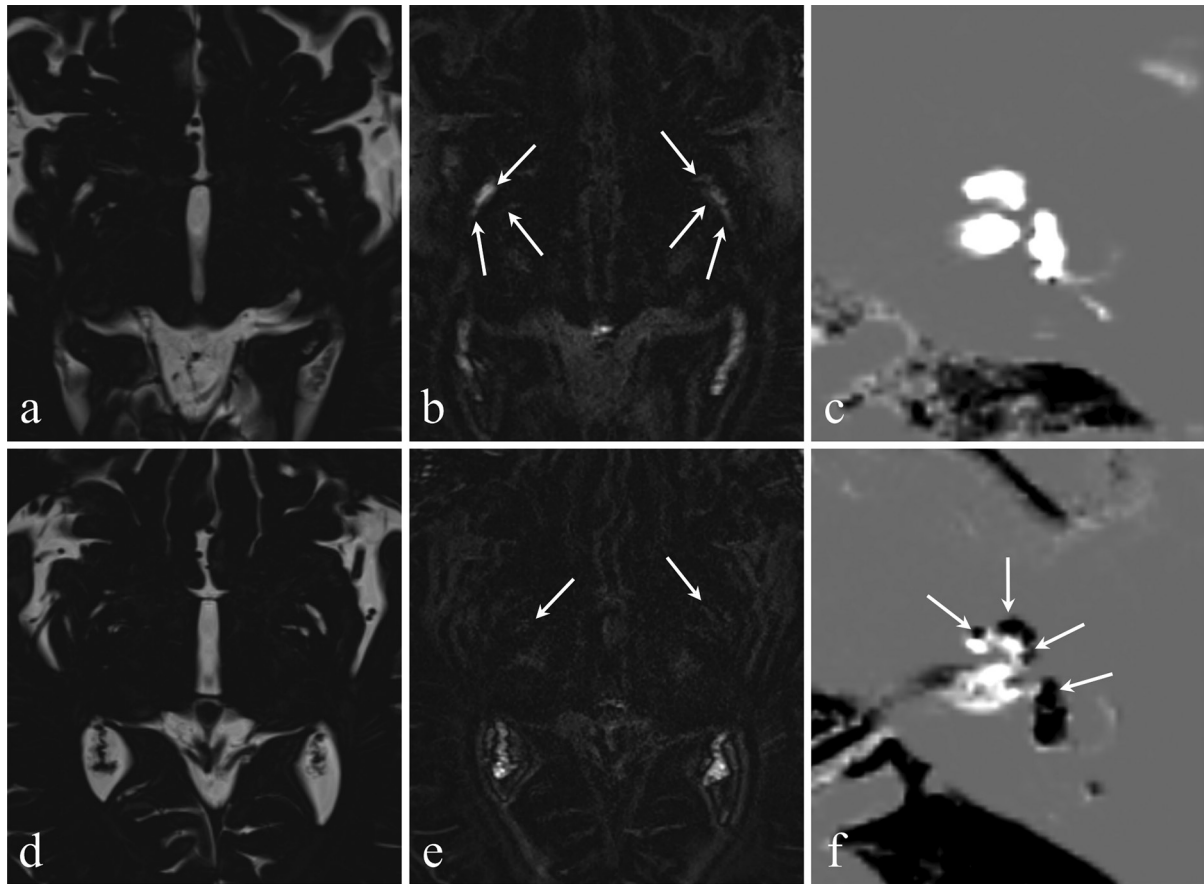
between the measurements. The Pearson correlation coefficient ( $r$ ) was  $-0.267$  ( $P = 0.256$ ). Figure 3c shows the relationship between the Vol-PVS and the SI-PVS. There was no significant correlation between the measurements. The Pearson correlation coefficient ( $r$ ) was  $-0.399$  ( $P = 0.081$ ). Figure 3d shows the relationship between the SI-Amb and the SI-PVS. There was a positive linear correlation between the measurements. The Pearson correlation coefficient ( $r$ ) was  $-0.655$  ( $P = 0.002$ ). Representative images obtained in this study are shown in Fig. 4.

## Discussion

It has been reported that enhancement of the PVS by GBM was observed on hT<sub>2</sub>w-3D-FLAIR images and this might reflect glymphatic function.<sup>6</sup> In other words, it is reasonable that the SI-PVS on post contrast images might depend on whether the glymphatic system functions normally or not. In this study, there was a positive linear correlation between the SI-PVS and the SI-Amb. These results might



**Fig. 3** Scattergrams of the signal intensity of the perivascular space (SI-PVS) and the percentage of the volume of the endolymphatic space in the total lymphatic space (the endolymphatic volume ratio [%EL<sub>volume</sub>]) of the cochlea (a), the vestibule (b), the volume of the perivascular space (Vol-PVS) (c), and the signal intensity of the ambient cistern (SI-Amb) (d).



**Fig. 4** Representative images: a 70-year-old woman with no endolymphatic hydrops (EH) (a–c) and a 59-year-old man with significant EH (d–f). On magnetic resonance cisternography (MRC), the perivascular space (PVS) is recognized well in both patients (a, d). On the positive perilymph image (PPI), the signal of the PVS in the patient with no EH indicates a higher signal intensity than the patient with significant EH (arrows) (b, e). On HYDROPS2-Mi2 (HYbrid of Reversed image Of MR cisternography and positive Perilymph Signal by heavily T<sub>2</sub>-weighted 3D-FLAIR-Multiplied with heavily T<sub>2</sub>-weighted MR cisternography), the EH is clearly indicated as a black area (arrows) (f).

indicate the connection of cerebrospinal fluid (CSF) and PVS as proposed for the glymphatic system.<sup>10</sup> Furthermore, previous evidence suggests the hypothesis that the development of EH is caused by a disorder of this fluid regulation system produced by water metabolism-related molecules such as vasopressin or aquaporin-2.<sup>12</sup> In this study, the SI-PVS indicated a strong negative linear correlation to the cochlear %EL<sub>volume</sub>. There might be a co-factor involved in fluid homeostasis between the development of EH and glymphatic dysfunction. However, the correlation to the SI-PVS observed in the cochlea was not found in the vestibule in this study. A previous report has suggested that in the early stages of MD, EH tends to occur, at first, in the unilateral cochlea.<sup>13</sup> The SI-PVS might respond to initial MD pathology more sensitively.

On the other hand, dysfunction of the glymphatic pathway promotes deposition of neurotoxic solutes including amyloid  $\beta$  (A $\beta$ ) and then causes neurodegenerative disease.<sup>10</sup> This speculation extends widely over a variety of illnesses such as Alzheimer's disease and glaucoma. This accumulation of A $\beta$  is thought to behave as a risk factor for

Alzheimer's disease.<sup>14</sup> Although high intraocular pressure is a major risk factor for glaucoma, elevated tension is not present in all glaucoma cases, therefore, the neurodegenerative process in glaucoma that is considered as a link with Alzheimer's disease is expected as one risk factor.<sup>15,16</sup> Nakashima et al. proposed that glaucoma, hydrocephalus and MD may be related to each other with regard to CSF and extracellular fluid regulation.<sup>17</sup> A $\beta$  and GBCM might show different clearance in the brain, however the importance of this glymphatic system warrants the further research using GBCM.

Endolymphatic hydrops has been recognized as the pathology of MD since the finding of EH in human temporal bones.<sup>18,19</sup> Furthermore, the existence of EH was confirmed in all living patients with definite MD by an MR imaging study.<sup>20</sup> However, EH may exist not only in the symptomatic ipsilateral ear, but also in the asymptomatic contralateral or bilateral ear.<sup>5</sup> Moreover, in an animal study, which artificially induced acute EH in the cochlea, the influence of simple EH on cochlear dysfunction was minimal or restrictive.<sup>21</sup> Therefore, EH might not be a direct or major factor of MD. The present study confirmed that there is a correlation between

the degree of EH and the SI-PVS. This result might be an indirect clue to the relationship between MD and lymphatic function. A further study correlating the EH volume, the patients' symptoms, the functional prognosis and the SI-PVS is warranted to better understand the pathophysiology of MD with respect to the lymphatic system. This study has a limitation. Only a small number of patients were evaluated in this retrospective study.

## Conclusion

There was a strong negative linear correlation between the %EL<sub>volume</sub> of the cochlea and the SI-PVS. Therefore, contrast enhancement of the PVS might be a new biomarker to assess EH.

## Conflicts of Interest

All authors do not have any conflicts of interest regarding this study.

## References

1. Fukuoka H, Hirai T, Okuda T, et al. Comparison of the added value of contrast-enhanced 3D fluid-attenuated inversion recovery and magnetization-prepared rapid acquisition of gradient echo sequences in relation to conventional postcontrast T<sub>1</sub>-weighted images for the evaluation of leptomeningeal diseases at 3T. *AJNR Am J Neuroradiol* 2010; 31:868–873.
2. Naganawa S, Kawai H, Sone M, Nakashima T. Increased sensitivity to low concentration gadolinium contrast by optimized heavily T<sub>2</sub>-weighted 3D-FLAIR to visualize endolymphatic space. *Magn Reson Med Sci* 2010; 9: 73–80.
3. Naganawa S. The technical and clinical features of 3D-FLAIR in neuroimaging. *Magn Reson Med Sci* 2015; 14:93–106.
4. Naganawa S, Yamazaki M, Kawai H, Bokura K, Sone M, Nakashima T. Visualization of endolymphatic hydrops in Ménière's disease with single-dose intravenous gadolinium-based contrast media using heavily T<sub>2</sub>-weighted 3D-FLAIR. *Magn Reson Med Sci* 2010; 9:237–242.
5. Nakashima T, Pyykkö I, Arroll MA, et al. Meniere's disease. *Nat Rev Dis Primers* 2016; 2:16028. doi: 10.1038/nrdp.2016.28.
6. Naganawa S, Nakane T, Kawai H, Taoka T. Gd-based contrast enhancement of the perivascular spaces in the basal ganglia. *Magn Reson Med Sci* 2017; 16:61–65.
7. Nakashima T, Naganawa S, Pyykkö I, et al. Grading of endolymphatic hydrops using magnetic resonance imaging. *Acta Otolaryngol Suppl* 2009; 560:5–8.
8. Naganawa S, Nakashima T. Visualization of endolymphatic hydrops with MR imaging in patients with Ménière's disease and related pathologies: current status of its methods and clinical significance. *Jpn J Radiol* 2014; 32:191–204.
9. Naganawa S, Ohashi T, Kanou M, Kuno K, Sone M, Ikeda M. Volume quantification of endolymph after intravenous administration of a single dose of gadolinium contrast agent: comparison of 18- versus 8-minute imaging protocols. *Magn Reson Med Sci* 2015; 14:257–262.
10. Iliff JJ, Wang M, Liao Y, et al. A paravascular pathway facilitates CSF flow through the brain parenchyma and the clearance of interstitial solutes, including amyloid  $\beta$ . *Sci Transl Med* 2012; 4:147ra111.
11. Naganawa S, Suzuki K, Yamazaki M, Sakurai Y. Serial scans in healthy volunteers following intravenous administration of gadoteridol: time course of contrast enhancement in various cranial fluid spaces. *Magn Reson Med Sci* 2014; 13:7–13.
12. Sawada S, Takeda T, Kitano H, Takeuchi S, Kakigi A, Azuma H. Aquaporin-2 regulation by vasopressin in the rat inner ear. *Neuroreport* 2002; 13:1127–1129.
13. Gibson WP. Hypothetical mechanism for vertigo in Meniere's disease. *Otolaryngol Clin North Am* 2010; 43:1019–1027.
14. Weller RO, Subash M, Preston SD, Mazanti I, Carare RO. Perivascular drainage of amyloid-beta peptides from the brain and its failure in cerebral amyloid angiopathy and Alzheimer's disease. *Brain Pathol* 2008; 18:253–266.
15. Wostyn P, Van Dam D, Audenaert K, Killer HE, De Deyn PP, De Groot V. A new glaucoma hypothesis: a role of lymphatic system dysfunction. *Fluids Barriers CNS* 2015; 12:16. doi: 10.1186/s12987-015-0012-z.
16. Wostyn P, De Groot V, Van Dam D, Audenaert K, Killer HE, De Deyn PP. Alzheimer's disease and glaucoma: can lymphatic system dysfunction underlie their comorbidity? *Acta Ophthalmol* 2017; 95:e244–e245.
17. Nakashima T, Sone M, Teranishi M, et al. A perspective from magnetic resonance imaging findings of the inner ear: relationships among cerebrospinal, ocular and inner ear fluids. *Auris Nasus Larynx* 2012; 39:345–355.
18. Hallpike CS, Cairns H. Observations on the pathology of Ménière's syndrome: (section of otology). *Proc R Soc Med* 1938; 31:1317–1336.
19. Yamakawa K. Über die pathologische Veränderung bei einem Menière-Kranken. *Proceedings of 42<sup>nd</sup> annual meeting of Oto-Rhino-Laryngol Soc Japan*. *J Otolaryngol Soc Jpn* 1938; 44:2310–2312.
20. Nakashima T, Naganawa S, Teranishi M, et al. Endolymphatic hydrops revealed by intravenous gadolinium injection in patients with Ménière's disease. *Acta Otolaryngol* 2010; 130:338–343.
21. Valk WL, Wit HP, Albers FW. Evaluation of cochlear function in an acute endolymphatic hydrops model in the guinea pig by measuring low-level DPOAEs. *Hear Res* 2004; 192: 47–56.