

A rare cause of pulmonary hemorrhage in an infant

Sir,

Pulmonary hemorrhage in children is rare and possibly a life-threatening event that should be evaluated. The usual causes for pulmonary hemorrhage in children include infections, cystic fibrosis, bronchiectasis, foreign bodies, trauma, immunologic disease, neoplasms, pulmonary hemosiderosis, and congenital cardiovascular lesions.^[1] Acute idiopathic pulmonary hemorrhage (AIPH) is a rare cause of pulmonary hemorrhage, and we report a case of a 2-month-old infant with acute onset of pulmonary hemorrhage.

The 2-month-old exclusively breast-fed female infant presented with a history of poor feeding, fast breathing and bleeding from nose and mouth for few hours with no history of fever, cough, rash, or drug intake. She was born at term by normal vaginal delivery, (birth weight 2.5 kg) with no neonatal complications. The infant's grandfather was a smoker. The family had no history of bleeding, rheumatologic disorders, or exposure to pesticides. Their house was cemented with no water leakage or growth of molds.

The physical examination revealed a restless infant who was in severe respiratory distress with grunting respiration, tachycardia, and oozing of blood from the nostrils. Oxygen saturation was 60% in room air and crackles were auscultated in both the lung fields. She was intubated immediately and fresh blood was noted in the trachea. She was ventilated with 100% oxygen at a high pressure setting. Intravenous antibiotics were started. Arterial blood gas (ABG) analysis after intubation showed respiratory acidosis with pH 7.26, pCO₂ 51 mmHg, bicarbonate 22 mmol/L. Initial investigations showed hemoglobin level 102 g/L; total leucocyte count 31.5×10^9 cells/L with neutrophils 58%, lymphocytes 35%, platelet count 756×10^9 cells/L. C-reactive protein, liver function, serum creatinine, coagulation profile and urine examination were within normal limits. Chest x-ray (CXR) showed diffuse air space opacities in both lung fields [Figure 1a]. Echocardiogram showed mild pulmonary arterial hypertension with patent foramen ovale. Computed tomography (CT) of the chest with contrast showed air space opacities predominantly in the lower lobes bilaterally [Figure 2]. A provisional diagnosis of diffuse alveolar hemorrhage was made and intravenous Methylprednisolone was started. Grave prognosis was explained to the parents in view of continuous bleeding from the endotracheal tube. Twelve hours after admission, she required

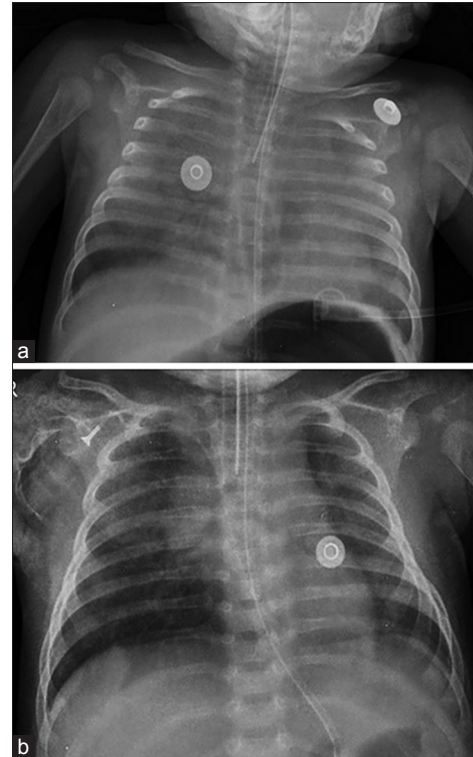


Figure 1: (a) Diffuse air space opacities in both lung fields (b) Repeat X-ray showing marked clearing of infiltrates

packed red cells transfusion as the Hemoglobin level dropped to 64 g/L. The condition of the baby improved rapidly thereafter, and she was extubated after 66 h of hospitalization. Repeat CXR showed marked clearing of infiltrates in the lung fields [Figure 1b], and hematocrit remained stable.

Cultures of blood and endotracheal aspirates did not show growth of any organism. C3 and C4 levels; serum ammonia; antinuclear antibody (ANA); antiglomerular basement membrane (anti-GBM) antibody; rheumatoid (RA) factor; cytoplasmic antineutrophil cytoplasmic antibody (c-ANCA); perinuclear antineutrophil cytoplasmic antibody (p-ANCA); cow's milk protein-specific immunoglobulin E (IgE); selective immunoglobulin M (S IgM) by immunofluorescent assay for Legionella, Mycoplasma, Coxiella, Chlamydia, Adenovirus, respiratory syncytial virus, influenza virus (A and B), parainfluenza virus (1, 2, and 3) were all negative. Gastric aspirate for hemosiderophages on day 13 and 14 of illness was negative. Repeat echocardiogram showed complete resolution of pulmonary arterial hypertension.

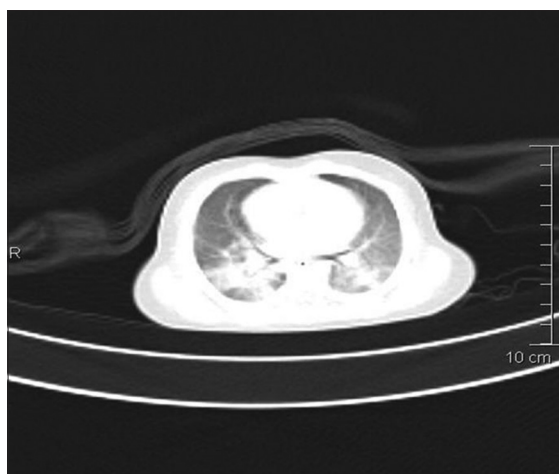


Figure 2: Computed tomography chest showing diffuse airspace opacities predominantly in the lower lobes bilaterally

The patient was discharged on Prednisolone at 0.5 mg/kg that was tapered and stopped over 3 months. She is well on follow-up at 4 months.

AIPH is a diagnosis of exclusion and is a distinct entity classified under diffuse alveolar hemorrhage syndromes without pulmonary capillaritis. The initial cases were reported in 37 infants from Cleveland.^[2] Dearborn *et al.* investigated these cases and reported an association of pulmonary hemorrhage with home water damage and presence of a toxigenic fungus *Stachybotrys chartarum* in indoor air.^[3] They postulated that rapidly growing lungs of infants are vulnerable to potent mycotoxins produced by fungal spores. Other risk factors described were male sex, absence of breast feeding, and exposure to tobacco smoke. However, in a review by the Centers for Disease Control and Prevention (CDC) in 2004, the shortcomings in the Cleveland study were identified and these associations were overruled.^[4] The CDC recommended surveillance and investigation of all cases of AIPH, and defined a “clinically confirmed” case of AIPH as sudden onset of pulmonary hemorrhage in a previously healthy infant aged <1 year with a gestational age >32 weeks in whom differential diagnosis and neonatal medical problems have been ruled out and whose condition meets the following three criteria:^[5]

- Abrupt or sudden onset of overt bleeding or obvious evidence of blood in the airway
- Severe appearing illness leading to acute respiratory distress or failure, resulting in hospitalization in a pediatric/neonatal intensive care unit with intubation and mechanical ventilation
- Diffuse unilateral or bilateral pulmonary infiltrates visible on CXR or CT of the chest with findings documented within 48 h of examination of the infant.

This infant meets these criteria for a clinically confirmed case of AIPH. The management of this disease includes prompt respiratory and hemodynamic support with systemic corticosteroids. Close follow-up and surveillance as recommended by the CDC may help determine the elusive cause of AIPH.

Financial support and sponsorship

Nil.

Conflicts of interest

There are no conflicts of interest.

**KS Lakshmi, Rachel R Peterson,
Prashant K Saranadagouda, Asha Kuruvilla¹**

Departments of Pediatrics and ¹Radiology, Bangalore Baptist Hospital, Bangalore, Karnataka, India
E-mail: lakshmiksdr@gmail.com

REFERENCES

1. Susarla SC, Fan LL. Diffuse alveolar hemorrhage syndromes in children. *Curr Opin Pediatr* 2007;19:314-20.
2. Centers for Disease Control and Prevention (CDC). Acute pulmonary hemorrhage/hemosiderosis among infants—Cleveland, January 1993–November 1994. *MMWR Morb Mortal Wkly Rep* 1994;43:881-3.
3. Dearborn DG, Yike I, Sorenson WG, Miller MJ, Etzel RA. Overview of investigations into pulmonary hemorrhage among infants in Cleveland, Ohio. *Environ Health Perspect* 1999;107(Suppl 3):495-9.
4. Centers for Disease Control and Prevention (CDC). Update: Pulmonary hemorrhage/hemosiderosis among infants—Cleveland, Ohio, 1993–1996. *MMWR Morb Mortal Wkly Rep* 2000;49:180-4.
5. Brown CM, Redd SC, Damon SA; Centers for Disease Control and Prevention (CDC). Acute idiopathic pulmonary hemorrhage among infants. Recommendations from the working group for investigation and surveillance. *MMWR Recomm Rep* 2004;53:1-12.

This is an open access article distributed under the terms of the Creative Commons Attribution-NonCommercial-ShareAlike 3.0 License, which allows others to remix, tweak, and build upon the work non-commercially, as long as the author is credited and the new creations are licensed under the identical terms.

Access this article online	
Quick Response Code: 	Website: www.lungindia.com
	DOI: 10.4103/0970-2113.177450

How to cite this article: Lakshmi KS, Peterson RR, Saranadagouda PK, Kuruvilla A. A rare cause of pulmonary hemorrhage in an infant. *Lung India* 2016;33:242-3.