

HOSTED BY



ELSEVIER

Available online at www.sciencedirect.com

ScienceDirect

journal homepage: www.elsevier.com/locate/IPEJ

Delayed AICD therapy and cardiac arrest resulting from undersensing of ventricular fibrillation in a subject with hypertrophic cardiomyopathy—A case report

Ashley Chin^a, Jeffrey S. Healey^b, Carlos S. Ribas^b, Girish M. Nair^{c,*}

^a Cardiac Clinic, E-17, Groote Schuur Hospital, Department of Medicine, University of Cape Town, Cape Town, South Africa

^b Arrhythmia Service, Division of Cardiology, McMaster University and Hamilton Health Sciences, 237 Barton St. East, Hamilton, Ontario L8L 2X2, Canada

^c Arrhythmia Service, Division of Cardiology, University of Ottawa Heart Institute, 40 Ruskin Ave, Ottawa, Ontario K1Y 4W7, Canada

ARTICLE INFO

Article history:

Available online 29 July 2015

Keywords:

Hypertrophic cardiomyopathy
Automatic implantable cardioverter defibrillator
Undersensing of ventricular fibrillation
Cardiac arrest

ABSTRACT

Defibrillation testing is no longer routinely performed after automatic implantable cardioverter-defibrillator (AICD) implantation. However, certain subjects undergoing AICD implantation may be at higher risk of undersensing of ventricular arrhythmias resulting in potentially fatal outcomes. We present the case of a 30-year-old woman with hypertrophic cardiomyopathy (HCM; 'asymmetric septal hypertrophy' morphologic variant) and prophylactic AICD who experienced an out of hospital cardiac arrest. AICD interrogation revealed undersensing as a result of intermittent high amplitude electrograms during an episode of ventricular fibrillation (VF). The subject underwent replacement and repositioning of the AICD lead along with pulse generator replacement (that utilized a different VF sensing algorithm) with appropriate sensing of VF and successful defibrillation testing. The presence of intermittent high amplitude electrograms during episodes of VF in AICDs using the AGC function should be recognized as a situation that may necessitate interventions to prevent undersensing and consequent delay in therapy.

Copyright © 2015, Indian Heart Rhythm Society. Production and hosting by Elsevier B.V. This is an open access article under the CC BY-NC-ND license (<http://creativecommons.org/licenses/by-nc-nd/4.0/>).

Case report

A 30-year-old woman with non-obstructive hypertrophic cardiomyopathy (HCM; 'asymmetric septal hypertrophy'

morphologic variant) received a dual-chamber automatic implantable cardioverter defibrillator (AICD; Boston Scientific Teligen 100) for prevention of sudden cardiac death. She was diagnosed during family screening after her father had been diagnosed with HCM following a ventricular fibrillation (VF)

* Corresponding author. H-1285 B, University of Ottawa Heart Institute, 40 Ruskin Ave, Ottawa K1Y 4W7, Canada. Tel.: +1 613 761 4820. E-mail address: gnair@ottawaheart.ca (G.M. Nair).

Peer review under responsibility of Indian Heart Rhythm Society.

<http://dx.doi.org/10.1016/j.ipej.2015.07.009>

0972-6292/Copyright © 2015, Indian Heart Rhythm Society. Production and hosting by Elsevier B.V. This is an open access article under the CC BY-NC-ND license (<http://creativecommons.org/licenses/by-nc-nd/4.0/>).

cardiac arrest. At implant the AICD lead tip was positioned in the right ventricular (RV) apex and the AICD was programmed with 2 treatment zones: ventricular tachycardia (VT) zone: 188 to 240 bpm (3 bursts of anti-tachycardia pacing (ATP), followed by 41 J shocks), VF zone: ≥ 240 bpm (41 J shocks only). Ventricular sensitivity (automatic gain control or AGC) was nominal at 0.6 mV. As per subject request defibrillation testing was not performed. During follow-up visits the subject's R wave amplitudes were noted to be consistently greater than 25 mV. She remained asymptomatic during follow-up and was compliant with Metoprolol 25 mg orally twice a day.

Approximately 18 months after her initial implant, she suffered an out-of-hospital cardiac arrest requiring resuscitation by paramedics. Her arrhythmia logbook recorded 3 episodes of non-sustained VT and 4 episodes of VT within a 4-min period at the time of the event. ATP was delivered during 2 of the VT episodes. During the final VT episode, 3 bursts of ATP were delivered followed by 3×41 J shocks.

A segment of the AICD tracing from the final "VT" episode is shown in Fig. 1. The tracing shows 3 recording channels-

atrial channel (A), near field ventricular channel (V), and a far-field ventricular channel (shock). The atrial channel shows sinus arrest with 1 atrial sensed (AS) beat. Close inspection of the near-field and far-field ventricular channels shows VF undersensing. Although the large amplitude ventricular electrograms (at times as high as 14 mV) are sensed appropriately (annotated PVC, VT and occasionally VF), the smaller amplitude ventricular electrograms following the large electrograms are undersensed. These undersensed small ventricular signals frequently correlate with ventricular electrogram signals in the far-field shock-channel confirming their presence. After a sufficient number of sensed beats fell in the "VT" zone (<320 ms), the device administered "VT" therapy. Following 3 bursts of ATP and 2 unsuccessful 41 J shocks, a third AICD shock converted her back to sinus rhythm. The total duration of this "VT" episode was 1 min 15 s.

Ventricular pacing threshold was 0.9 V @ 0.5 ms and sensed R waves were noted to be > 25 mV. Lead impedances were normal. Defibrillation testing was performed in hospital and VF was induced with the AGC lowered to 0.3 mV.

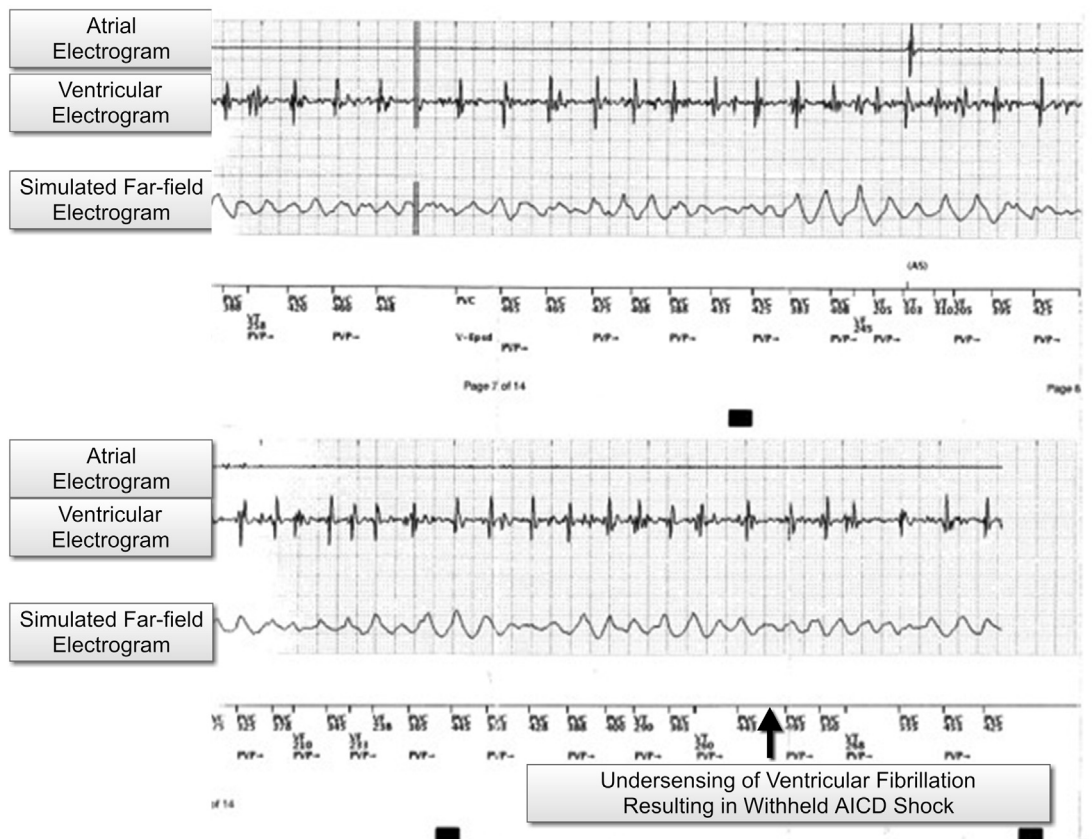


Fig. 1 – The device tracing shows 3 recording channels (atrial channel (A), near field ventricular channel (V), and a far-field ventricular channel (shock)). The atrial channel shows sinus arrest with 1 atrial sensed (AS) beat. Close inspection of the near-field and far-field ventricular channels shows VF undersensing. Although the large amplitude ventricular electrograms (at times as high as 14 mV) are sensed appropriately (annotated PVC, VT and occasionally VF), the smaller amplitude ventricular electrograms following the large electrograms are undersensed. These undersensed small ventricular signals frequently correlate with ventricular electrogram signals in the far-field shock-channel confirming their presence. After a sufficient number of sensed beats fell in the "VT" zone (<320 ms), the device administered "VT" therapy.

Undersensing of VF was noted and 41 J AICD shocks were unsuccessful in defibrillating the subject.

Discussion

We report a case of VF undersensing and high defibrillation thresholds in a subject with HCM with a current generation AICD. VF was misclassified as "VT" which delayed AICD shocks. Subsequent induction of VF during defibrillation testing confirmed undersensing of VF and high defibrillation thresholds.

An understanding of how AICDs sense ventricular arrhythmias is required to explain the undersensing noted in our case. Most manufacturers have developed algorithms that measure R-wave amplitude on a beat-to-beat basis. These algorithms are designed to detect small depolarization waves during VF and to prevent T-wave oversensing during VT. In a Boston scientific device, the algorithm is called "Automatic Gain Control" or "AGC". The sensing threshold is set at 75% of the sensed R-wave height, which declines over a pre-determined time constant. The algorithm was non-programmable in the Boston-Scientific device used in our subject. In our subject, large alternation of voltages during VF led to undersensing of smaller amplitude signals immediately following the larger signals. Lowering the AGC to 0.3 mV proved to be insufficient for preventing undersensing in our subject. We speculate that HCM might have been responsible for the presence of high amplitude electrograms noted during VF in our subject.

Various mechanisms have been invoked for high amplitude regular intracardiac electrograms during episodes of VF with chaotic activity noted on the surface ECG. These include regional differences in refractory period of cardiac tissue and conduction blocks in certain regions of the myocardium during VF. It is possible that in our subject the relative difference in myocardial hypertrophy between the left and right ventricles might have resulted in heterogeneity of refractoriness. This might have been responsible for slower, higher amplitude ventricular activity in the right ventricle and simultaneous chaotic, disorganized fibrillatory activity in the left ventricle. Also, the asymmetric septal hypertrophy noted in our subject might have caused functional conduction block between the left and right ventricles manifesting as electrical heterogeneity during the clinical event [1].

Undersensing of VF in the setting of HCM has been previously reported. In a subject with HCM, large amplitude oscillation of electrograms and a Boston Scientific device, lowering the AGC from 0.43 mV to 0.18 mV led to appropriate sensing of VF [2]. In our case, lowering the AGC from 0.6 mV to 0.3 mV was unsuccessful in preventing undersensing during VF. However, the amplitude of R waves in sinus rhythm was smaller in Nestor's case report (9 mV) compared to our case (>25 mV), which could explain VF undersensing in our case. Another case report presented similar undersensing of VF in a subject with ischemic cardiomyopathy and large oscillating electrograms during defibrillation testing shortly after device implant. The sinus rhythm R wave amplitude in this case was 18.5 mV [1].

In our subject, we decided to add a dual shock coil lead because of the failure of 41 J shocks during defibrillation testing. At implant, we positioned the new AICD lead on the interventricular septum as this site had smaller sensed R wave voltages (13 mV). The intention was to avoid large oscillations in electrogram amplitudes during VF episodes. Finally, we chose to replace the Boston device with a Medtronic Protecta device. The algorithm in the Medtronic device is called "auto adjusting sensitivity" with a V sensitivity set at 0.3 mV. No undersensing of VF was noted during the test and the defibrillation threshold was 21 J. A possible reason for improved VF sensing during the second procedure could be attributed to the fact that the maximum sensitivity peak is limited to 10 times the programmed sensitivity value (e.g. 3 mV peak with a V sensitivity of 0.3 mV) in the Medtronic device. Small amplitude electrograms are more likely to be sensed following an electrogram with a low sensitivity peak. This is in contrast to the Boston Scientific device implanted previously, where the sensitivity peak is always 75% of the sensed R wave (e.g. 10.5 mV peak with VF amplitude of 14 mV). Other possible reasons for adequate sensing noted during the second defibrillation test include septal AICD lead position with lower sensed R wave amplitude and lesser oscillation in the electrogram amplitude.

This case raises the question as to whether defibrillation testing is required at the time of AICD implant in subjects with HCM. The largest study of defibrillation testing in subjects with HCM found that HCM subjects do not have higher defibrillation thresholds compared to other AICD populations [3]. However, this study did not report on the prevalence of VF undersensing. One can speculate that if defibrillation testing had been performed at the time of implant in our subject. VF undersensing and high thresholds could have been recognized and managed appropriately. The available evidence does not support a recommendation for routine defibrillation testing in subjects undergoing AICD implantation. The European Heart Rhythm Association/Heart Rhythm Society guideline recommends that the decision to perform defibrillation threshold testing should be made on an individual basis by the implanting physician based on the relative risks and benefits in a given subject [4].

Conclusions

The presence of intermittent high amplitude electrograms during episodes of VF in AICDs using the AGC function should be recognized as a situation that may necessitate interventions to prevent undersensing and consequent delay in therapy.

Disclosures

None of the authors have any disclosures or conflicts of interest for this subject.

REFERENCES

-
- [1] Dekker LR, Schrama TA, Steinmetz FH, Tukkie R. Undersensing of VF in a patient with optimal R wave sensing during sinus rhythm. *Pacing Clin Electrophysiol* 2004;27:833-4.
 - [2] Galizio NOFG, Gonzalez JL, Medesani LA, Fraguas H, Comtesse D, Arroyo G. Undersensing of spontaneous ventricular fibrillation as a cause of sudden death in a child. *Rev Argent Cardiol* 2008:317-20.
 - [3] Quin EM, Cuoco FA, Forcina MS, Coker JB, Yoe RH, Spencer 3rd WH, et al. Defibrillation thresholds in hypertrophic cardiomyopathy. *J Cardiovasc Electrophysiol* 2011 May;22(5):569-72.
 - 4 Daubert JC, Saxon L, Adamson PB, Auricchio A, Berger RD, Beshai JF, et al., European Heart Rhythm Association (EHRA), European Society of Cardiology (ESC), Heart Rhythm Society, Heart Failure Society of America (HFSa), American Society of Echocardiography (ASE); American Heart Association (AHA), European Association of Echocardiography (EAE) of ESC, Heart Failure Association of ESC (HFA). 2012 EHRA/HRS expert consensus statement on cardiac resynchronization therapy in heart failure: implant and follow-up recommendations and management. *Europace* 2012 Sep;14(9):1236-86.