



CASE REPORT

Pyogenic granuloma associated with *Actinomyces israelii*



Kayo Kuyama ^{a,b*}, Kenji Fukui ^b, Eriko Ochiai ^b,
Masanobu Wakami ^c, Hirotaka Oomine ^d, Yan Sun ^a,
Miyuki Morikawa ^a, Kimiharu Iwadate ^b, Hirotosugu Yamamoto ^a

^a Department of Oral Pathology, Nihon University School of Dentistry at Matsudo, Chiba, Japan

^b Department of Forensic Medicine, The Jikei University School of Medicine, Minato-ku, Tokyo, Japan

^c Department of Crown and Bridge Prosthodontics, Nihon University School of Dentistry at Matsudo, Chiba, Japan

^d Department of Maxillo-Facial Orthodontics, Nihon University School of Dentistry at Matsudo, Chiba, Japan

Received 19 March 2012; Final revision received 13 September 2012

Available online 2 May 2013

KEYWORDS

Actinomyces israelii;
actinomycosis;
DNA sequence;
nested PCR;
pyogenic granuloma

Abstract Peculiar findings of orofacial actinomycosis mimicking the clinical appearance of a tumor of the upper gingiva are reported. An 83-year-old man with bleeding of the gingiva visited our hospital. The clinical diagnosis was a benign gingival tumor, and the lesion was surgically removed. Histologically, the excised specimens showed an ulcerative granuloma lesion covered by bacterial colonies consisting of club-shaped filaments. DNA samples were extracted from paraffin sections and examined by polymerase chain reaction (PCR) for *Actinomyces* species. The PCR products examined by direct DNA sequencing demonstrated the presence of *Actinomyces israelii*. Finally, a pathological diagnosis was made of a pyogenic granuloma associated with actinomycosis. The PCR method aided the early and exact diagnosis of the paraffin-embedded sample of oral mucosal infectious diseases including actinomycosis.

© 2018 Association for Dental Sciences of the Republic of China. Publishing services by Elsevier B.V. This is an open access article under the CC BY-NC-ND license (<https://creativecommons.org/licenses/by-nc-nd/4.0/>).

* Corresponding author. Department of Oral Pathology, Nihon University School of Dentistry at Matsudo, 2-870-1, Nishi-Sakae cho, Matsudo City, Chiba Prefecture, Japan.

E-mail address: kuyama.kayo@nihon-u.ac.jp (K. Kuyama).

1991-7902/© 2018 Association for Dental Sciences of the Republic of China. Publishing services by Elsevier B.V. This is an open access article under the CC BY-NC-ND license (<https://creativecommons.org/licenses/by-nc-nd/4.0/>).

<http://dx.doi.org/10.1016/j.jds.2012.09.026>

Introduction

Pyogenic granulomas are a form of nonneoplastic inflammatory hyperplasia that respond to various stimuli such as chronic local irritation, trauma, and hormonal changes.¹ A case of infection of *Actinomyces israelii* with associated pyogenic granuloma formation is described.

A diagnosis of actinomycosis is commonly made by histological examination that reveals a characteristic picture of sulfur granules. A polymerase chain reaction (PCR) and DNA sequencing enable the identification of bacterial species and strains that are difficult or even impossible to grow in artificial culture. This case was diagnosed by histopathological findings and DNA analyses.

The clinical appearance of a benign tumor of the upper gingiva is reported clinically and histopathologically with a review.

Case report

An 83-year-old Japanese man who suffered from bleeding of the buccal gingiva around the maxillary right second premolar was referred to Nihon University School of Dentistry at Matsudo Hospital (Matsudo, Japan). The first time the patient had noticed bleeding from a swelling with erosive surface by tooth brushing was 1 month previously. Although there was no spontaneous bleeding, the lesion caused the patient discomfort.

An oral examination revealed an elevated, pedunculated tumorlike lesion of 1.5 × 2.0 cm with a hemorrhagic surface of the buccal gingiva around the maxillary right second premolar. It was deep red, without spontaneous pain and had a rather soft consistency. The patient was not clear about the development time. There were no dental prostheses in that area or any indications of persistent infection. Dysplastic/malignant findings were not observed as a result of exfoliative cytology. Under a clinical diagnosis of a benign gingival tumor, an excision biopsy was performed.

Copious amounts of endothelial cells and small dilated capillaries were observed in the connective tissue (Fig. 1). Erythrocytes or blood plasma ingredients filled many of the

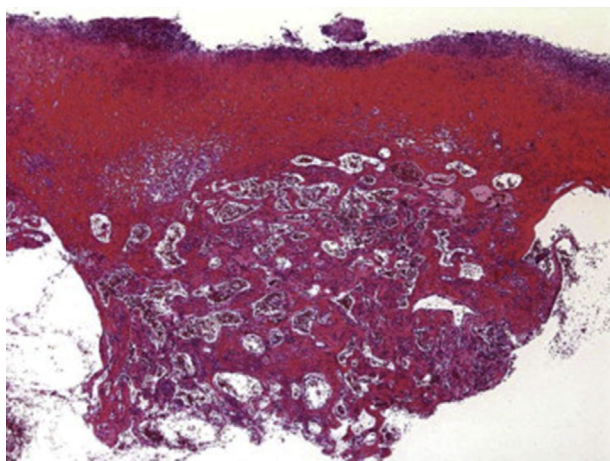


Figure 1 Vascularity of the connective tissue was obvious at low-power magnification.

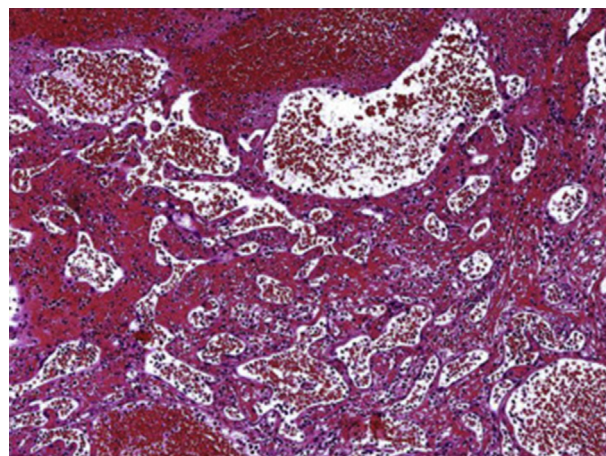


Figure 2 Demonstration of inflammatory granulation tissue composed of numerous endothelial cells lining enlarged capillary blood vessels, as well as inflammatory cells and fibroblasts.

enlarged capillaries (Fig. 2). There was a moderately intense infiltration by polymorphonuclear neutrophils, lymphocytes, and plasma cells, bleeding, and proliferation of fibroblasts. The lesion was ulcerated and covered with thick fibrous exudates. Additionally, vast numbers of bacterial colonies positive for hematoxylin surrounded the periphery of the uppermost surface of the ulcerated lesion (Fig. 3). Under high-power magnification, colonies were composed of a meshwork of filaments that stained with hematoxylin such as the so-called "ray fungus".

Because actinomycosis was suspected histopathologically, bacterial DNA was analyzed. Serial paraffin sections (10 μm thick) were cut from formalin-fixed and paraffin-embedded tissues of the excised specimen. Three sections were treated using DEXPAT[®] (Takara Bio, Kyoto, Japan) for DNA extraction. A nested PCR and DNA sequencing were carried out to detect *A. israelii*. The oligonucleotide primers used in this study are summarized in Table 1.² The PCR products were resolved by 2% agarose gel electrophoresis, and amplified bands were confirmed (Fig. 4). Direct

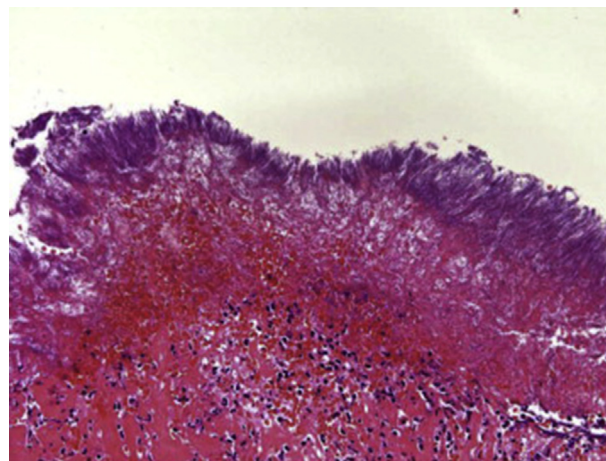


Figure 3 Colonies composed of a meshwork of filaments that stained with hematoxylin like the so-called "ray fungus".

Table 1 PCR primers and amplicon sizes in this study.

Primer name	DNA sequence of PCR primer (5' → 3')	Amplicon size (bp)
ACM-F-1	AAGTCGAACGGGTCTGCCTTG	237
ACM-R-1	TCAAAGCCTTGGCAGGCCATC	
ACM-F-2	TAACCTGCCCTCACTTCTGG	170

DNA sequencing of the PCR products was performed using a BigDye[®] Terminator v3.1 Cycle Sequencing Kit (Life Technologies Corporation, Carlsbad, CA, USA). DNA sequences were compared to the 16S ribosomal RNA gene of *A. israelii* (GenBank accession no. X82450.1). This molecular biological evidence indicated that tumorlike granulation tissue was infected with *A. israelii*.

Discussion

Oral pyogenic granulomas are a common vascular proliferation resulting from chronic low-grade irritation of the mucous membranes, and they account for approximately 1.5–7.0% of all biopsies from the oral cavity.^{3,4} Reports of

oral pyogenic granuloma associated with actinomycosis are rare, although nonspecific pyogenic granulomas are relatively common. There are two histological types of pyogenic granulomas^{5,6}: the first type with highly vascular proliferation resembles granulation tissue, and the second type with proliferating blood vessels is organized in lobular aggregates accompanied by small inflammatory reactions. Herein, the present case was the first type.

The site distribution of oral pyogenic granulomas was also reported in the lips, tongue, and cheek, although they are observed most frequently in the gingiva.¹ However, gingival trauma is not always present in the clinical history,⁷ and food impaction or even rough restorations may be a precipitating factor in many of these patients¹ with poor oral hygiene and consequent calculus accumulation.⁸ The gingiva was also the site of the lesion in this case report and was also reported to be the predominant site with a range of 74–83% in previous studies.^{1,9} These localized overgrowths composed of mature collagen and cellular fibroblastic tissue are not considered to be neoplasms but rather hyperplastic inflammatory reactions.¹⁰ Moreover, the irritant agents may induce vascular, endothelial, or fibroblast growth factors that are known to be involved in angiogenesis and the development of oral pyogenic granulomas.¹ Presumably, this might explain the predominance of the gingiva among oral sites of pyogenic granulomas.

The pathogenesis of pyogenic granulomas has not clearly been defined. Various stimuli that are associated with the development of this type of lesion include traumatic injury, hormonal changes, and certain kinds of drugs.¹ Trauma was particularly mentioned as the most common initiating event. Approximately one-third of lesions occurred after an injury, so a history of trauma before the development of a lesion is not unusual, especially for extragingival oral pyogenic granulomas.¹ It was additionally speculated that there is an infectious cause because of the frequent presence of microorganisms. *Actinomyces* spp., which are normal inhabitants of the human oral cavity, have a tendency to penetrate submucosal tissues when there is a disruption of the mucosal barrier.^{11,12} *Actinomyces* spp. are also found in healthy persons, and *A. israelii* is the main causative bacteria.¹³ In the intraoral mucosal region, actinomycosis is rarely seen,^{14,15} and causative organisms that enter tissues through an area are sometimes prior triggers. We considered hypotheses about the generating mechanism in this case. The persistent actinomycosis infection had continued after the inflammatory granuloma developed due to minor injury to the gingiva, followed by capillary proliferation and enlargement from proliferation of endothelial factors.

A diagnosis of actinomycosis depends on the clinical findings in the patient, the demonstration of the organisms in tissue the histopathological specimens, and also upon their culture. However, a previous report pointed out that the organisms are difficult to culture.¹⁶ Some studies showed recurrence rates ranging from 3–23%.^{8,17} After complete excision, the lesion must be excised down to the underlying tissue, and predisposing factors must be removed to avoid recurrence.¹⁸

We diagnosed actinomycosis using a paraffin-embedded section. Applying the PCR method might be useful as a technique for microorganism identification to replace

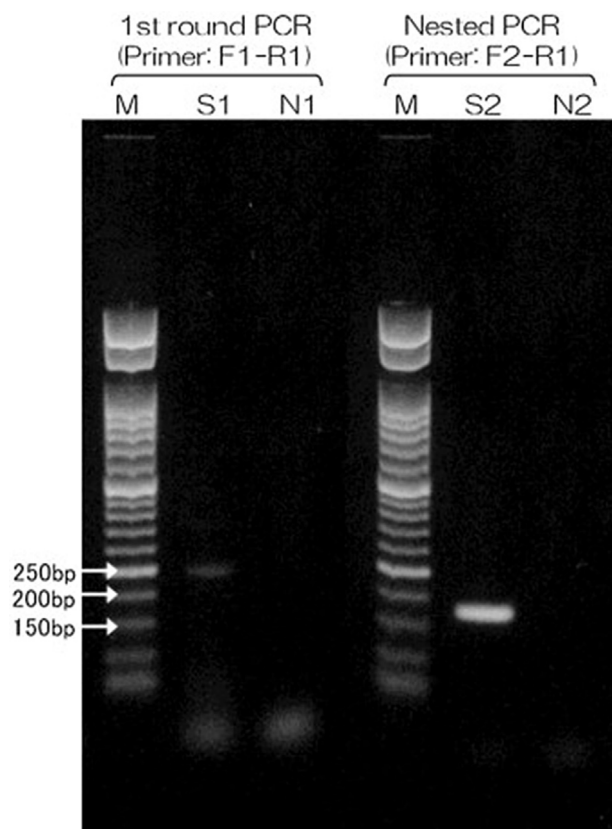


Figure 4 *Actinomyces israelii*-specific DNA amplified with a first-round PCR primer set, ACM-F-1 and ACM-R-1 (lanes S1 and N1), and with a nested PCR primer set, ACM-F-2 and ACM-R-1 (lanes S2 and N2). PCR products were separated by 2% ethidium bromide-stained agarose gel electrophoresis. Lane M, 50-bp ladder DNA marker; lanes S1 and S2, sample; lanes N1 and N2, negative control. PCR = polymerase chain reaction.

culture. However, the following possibilities should be considered. Because only *Actinomyces* was analyzed in the present study, combined infection with other microbes could not be eliminated. Combined infection with streptococci and staphylococci was also considered a possibility, and it remains a future subject for investigation. It was suggested that a diagnosis of the causative microorganisms of the irritation could serve as an aid to radical treatment of pyogenic granulomas.

References

1. Jafarzadeh H, Sanatkhan M, Mohtasham N. Oral pyogenic granuloma: a review. *J Oral Sci* 2006;48:167–75.
2. Hansen T, Kunkel M, Kirkpatrick CJ, Weber A. Actinomyces in infected osteoradionecrosis—underestimated? *Hum Pathol* 2006;37:61–7.
3. Akyol MU, Yalçiner EG, Doğan AI. Pyogenic granuloma (lobular capillary hemangioma) of the tongue. *Int J Pediatr Otorhinolaryngol* 2001;58:239–41.
4. Lawoyin JO, Arotiba JT, Dosumu OO. Oral pyogenic granuloma: a review of 38 cases from Ibadan, Nigeria. *Br J Oral Maxillofac Surg* 1997;35:185–9.
5. Neville BW, Damm DD, Allen CM, Bouquot JE. *Oral and Maxillofacial Pathology*, 2nd ed. Philadelphia: Saunders, 2002:447–9.
6. Bouduot JE, Nikai H. Lesions of the oral cavity. In: Gnepp DR, ed. *Diagnostic Surgical Pathology of the Head and Neck*. Philadelphia: Saunders, 2001:141–233.
7. Macleod RI, Soames JV. Epulides: a clinicopathological study of a series of 200 consecutive lesions. *Br Dent J* 1987;163:51–3.
8. Al-Khateeb T, Ababneh K. Oral pyogenic granuloma in Jordanians: a retrospective analysis of 108 cases. *J Oral Maxillofac Surg* 2003;61:1285–8.
9. Vilmann A, Vilmann P, Vilmann H. Pyogenic granuloma: evaluation of oral conditions. *Br J Oral Maxillofac Surg* 1986;24:376–82.
10. Bychner A, Calgeron S, Ramon Y. Localized hyperplastic lesions of the gingiva: a clinicopathological study of 302 lesions. *J Periodontol* 1977;48:101–4.
11. Appiah-Anane S, Tickle M. Actinomycosis—an unusual presentation. *Br J Oral Maxillofac Surg* 1995;33:248–9.
12. Lan MC, Huang TY, Lin TY, Lan MY. Pathology quiz case 1. Actinomycosis of the lip mimicking minor salivary gland tumor. *Arch Otolaryngol Head Neck Surg* 2007;133(411):414.
13. Ozaki W, Abubaker AO, Sotereanos GC, Patterson GT. Cervicofacial actinomycoses following sagittal split ramus osteotomy: a case report. *J Oral Maxillofac Surg* 1992;50:649–52.
14. Alamillos-Granados FJ, Dean-Ferrer A, García-López A, López-Rubio F. Actinomycotic ulcer of the oral mucosa: an unusual presentation of oral actinomycosis. *Br J Oral Maxillofac Surg* 2000;38:121–3.
15. Kuyama K, Sun Y, Fukui K, et al. Tumor mimicking actinomycosis of the upper lip: report of two cases. *Oral Med Pathol* 2011;15:95–9.
16. Brown JR. Human actinomycosis. A study of 181 subjects. *Hum Pathol* 1973;4:319–30.
17. Zain RB, Khoo SP, Yeo JF. Oral pyogenic granuloma (excluding pregnancy tumor)—a clinical analysis of 304 cases. *Singapore Dent J* 1995;20:8–10.
18. Shenoy SS, Dinkar AD. Pyogenic granuloma associated with bone loss in an eight year old child: a case report. *J Indian Soc Pedodont Prev Dent* 2006;24:201–3.