

Association of oral manifestations in ulcerative colitis: A pilot study

Mohan Kumar KP¹, Nachiammai N², Madhushankari GS¹

¹Department of Oral Pathology and Microbiology, College of Dental Sciences, Davangere, Karnataka, ²Department of Oral and Maxillofacial Pathology, Chettinad Dental College and Research Institute, Tamil Nadu, India

Abstract

Background: Ulcerative colitis (UC) is a chronic tissue destructive inflammatory bowel disease (IBD) of autoimmune origin characterized by predominant bowel symptoms such as abdominal pain, diarrhea and relapsing and remitting rectal bleeding, leading to loss of weight. Extraintestinal manifestations, including involvement of the oral cavity, may also occur. Oral involvement during IBD includes aphthous ulcers, pyostomatitis vegetans (PV) and lichen planus (LP).

Objectives: The purpose of this study was to document the oral manifestations in UC patients and also to evaluate whether oral manifestation can predict relapse and remission of UC.

Materials and Methods: Fifteen patients (8 men and 7 women) diagnosed for UC, in clinics of gastroenterology (with disease duration 5–15 years), with equal age- and sex-matched healthy controls were included in the study. All study participants were subjected to intraoral examination to evaluate for oral manifestation. The same patients were also asked a series of questions in the form of questionnaire to evaluate possible association between occurrence of oral manifestations and relapse of UC episode.

Results: PV, minor aphthous ulcer, LP, halitosis, dysgeusia, dry mouth, tongue coating, gingivitis and periodontitis were documented as oral manifestations in UC. PV, minor aphthous ulcer and LP exhibited relapse and remission with the severity of UC.

Conclusion: Our study revealed numerous and varied intraoral manifestations among the patients with UC. The previous episodes of oral manifestations were also similar and reported exacerbation of oral manifestations during relapses. Thus, oral manifestations can be used as an indicator of relapse in UC.

Keywords: Inflammatory bowel disease, oral manifestations, pyostomatitis vegetans, ulcerative colitis

Address for correspondence: Dr. Nachiammai N, A7 Villa house, Staff quarters, Chettinad Health City, Kelambakkam, Chennai - 603 103, Tamil Nadu, India.
E-mail: nachal.1987@gmail.com

Received: 08.12.2016, **Accepted:** 09.05.2018

INTRODUCTION

Inflammatory bowel disease (IBD) is a group of inflammatory conditions of the colon and small intestine, which principally includes Crohn's disease and ulcerative colitis (UC). In genetically susceptible individuals, an

inappropriate and continued inflammatory response by the complex interaction of environmental, genetic and immunoregulatory factors to gut microbiota is thought to result in UC. The current and more accepted theory is that intestinal inflammation is a consequence of an

Access this article online	
Quick Response Code:	Website: www.jomfp.in
	DOI: 10.4103/jomfp.JOMFP_223_16

This is an open access journal, and articles are distributed under the terms of the Creative Commons Attribution-NonCommercial-ShareAlike 4.0 License, which allows others to remix, tweak, and build upon the work non-commercially, as long as appropriate credit is given and the new creations are licensed under the identical terms.

For reprints contact: reprints@medknow.com

How to cite this article: Kumar KP, Nachiammai N, Madhushankari GS. Association of oral manifestations in ulcerative colitis: A pilot study. J Oral Maxillofac Pathol 2018;22:199-203.

abnormal action of T-lymphocytes on enteric bacterial flora in genetically susceptible individual. This chronic inflammation of the colonic mucosa causes ulceration, edema, bleeding, diarrhea and fluid and electrolyte loss.^[1] UC is a relapsing and remitting disease. Incidence and prevalence rate of UC in India are reported to be 6.02/10⁵ per year and 44.3/10⁵ population, respectively.^[2]

UC exhibits intestinal and extraintestinal complications. Local complications include ischio-rectal abscess, rectal prolapse, hemorrhoids, fibrous stricture, pseudopolyps, perforation, massive hemorrhage and also carcinoma of colon. Extraintestinal complications are common in UC and may dominate the clinical picture. Some of these occur during relapse of intestinal disease others appear unrelated to disease severity. These include erythema nodosum, pyoderma gangrenosum, skin eruptions, uveitis, arthritis, transient hepatitis and venous thrombosis.^[1]

As oral cavity is the portal of entry and part gastrointestinal (GI) tract, oral manifestations do occur. Oral manifestations of UC occur as a systemic complication or extraintestinal manifestation that may precede, exacerbate or regress with alterations in severity of the disease. Pyostomatitis vegetans (PV) is considered as a specific oral indicator of UC, and other manifestations such as aphthous ulcers, lichenoid lesion, halitosis, dysgeusia, dry mouth, coated tongue, gingivitis and periodontitis are considered as nonspecific oral manifestation.^[3-6]

The purpose of this study was to list and evaluate the oral manifestation in UC patients and also to evaluate whether oral manifestation can be a predictor for relapse and remission of UC.

MATERIALS AND METHODS

The study was conducted in clinics of gastroenterology, Davangere, Karnataka. Fifteen (8 males and 7 females) individuals diagnosed with UC [Figures 1 and 2 indicating active colitis, Figure 3 showing healing colitis] and their age- and sex-matched controls were included in the study by obtaining informed consent.

From the review of various studies and personal experience of oral manifestations of UC, a detailed case history format was prepared that included patient evaluation for PV, aphthous ulcer, lichenoid lesion, tongue coating, halitosis, dysgeusia, dry mouth, gingivitis and periodontitis. PV, aphthous ulcer (composite index),^[7] lichenoid lesion, tongue coating (Miyazaki *et al.*'s index)^[8] were assessed by clinical examination. Halitosis and dysgeusia were

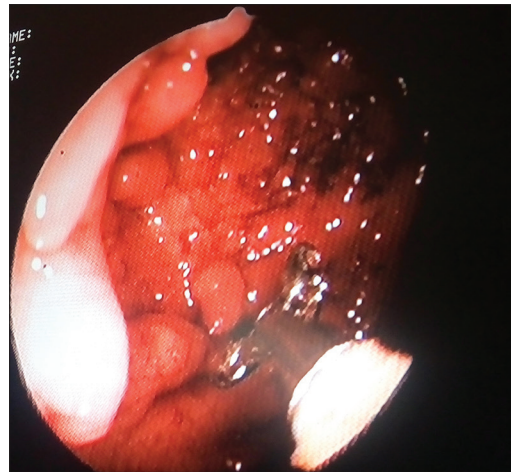

Figure 1: Multiple pseudopolyps with mucosal ulcers in the colon

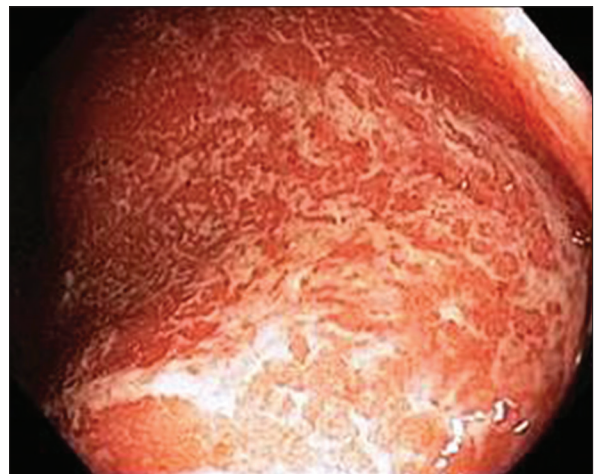


Figure 2: Mucosal irregularity with loss of vascular pattern and edematous appearance of the colon

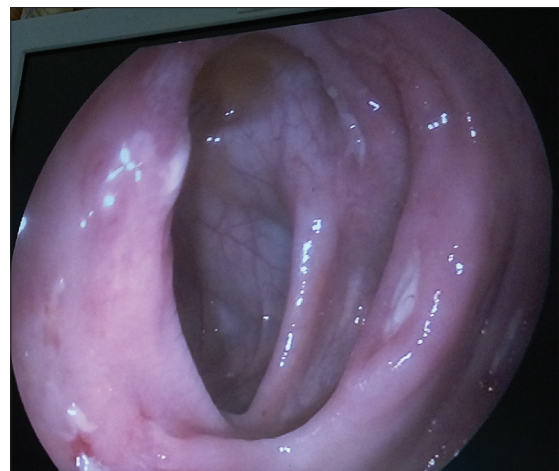

Figure 3: Healing ulcers in the colon

evaluated by series of questions, dry mouth by estimation of unstimulated salivary flow rate. Periodontal status was assessed by gingival and periodontal index. All the above parameters were assessed in diagnosed UC

patients. A questionnaire was prepared to evaluate these manifestations during the past remissions, which was explained to patients and was filled. All the parameters were compared with controls.

Statistical analysis

Mann–Whitney test was used for comparison of intergroup data. To evaluate the oral manifestations during previous episode and present status, Wilcoxon signed-rank test was applied. $P < 0.05$ was considered statistically significant.

RESULTS

The findings of the present study in the case group are depicted in Table 1. Of the 15 patients, 10 patients reported aphthous ulceration, one patient revealed PV, three patients exhibited lichenoid lesion, and 11–12 patients had halitosis and dry mouth and 4–5 patients showed coated tongue and dysgeusia. Salivary flow rate, tongue coating and periodontal status between study and control group are presented in Table 2. Salivary flow rate was significantly reduced, coated tongue was present and periodontal status was comparatively same in UC patients when compared to controls. Aphthous ulcer status during previous relapse and present status is statistically highly significant [Table 3]. Among all the manifestations, studied aphthous ulcer showed statistically significant values when compared between previous relapse of the disease and at present examination.

DISCUSSION

UC, an inflammatory bowel, is postulated that they result from unregulated and exaggerated immune response to commensal microbes in the gut in genetically susceptible individuals. The genetic susceptibility plays an important role, and the implicated genes regulate several important biologic functions including immunoregulation, mucosal barrier integrity and microbial clearance and/or homeostasis. The gene associated with UC MDR1 located on chromosome 7 physiologically protects cells from toxic substances or metabolites. Some genotypes of UC, HLADRB1*0103, B*27 and B*58 are linked with extraintestinal manifestations.^[9]

Oral lesions occur as an extraintestinal manifestation that may precede, exacerbate or regress with alterations disease. Thus, the present study was carried out to evaluate the oral manifestations and also to assess whether these manifestations can predict remission and relapse of UC.

Results of our study indicate that all the patients diagnosed with UC exhibited oral manifestations. Oral ulceration,

Table 1: Oral manifestations evaluated in the study group

Manifestation	Study group (n=15)
Pyostomatitis vegetans	1
Aphthous ulceration	10
Lichenoid lesion	3
Halitosis	12
Dysgeusia	5
Dry mouth	11
Tongue coating	4

Table 2: Salivary flow rate, tongue coating and periodontal status between study and control group

Manifestation	Study group	Control group	P
Salivary flow rate (ml/min)	1.5	1.98	0.02(S)
Tongue coating	4.5	3	0.12(NS)
Periodontal status			
Gingival index (score)	1.2	1.3	0.23 (NS)
Periodontal index (score)	1.0	1.4	
Loss of attachment (mm)	0.4	0.2	

NS: Not Significant

halitosis, altered taste and dry mouth were frequently prevalent oral manifestations in patients with UC.

One of the male patients presented with PV on the lower anterior gingiva, a specific oral manifestation of UC, and reported exacerbation during relapse.^[10] PV is common in young middle-aged adults with male predominance (3:1), clinically characterized by initial formation of 2–5 mm in diameter, abscess on erythematous mucosa, erode and coalesce, and undergoes necrosis to form “snail track” appearance. Sometimes, they correspond to exophytic lesions, producing a vegetating appearance. The surface is yellow creamy color and is covered by a pseudomembrane that easily disintegrates, facilitating formation of small ulcers and superficial erosion.^[11] The most common site of occurrence are the labial and buccal mucosa, hard and soft palate, gums and less frequently floor of the mouth. Histopathologically PV shows hyperkeratosis, acanthosis, intraepithelial and subepithelial microabscess with prominent neutrophil and eosinophilic infiltrate.^[12]

Several authors hypothesized that PV results from an aberrant immune response to yet unidentified factors. As IBD is the most common underlying disorder, it is postulated that the cross-reacting antigens in the bowel and mucosa to be responsible for secondary mucocutaneous manifestation.^[13] Thus, numerous case reports and few studies have suggested PV as a specific indicator of UC.

In the present study, 10 patients had aphthous ulcers and reported exacerbation of the aphthous ulcers during the previous relapse compared too, suggesting that aphthous ulcer evaluation can be used as an indicator of the relapse and remission. Aphthous ulceration in UC is due

Table 3: Aphthous ulcer status during previous relapse and present status in study group

Aphthous ulcer status	Composite index		
	Number of ulcers	Pain status (VAS Score)	Functional status affected due to ulcer
Previous Relapse	3.3	4	1.7
Present evaluation	0.9	1.2	0.5

$P=0.001$. HS: Highly significant

to micronutrient malabsorption of iron-inducing iron deficiency anemia and Vitamin B₁₂ in pernicious anemia. Our study results stimulate us to support findings of Correll *et al.*, who suggested that recurrent oral aphthous ulcers should be included as one of the factors in determining the occurrence, relapse and remission of UC.^[14]

Among the evaluated UC patients, three patients exhibited oral lichen planus (OLP). The co-occurrence of OLP and UC can be attributed to the side effects of drugs used such as sulfasalazine and diltiazem. It seems that aminosalicylic acid moiety of sulfasalazine drug is responsible for the reaction and that LP is a true complication of mesalazine therapy.^[15] Some authors indicated that OLP is a drug complication and discontinuation of sulfasalazine resolved the condition, whereas others contraindicated and reported that discontinuation did not resolve but instead became more extensive.^[13] Still further on, studies should be carried to prove whether OLP is a manifestation due to UC or reactive lesions to unavoidable medications used for the treatment of UC.

Twelve of our UC patients reported halitosis; this finding of ours was in accordance with Elahl *et al.* This finding can be due to an increased amount of colonic sulfate-reducing bacteria in UC patients, resulting in higher concentrations of the toxic gas hydrogen sulfide. Human colonic mucosa is maintained by the colonic–epithelial barrier and immune cells in the lamina propria. N-butyrate, a short-chain fatty acid, gets oxidized through the beta-oxidation pathway into carbon dioxide and ketone bodies. It has been shown that N-butyrate helps supply nutrients to this epithelial barrier. Studies have proposed that hydrogen sulfide plays a role in impairing this beta oxidation pathway by interrupting the short chain acetyl Co-A dehydrogenase, an enzyme within the pathway. An unrelated study suggested that the sulfur contained in red meats and alcohol may lead to an increased risk of relapse for patients in remission.^[16,17] Hence, red meat and alcohol should be avoided in UC patients.

Altered taste was reported by five UC patients, which was similar to the results of Elahl *et al.* It is considered to be due to long-term use of medication in the treatment of UC as sulfasalazine metabolizes to sulfapyridine. Serum sulfapyridine levels >50 µg/mL are associated with altered taste.^[18]

In our study, salivary flow rate was decreased when compared to controls which was in accordance with other studies^[19] and is thought to be due to long-term use of steroids and sulfasalazine therapy that decreases the secretory capacity of acinar cells. Four patients exhibited yellow-to-white discoloration with heavy thick coating and is suggested to be due to steroid therapy or superimposed candidal infection or stress-induced negligence of oral hygiene.

Periodontal status was comparable to that of controls and one of the cases exhibited severe gingivitis and periodontitis. Brito *et al.* suggested that IBD patients harbor higher levels of *Treponema denticola* and other bacteria that are related to opportunistic infections in inflamed subgingival sites that might be harmful for the crucial microbe–host interaction and responsible for severity of gingivitis and periodontitis.^[20]

Finally, UC patients are suggested to be prone to colonic cancer with increase in duration of colitis and relapse. Meta-analysis by Eden *et al.* suggested that with increase in duration of colitis, viz., 10, 20 and 30 years, the risk of colon cancer increases by 2%, 8% and 18%, respectively.^[21] Thus, simple early detection of oral manifestations in UC patients can aid in the prognosis, monitoring of relapse and remission and possibly in the prevention of colorectal cancer.

CONCLUSION

From the present study, oral symptoms and lesions such as aphthous ulceration, PV and also other manifestation should alert a clinician to elicit history and suspect the possibility of UC even in the absence of full-blown GI manifestations.^[21] Few patients of our study considered oral manifestation as the marker of disease severity and took adequate care.

Information regarding the oral manifestation in UC is less and is based mainly on case reports. The results of this study have been obtained based on a small number of patients; hence, studies on larger samples would provide more insight into the evaluation of oral manifestations in UC patients and their correlation with relapse and remission.

Acknowledgment

We would like to acknowledge Dr. Prakash. M. G, Sujana Gastroenterology and Maternity Centre, Davangere - 577004.

Financial support and sponsorship

Nil.

Conflicts of interest

There are no conflicts of interest.

REFERENCES

1. Friedman S, Blumberg RS. Inflammatory bowel disease. In: Kasper DL, Braunwald E, Fauci AS, Hauser SL, Longo DL, Jameson JL, editors. *Harrison's Principles of Internal Medicine*. 16th ed. USA: McGraw-Hill Companies, Inc.; 2005. p. 1776.
2. Gunisetty S, Tiwari SK, Bardia A, Phanibhushan M, Satti V, Habeeb MA, *et al.* The epidemiology and prevalence of ulcerative colitis in the South of India. *Open J Immunol* 2012;2:144-8.
3. Paradowska A. Oral cavity at ulcerative colitis – Preliminary study. *Dent Med Probl* 2008;45:382-5.
4. Daley TD, Armstrong JE. Oral manifestations of gastrointestinal diseases. *Can J Gastroenterol* 2007;21:241-4.
5. Edwards FC, Truelove SC. The course and prognosis of ulcerative colitis. III. Complications. *Gut* 1964;5:1-22.
6. Ganapelli A, Ayinampudi BK, Pacha VB, Podduturi SR, Gangula S, Sankireddy S. Oral indicators of ulcerative colitis: A rare case report and review of literature. *J Indian Aca Oral Med Radiol* 2012;24:56-62.
7. Mumcu G, Sur H, Inanc N, Karacayli U, Cimilli H, Sisman N, *et al.* A composite index for determining the impact of oral ulcer activity in Behcet's disease and recurrent aphthous stomatitis. *J Oral Pathol Med* 2009;38:785-91.
8. Van Tornout M, Dadamio J, Coucke W, Quirynen M. Tongue coating: Related factors. *J Clin Periodontol* 2013;40:180-5.
9. Rothfuss KS, Stange EF, Herrlinger KR. Extraintestinal manifestations and complications in inflammatory bowel diseases. *World J Gastroenterol* 2006;12:4819-31.
10. Lobkowicz F, Eckert F, Braun-Falco O. Pyostomatitis vegetans. A specific marker of Crohn disease and ulcerative colitis. *Hautarzt* 1991;42:92-5.
11. Knapp N, Albuquerque R, Khan Z, Richards A, Brown RM. Pyostomatitis vegetans in ulcerative colitis; management with topical tacrolimus and systemic azathioprine in a 10-year-old boy (case report and review of the literature). *J Int Oral Health* 2016;8:132-6.
12. Ruiz-Roca JA, Berini-Aytés L, Gay-Escoda C. Pyostomatitis vegetans. Report of two cases and review of the literature. *Oral Surg Oral Med Oral Pathol Oral Radiol Endod* 2005;99:447-54.
13. Femiano F, Lanza A, Buonaiuto C, Perillo L, Dell'Ermo A, Cirillo N, *et al.* Pyostomatitis vegetans: A review of the literature. *Med Oral Patol Oral Cir Bucal* 2009;14:E114-7.
14. Correll RW, Wescott WB, Jensen JL. Recurring, painful oral ulcers. *J Am Dent Assoc* 1981;103:497-8.
15. Alstead EM, Wilson AG, Farthing MJ. Lichen planus and mesalazine. *J Clin Gastroenterol* 1991;13:335-7.
16. Davies PT, Shadforth MF. Sulphasalazine induced oral lichen planus. *Br Med J* 1984;288:194.
17. Tannock GW. The bowel microbiota and inflammatory bowel diseases. *Int J Inflam* 2010;2010:954051.
18. Tilg H, Kaser A. Diet and relapsing ulcerative colitis: 'Take off the meat?' *Gut* 2004;53:1399-401.
19. Brito F, Zaltman C, Carvalho AT, Fischer RG, Persson R, Gustafsson A, *et al.* Subgingival microflora in inflammatory bowel disease patients with untreated periodontitis. *Eur J Gastroenterol Hepatol* 2013;25:239-45.
20. Eaden JA, Abrams KR, Mayberry JF. The risk of colorectal cancer in ulcerative colitis: A meta-analysis. *Gut* 2001;48:526-35.
21. Elahi M, Telkabadi M, Samadi V, Vakili H. Association of oral manifestations with ulcerative colitis. *Gastroenterol Hepatol Bed Bench* 2012;5:155-60.