



# Shortening of interpupillary distance after topical prostaglandin analog eye drop application in an ophthalmic surgeon: A case report

Ichiya Sano <sup>a</sup>, Hidenori Takahashi <sup>b,\*</sup>, Takeshi Hara <sup>c</sup>, Hidetoshi Kawashima <sup>b</sup>, Chihiro Mayama <sup>d</sup>

<sup>a</sup> Department of Ophthalmology, Shimane University, 89-1, Enya Izumo Shimane, Japan

<sup>b</sup> Department of Ophthalmology, Jichi Medical University, 3311-1, Yakushiji Shimotsuke, Tochigi, Japan

<sup>c</sup> Hara Eye Hospital, 1-1-11, Nishi Utsunomiya, Tochigi, Japan

<sup>d</sup> Department of Ophthalmology, Japan Community Health Care Organization Tokyo Shinjuku Medical Center, 5-1 Tsukudo-cho, Shinjuku-ku, Tokyo, Japan

## ARTICLE INFO

### Keywords:

Prostaglandin  
Prostaglandin-associated periorbitopathy  
Deepening of upper eyelid  
Interpupillary distance  
Glaucoma

## ABSTRACT

**Purpose:** This study reports a case of interpupillary distance (IPD) shortening after instillation of topical prostaglandin analog (PGA) eye drops.

**Observations:** The patient was a 36-year-old ophthalmic vitreoretinal surgeon from Tochigi, Japan, with primary open-angle glaucoma and bilaterally instilled PGA eye drops to decrease intraocular pressure. His IPD had been recorded closely based on surgical microscope settings. The patient had a stable IPD for over five years before the use of PGA drops. The patient noticed IPD shortening associated with latanoprost usage since four years. The IPD shortened further twice with temporal switching to bimatoprost. However, the IPD partially recovered both the times on discontinuing the medication over the course of several months.

**Conclusions and Importance:** Fluctuations in IPD with visible cosmetic changes occur in association with the use of topical PGA eye drops. There might be effects of PGA drops on binocular vision, which are possibly unaddressed and warrant further study.

## 1. Introduction

Prostaglandin analogs (PGAs) decrease intraocular pressure (IOP) through prostanoid prostaglandin F (FP) receptors. They are commonly used as first-line pharmacological agents in patients with glaucoma. The notable long-term side effects of therapy with PGAs are mostly cosmetic related, such as upper eyelid ptosis, deepening of the upper eyelid sulcus (DUES), orbital fat atrophy, enophthalmos, flattening of lower eyelid bags, inferior scleral show, tight orbit, and dermatochalasis. These side effects are collectively referred to as prostaglandin-associated periorbitopathy (PAP).<sup>1</sup> Among them, DUES has been previously assessed through a series of facial photographs and is thought to be solely a cosmetic problem.<sup>2-6</sup> However, we have previously reported that these cosmetic changes may lead to interpupillary distance (IPD) changes.<sup>7</sup> Herein, we present a case of IPD changes over time as a result of treatment with PGA eyedrops.

## 2. Case report

A 36-year-old Japanese ophthalmologist was diagnosed with

bilateral primary open-angle glaucoma (POAG). The treatment of POAG comprised bilateral instillation of the topical PGA eye drops, 0.005% latanoprost (Xalatan, Viatris Inc., Tokyo, Japan) once daily. Despite experiencing atopic dermatitis, the patient never applied any topical agents over the skin around his eyes. The patient had no history of any oral or systemic medications, including steroids or steroid-sparing agents. The visual acuity of the patient with correction was 20/16, and the refractive error was  $-5.5$  diopters, with no astigmatism bilaterally. The patient's pre-treatment IOP was 15 mmHg in both the eyes. A diagnosis of POAG was established based on the presence of glaucomatous optic nerve head damage with corresponding early-stage visual field damage, an open angle, and no other ocular abnormalities or history of other ocular diseases. The ocular movements and pupillary examination findings were normal.

The patient is an experienced ophthalmic surgeon who has continually performed cataract and/or vitreoretinal surgeries. Each surgeon's IPD is recorded at their respective hospitals to set up surgical microscopes. The recorded IPD of our patient was 63.0 mm before starting treatment with PGA eye drops over 5 years ago. The IPD of the microscope was set at 63.0 mm during his surgeries.

\* Corresponding author. Jichi Medical University, 3311-1 Yakushiji, Shimotsuke-shi, Tochigi, 329-0498, Japan.

E-mail address: [takahah-ky@umin.ac.jp](mailto:takahah-ky@umin.ac.jp) (H. Takahashi).

<https://doi.org/10.1016/j.ajoc.2022.101480>

Received 16 December 2020; Received in revised form 4 March 2022; Accepted 6 March 2022

Available online 15 March 2022

2451-9936/© 2022 Published by Elsevier Inc. This is an open access article under the CC BY-NC-ND license (<http://creativecommons.org/licenses/by-nc-nd/4.0/>).

Six months after continuous instillation of latanoprost, the patient noticed slight difficulty in focusing when looking through the microscope. However, his visual fields had not worsened. Intraoperatively, the patient found that his IPD had changed slightly. On measuring IPD in units of 0.5 mm, the patient found that it had decreased to 62.5 mm.

Three years later, due to insufficient IOP reduction, the patient switched from latanoprost to 0.03% bimatoprost (Lumigan, Senju Pharmaceutical Co., Ltd., Osaka, Japan), another PGA eye drop, which has the highest efficacy compared with other PGAs, pharmacologically.<sup>8</sup> At that time, the patient had taken a hiatus from performing surgeries for three months for non-medical reasons. However, on resuming surgical procedures, the patient noticed blurring of vision when looking through the microscope. On measuring, his IPD measurement had shortened to 60.0 mm.

His IOP had not improved as expected, with right and left eye IOP of 15 and 13 mmHg, respectively. To reduce the IOP further, a combination of 0.005% latanoprost and 2% carteolol (Mikeluna, Otsuka Pharmaceutical Co., Ltd., Tokyo, Japan) was prescribed since the combination drug of bimatoprost was unavailable commercially. Three months after switching back to latanoprost from bimatoprost, his IPD had partially recovered to 61.5 mm, with an improvement in DUES. The IPD was repeatedly recorded using surgical microscope settings and sometimes measured using automatic refractometry. The time course of IPD, along with the first bimatoprost use, is shown in Fig. 1.

The patient used the latanoprost and carteolol combination for approximately one year, and his mean right and left IOP was 13 and 12 mmHg, respectively. Although his visual field did not worsen, optical coherence tomography findings were reviewed for progressive thinning and increased defect range. The patient was instructed to switch back to 0.03% bimatoprost, and the combination of 0.5% timolol and 1% brinzolamide (Azorga, Novartis Pharma K.K., Tokyo, Japan) was added to the treatment regimen. The right and left IOP decreased to 11 mmHg and 10 mmHg, respectively, with the use of these drugs. However, the DUES worsened eight weeks after bimatoprost instillation. For cosmetic reasons, the surgeon stopped PGA administration briefly and added 0.1% brimonidine (Aiphagan, Senju Pharmaceutical Co., Ltd., Osaka, Japan). The IPD change was monitored very closely via surgical microscope setting and automatic refractometry. The patient's IPD showed a continuous decrease from 61.5 mm to 59 mm immediately after restarting the use of bimatoprost for eight weeks. However, the IPD increased immediately after drug discontinuation and increased to 61 mm in 4–6 weeks (Fig. 2a). The appearance of DUES also changed with the degree of his IPD during this period (Fig. 2b). Notably, DUES was most obvious when his IPD was shortest.

### 3. Discussion

To the best of our knowledge, this is the first case report focusing on detailed personal IPD changes over time associated with the use of two different PGA eye drops. We have previously reported the shortening of IPD after instillation of topical PGAs in a retrospective study.<sup>7</sup>

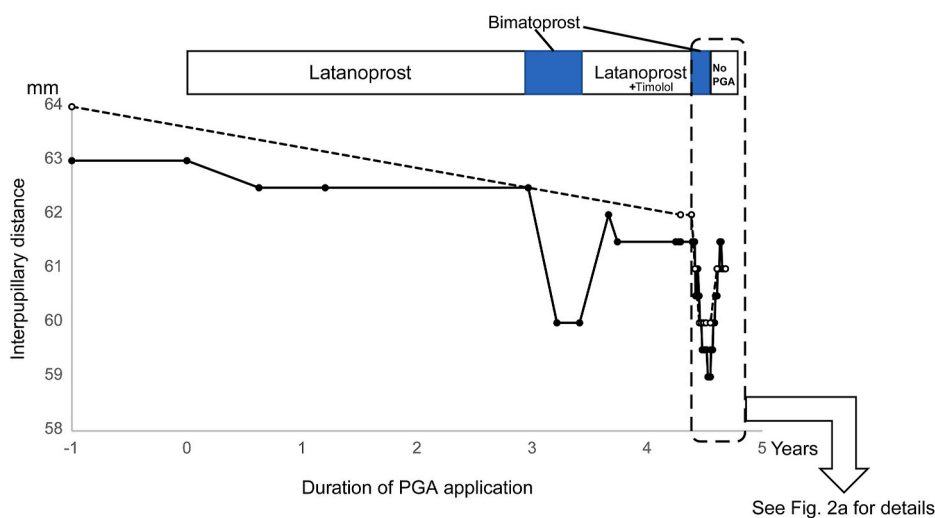
IPD shortening can occur due to PAP. The mechanism of this side effect is unclear. However, the involvement of fat atrophy and adipogenesis inhibition has been suggested in the process.<sup>9</sup> The pathophysiology of PAP comprises decreased fat production in the periorbital fat tissues through activation of FP receptors, resulting from the use of topical PGA eye drops.

We have previously explained the theoretical principles of the anatomic shortening of IPD in greater detail.<sup>7</sup> Decreased orbital fat may induce simultaneous dorsal movement of the eyeballs and shortening of IPD as the distance between the eye sockets shortens toward the posterior orbital apices.<sup>7</sup>

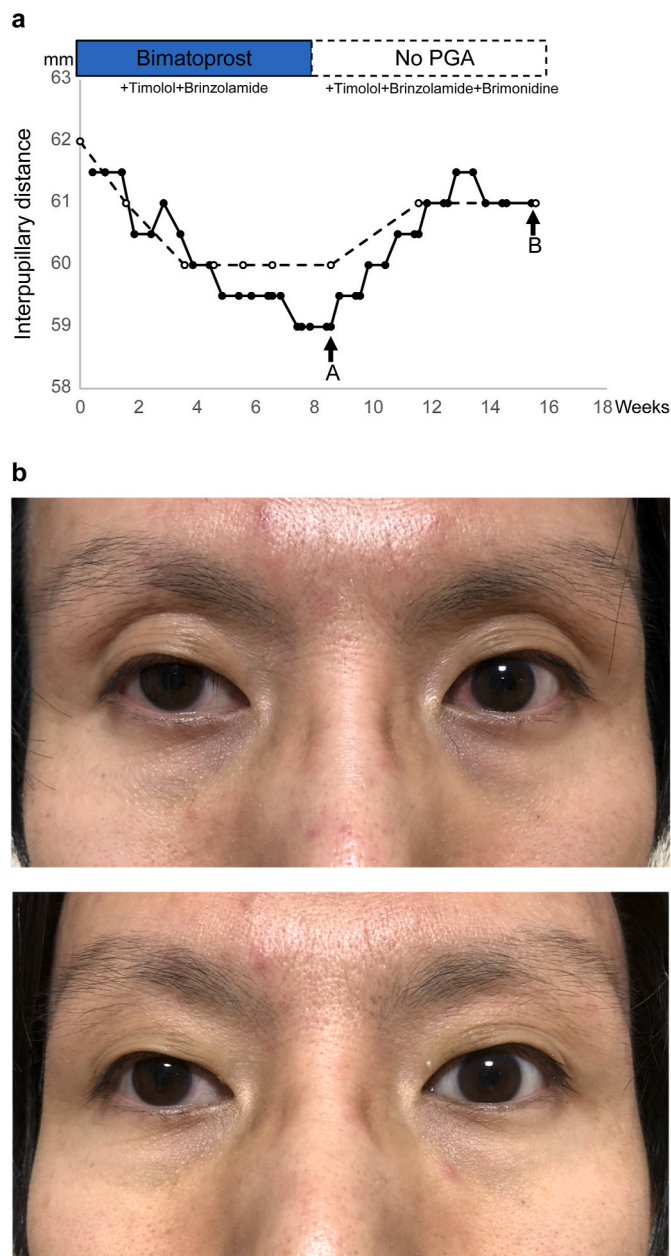
Another study found that among control patients and those treated with bimatoprost, travoprost, or latanoprost, the lowest densities of adipocyte cells obtained from preaponeurotic fat biopsies were from patients treated with bimatoprost. This shows that bimatoprost has a strong effect on PAP.<sup>9</sup> We have previously reported significant differences in the degree of IPD changes associated with different types of PGAs.<sup>7</sup> In that study, the average IPD change after bimatoprost instillation was -2.2 mm, which was similar to that in the current case. That previous study also reported that the frequencies and degrees of PAP differed among bimatoprost, travoprost, and latanoprost users, with a frequency of 80% in the bimatoprost group, 45% in the travoprost group, and 15.7% in the latanoprost group. In addition, PAP associated with bimatoprost use was more severe than that associated with latanoprost.<sup>10</sup>

The current case is noteworthy due to the time course and plasticity of IPD associated with the use of PGAs and their switching and discontinuation. According to a previous report, PAP can develop as quickly as within 4–6 weeks after initiating the use of PGA eye drops.<sup>1</sup> Moreover, IPD change and PAP incidence may occur simultaneously as both share the same mechanism: orbital volume reduction. Therefore, it is reasonable that IPD may shorten within the same period. In the current case, IPD shortened from 62.5 mm to 60.0 mm over a period of 3 months and shortened again from 61.5 mm to 59.0 mm over a period of 8 weeks with bimatoprost use. Concurrently, the patient's PAP symptoms became more evident.

Previous reports have described recovery from bimatoprost-induced PAP. Several studies have reported complete or partial improvement in PAP after bimatoprost discontinuation or after switching to



**Fig. 1.** The line graph shows changes in interpupillary distance (IPD) over time with the topical use of prostaglandin analogs (PGAs). The solid line indicates IPD measured manually using a microscope in 0.5-mm units. The outlined white dot and dotted line indicate IPD measured using automatic refractometry. The bar above the graph indicates the PGA used and the duration of use; given below these are the other glaucoma drugs used. The IPD decreases to 62.5 mm. After switching to bimatoprost, the IPD decreased to 60 mm and then recovered upon switching back to latanoprost from bimatoprost.



**Fig. 2.** a and b. The line graph in Fig. 2a shows change in inter pupillary distance (IPD) associated with the second short-term use of bimatoprost one year after the episode shown in Fig. 1. The solid line indicates IPD manually measured by a microscope. The outlined white dot and dotted line indicate IPD measured by an automatic refractometry. The bar above the graph indicates the prostaglandin analogs used and the duration of use; given below these are the other glaucoma drugs used. This graph illustrates changes during and after short-term bimatoprost use by the week, and IPD gradually shortened when using bimatoprost with partial recovery after discontinuation. The photograph (2b, above) shows deepening of the upper eyelid sulcus at the time marked A in Fig. 2a. The photograph (2b, below) shows an improvement in deepening of the upper eyelid sulcus at the time marked B in Fig. 2a.

latanoprost.<sup>1,6,9,11–14</sup> Another study has reported that PAP decreased significantly or even resolved after switching from bimatoprost to latanoprost as early as in two months in 11 out of 13 patients.<sup>15</sup> Our findings of IPD shortening with bimatoprost use and recovery after switching to latanoprost are consistent with that of previous studies. The patient's IPD recovered partially as early as within several months after PGA instillation was discontinued.

#### 4. Conclusions

In this case, the patient reported at least partial reversible changes in his IPD, which occurred along with the use, switching, and discontinuation of PGA eye drops. Although manual measurement using microscopy might not truly represent the exact objective index as a limitation to the current report, its change made the patient consider the influence of PGA eye drops on IPD. Generally, PAP has been considered only a cosmetic problem. However, this case indicated that IPD shortening might be associated with binocular vision quality. In some professionals, it is important to ascertain whether the use of PGA eye drops for treating glaucoma may adversely affect their ability to work.

#### Patient consent

The patient consented in writing to the publication of the case.

#### Institutional review board approval

Not Applicable.

#### Funding

No funding or grant support.

#### Authorship

All authors attest that they meet the current ICMJE criteria for authorship.

#### Declaration of competing interest

The authors declare that they have no known competing financial interests or personal relationships that could have appeared to influence the work reported in this paper.

#### Acknowledgments

None.

#### References

1. Peplinski LS, Albani Smith K. Deepening of lid sulcus from topical bimatoprost therapy. *Optom Vis Sci.* 2004;81(8):574–577.
2. Sakata R, Shirato S, Miyata K, Aihara M. Incidence of deepening of the upper eyelid sulcus in prostaglandin-associated periorbitopathy with a latanoprost ophthalmic solution. *Eye.* 2014;28(12):1446–1451.
3. Sakata R, Shirato S, Miyata K, Aihara M. Incidence of deepening of the upper eyelid sulcus on treatment with a tafluprost ophthalmic solution. *Jpn J Ophthalmol.* 2014;58(2):212–217.
4. Shah M, Lee G, Lefebvre DR, et al. A cross-sectional survey of the association between bilateral topical prostaglandin analogue use and ocular adnexal features. *PLoS One.* 2013;8(5), e61638.
5. Ung T, Currie ZI. Periocular changes following long-term administration of latanoprost 0.005. *Ophthalmic Plast Reconstr Surg.* 2012;28(2):e42–e44.
6. Yang HK, Park KH, Kim TW, Kim DM. Deepening of eyelid superior sulcus during topical travoprost treatment. *Jpn J Ophthalmol.* 2009;53(2):176–179.
7. Sano I, Takahashi H, Inoda S, et al. Shortening of inter pupillary distance after instillation of topical prostaglandin analog eye drops. *Am J Ophthalmol.* 2019;206:11–16.
8. Curran MP. Bimatoprost: a review of its use in open-angle glaucoma and ocular hypertension. *Drugs Aging.* 2009;26(12):1049–1071.
9. Park J, Cho HK, Moon JI. Changes to upper eyelid orbital fat from use of topical bimatoprost, travoprost, and latanoprost. *Jpn J Ophthalmol.* 2011;55(1):22–27.
10. Kucukveçilçioğlu M, Bayer A, Uysal Y, Altınsoy HI. Prostaglandin associated periorbitopathy in patients using bimatoprost, latanoprost and travoprost. *Clin Exp Ophthalmol.* 2014;42(2):126–131.
11. Aihara M, Shirato S, Sakata R. Incidence of deepening of the upper eyelid sulcus after switching from latanoprost to bimatoprost. *Jpn J Ophthalmol.* 2011;55(6):600–604.
12. Filippopoulos T, Paula JS, Torun N, Hatton MP, Pasquale LR, Grosskreutz CL. Periocular changes associated with topical bimatoprost. *Ophthalm Plast Reconstr.* 2008;24(4):302–307.

13. Nakakura S, Tabuchi H, Kiuchi Y. Latanoprost therapy after sunken eyes caused by travoprost or bimatoprost. *Optom Vis Sci.* 2011;88(9):1140–1144.
14. Yam JCS, Yuen NSY, Chan CWN. Bilateral deepening of upper lid sulcus from topical bimatoprost therapy. *J Ocul Pharmacol Therapeut.* 2009;25(5):471–472.
15. Sakata R, Shirato S, Miyata K, Aihara M. Recovery from deepening of the upper eyelid sulcus after switching from bimatoprost to latanoprost. *Jpn J Ophthalmol.* 2013;57(2):179–184.