

# Delayed bilateral facet dislocation at L4-5

## A case report

Hyung-Youl Park, MD<sup>a</sup>, Kee-Yong Ha, MD, PhD<sup>a</sup>, Young-Hoon Kim, MD, PhD<sup>a,\*</sup>, Sang-Il Kim, MD<sup>a</sup>, Hyung-Ki Min, MD<sup>a</sup>, In-Soo Oh, MD, PhD<sup>b</sup>, Jun-Yeong Seo, MD, PhD<sup>c</sup>, Dong-Gune Chang, MD, PhD<sup>d</sup>, Mohammed Ali Alhazmi, MD<sup>a</sup>, Joon-Hyung Cho, MD<sup>a</sup>

### Abstract

**Rationale:** Traumatic bilateral facet dislocation in the lumbar (L) spine has rarely been reported. All reported cases were presented with acute facet dislocation. However, we present the first case of delayed bilateral facet dislocation at L4-5.

**Patient concerns:** A 34-year-old woman presented with back pain after a head-on collision. The patient was treated conservatively for 3 months with rigid orthosis and activity restriction. Even after this conservative treatment, she continued to suffer from persistent back pain that radiated down her left leg and a progressively kyphotic posture.

**Diagnoses:** Initial imaging studies revealed a fracture of the left L5 superior articular process with a posterior ligament complex (PLC) injury. Subsequent radiographs showed the locked facet dislocation with kyphotic changes.

**Interventions:** The patient underwent surgical reduction and fusion, and the operative findings revealed the L4-5 bilateral facet dislocation and rupture of the PLC at the index level.

**Outcomes:** After surgical reduction and fusion at L4-5 by posterior interbody fusion, we achieved a satisfactory clinical outcome.

**Lessons:** Injury of the PLC in the lower lumbar region deserves careful attention for the development of sequelae. The anatomic transition from lordosis to kyphosis, in the lumbosacral region may be related to this type of injury.

**Abbreviations:** L = lumbar, MR = magnetic resonance, PLC = posterior ligament complex.

**Keywords:** joint dislocations, ligaments, lumbar vertebrae, spinal fusion

## 1. Introduction

Traumatic bilateral facet dislocation at L4-5 is extremely rare and to date only 4 cases have been reported (Table 1).<sup>[1-4]</sup> This dislocation is generally associated with high-energy trauma induced by rapid deceleration such as motor vehicle accidents (MVAs).<sup>[1,5-7]</sup> In this regard, all reported cases were presented

with acute facet dislocation. To the best of our knowledge, we present the first case of delayed bilateral facet dislocation at L4-5 and discuss the probable pathophysiologic mechanism.

## 2. Case report

A 34-year-old woman without any medical history was the passenger in a head-on collision. She complained of mild low back pain and was neurologically intact. A lumbar (L) spine computed tomography (CT) scan revealed the fracture of the L5 left superior articular process and sacralization of the L5 vertebra. Magnetic resonance (MR) images showed the disruption of the posterior ligament complex (PLC) at L4-5 (Fig. 1).

The patient was treated conservatively at another hospital for 3 months. After the initial 3 weeks of absolute bed rest, she was permitted to ambulate with a lumbosacral orthosis and restricted activity. Even after the conservative treatment, she continued to suffer from persistent back pain that radiated to her left leg and a progressively kyphotic posture. She was transferred to our hospital for further evaluation and treatment. Subsequent radiographs showed wide separation of the L4-5 interspinous space and locked facet dislocation with kyphotic changes (Fig. 2). Subsequent MR images further identified a rupture of the intervertebral disc and PLC. The extruded disc was mildly compressing the left L5 nerve root (Fig. 3).

We performed the surgery based on diagnosis of an L4-5 bilateral facet dislocation. The operative findings revealed a rupture of the PLC and severe adhesion of the ligament to the dura at the index level. The L5 superior articular facets were resected in order to reduce the dislocation. Pedicle screw fixation and posterolateral arthrodesis with autologous bone grafts were

Editor: N/A.

This work was supported by Small Grant for Exploratory Research (SGER) through the Ministry of Education of the Republic of Korea and The Catholic University of Korea Songjei (2018R1D1A1A02049202).

The authors have no conflicts of interest to disclose.

<sup>a</sup> Department of Orthopedic Surgery, Seoul St. Mary's Hospital, College of Medicine, The Catholic University of Korea, Seoul, <sup>b</sup> Department of Orthopedic Surgery, Incheon St. Mary's Hospital, College of Medicine, The Catholic University of Korea, Incheon, <sup>c</sup> Department of Orthopedic Surgery, Jeju National University Hospital, School of Medicine, Jeju National University, Jeju, <sup>d</sup> Department of Orthopedic Surgery, Sanggye Paik Hospital, College of Medicine, The Inje University, Seoul, Korea.

\* Correspondence: Young-Hoon Kim, Department of Orthopedic Surgery, Seoul St. Mary's Hospital, College of Medicine, The Catholic University of Korea, 222, Banpo-daero, Seocho-Ku, Seoul, 06591, Republic of Korea (e-mail: boscoa@catholic.ac.kr).

Copyright © 2018 the Author(s). Published by Wolters Kluwer Health, Inc. This is an open access article distributed under the terms of the Creative Commons Attribution-Non Commercial License 4.0 (CCBY-NC), where it is permissible to download, share, remix, transform, and buildup the work provided it is properly cited. The work cannot be used commercially without permission from the journal.

Medicine (2018) 97:38(e12483)

Received: 4 June 2018 / Accepted: 28 August 2018

<http://dx.doi.org/10.1097/MD.00000000000012483>

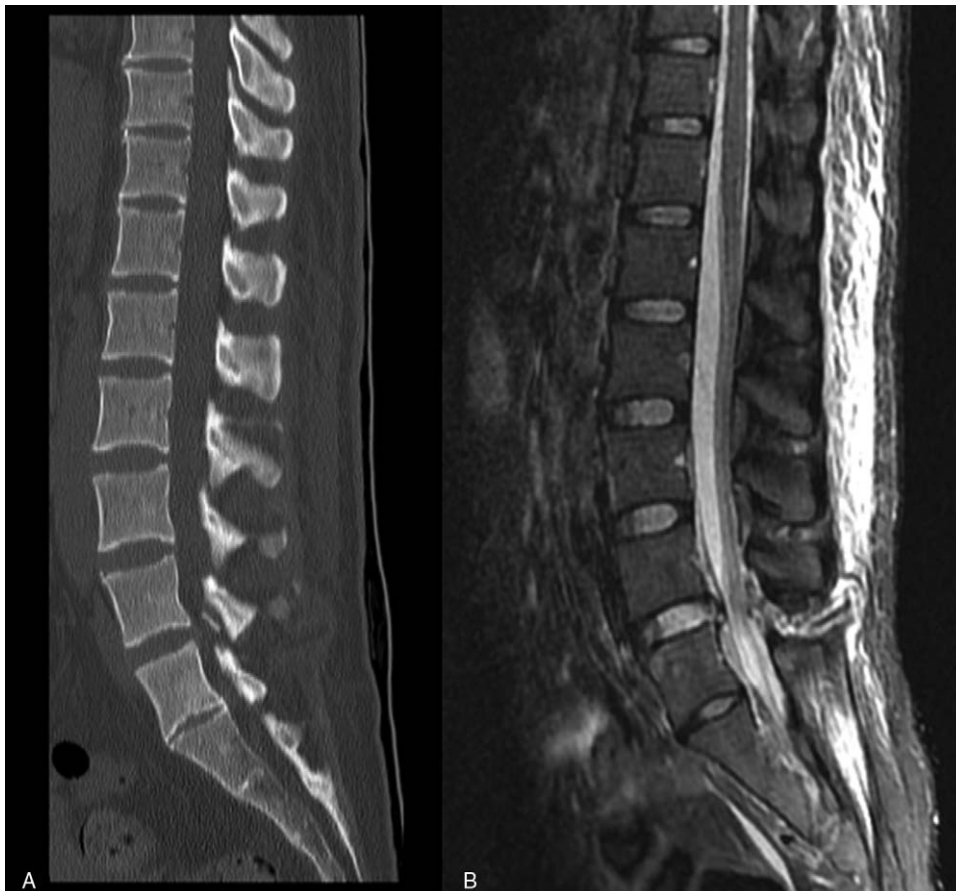
**Table 1****Previous case reports.**

Author & Year	Age	Sex	Trauma	Presenting symptoms	Time from injury to treatment	Treatment	Outcome
Mori et al <sup>[1]</sup> (2002)	32	F	MVA head on collision	Low back pain without neurologic deficit	2 weeks	Open reduction with resection of L5 superior facets, L4-L5 posterior pedicle screw fixation and posterior interbody fusion	Relief of pain Neurologically intact at 1 year and 6 months
Song et al <sup>[2]</sup> (2005)	47	F	MVA head on collision	Lumbodorsal pain without neurologic deficit	Immediate	Open reduction with partial removal of L4 and L5 lamina, L4-L5 pedicle screw fixation and posterior interbody fusion	Relief of pain Neurologically intact at 10 months
Deniz et al <sup>[3]</sup> (2008)	44	M	Fall from tractor after crashing into tree	Low back pain with numbness and weakness in both lower extremities	4 months (Patient refusal to operate)	Decompression, reduction with L3-L5 pedicle screw fixation and posterior interbody fusion	Relief of pain Neurologically intact at 3 months
Zenonos et al <sup>[4]</sup> (2016)	36	M	MVA head on collision	Without neurologic deficit	1 day	Open reduction with resection of pars and superior L5 facets, L3-S1 pedicle screw fixation and arthrodesis	Relief of pain Neurologically intact at 3 months

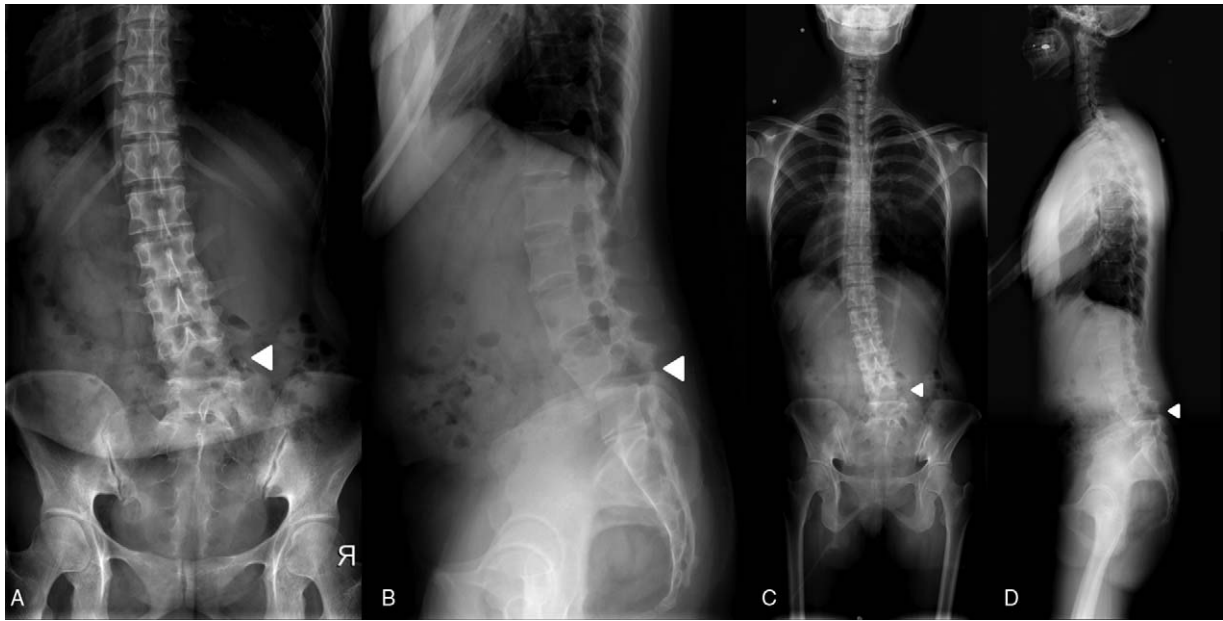
L=lumbar, MVA= motor vehicle accident, S=sacrum.

followed by posterior interbody fusion (Fig. 4). The patient ambulated on second postoperative day and was discharged home without neurologic deficit. The patient reported no low back pain at her 1-year follow-up.

This study was approved by the institutional review of board of Seoul St. Mary's hospital (KC17ZESI0255). Informed written consent was obtained from the patient for publication of this case report and accompanying images.



**Figure 1.** Initial lumbar spine CT images showing the fracture of the L5 left superior articular process (A) and MR images showing the disruption of the PLC at L4-5 (B). CT=computed tomography, MR=magnetic resonance, PLC=posterior ligament complex.



**Figure 2.** Subsequent preoperative radiographs showing wide separation of the L4-5 interspinous space and bilateral facet dislocation at L4-5 (arrow head). (A) Lumbar AP view. (B) Lumbar lateral view. (C) Whole spine AP view. (D) Whole spine lateral view.

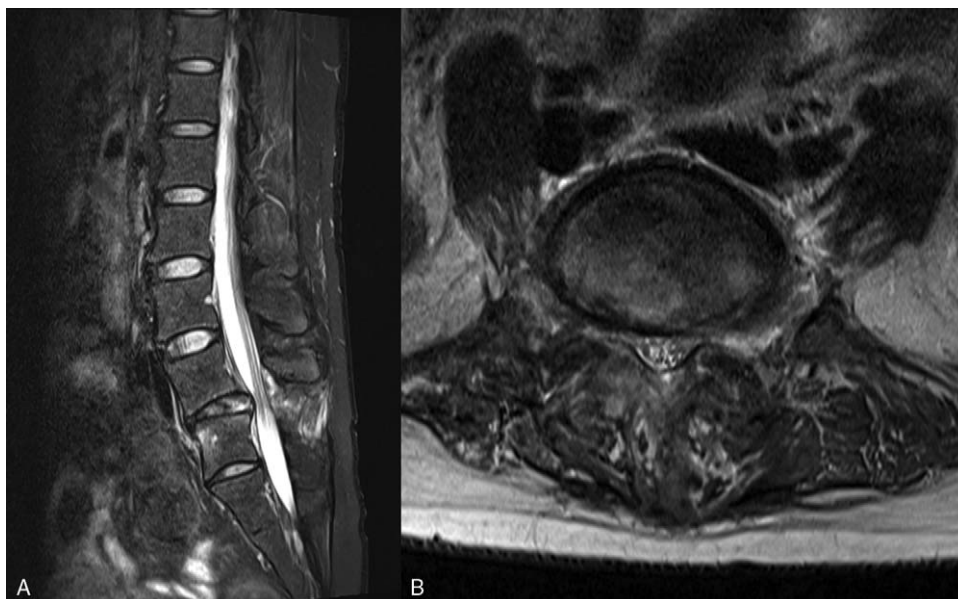### 3. Discussion

Bilateral facet dislocation at L4-5 is extremely rare and, to date, only 4 cases have been reported. All reported cases presented with acute facet dislocation.<sup>[1-4]</sup> However, in this case, the dislocation developed with a delayed onset.

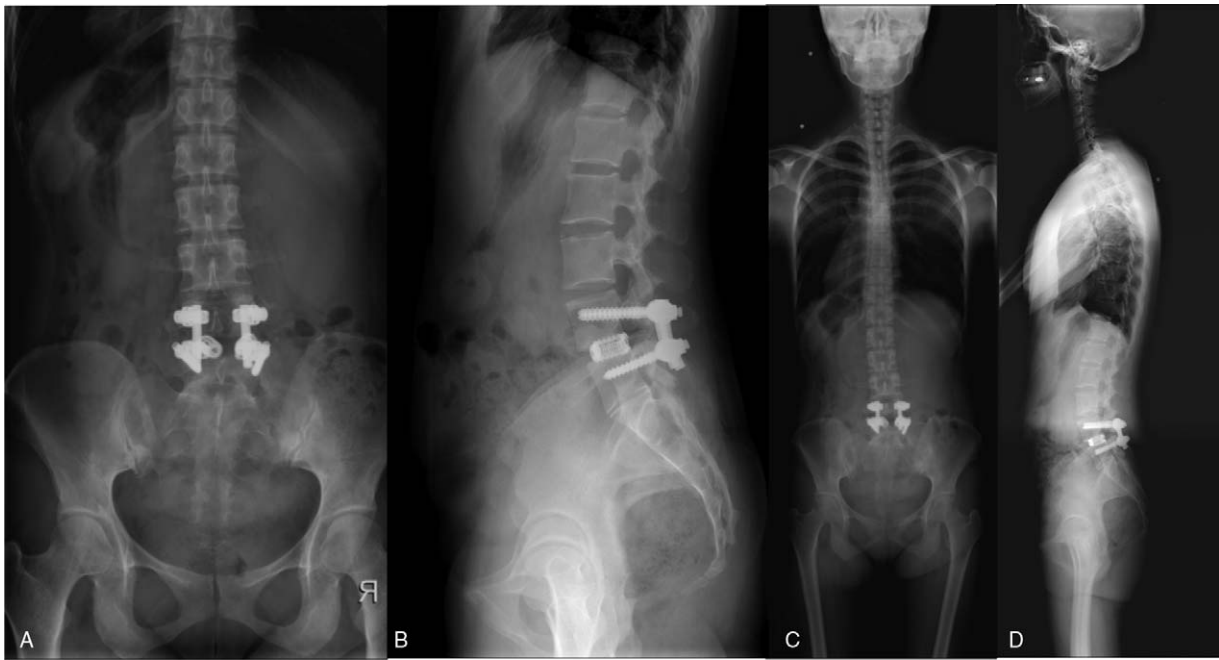
It is plausible that disruption of the PLC had a significant impact on the delayed onset of the bilateral facet dislocation. The PLC is composed of the facet capsules, ligamentum flavum, supraspinous ligament, and interspinous ligament and is thought to maintain the stability of the spine. Traumatic injury of the PLC can potentially cause spinal instability.<sup>[8]</sup>

In addition, Gillespie et al performed a biomechanical study of the effect of the posterior ligaments on spinal stability in a porcine model. The supraspinous and interspinous ligaments are the most significant structures which restrict flexion motion of the lumbar spine.<sup>[9]</sup> Although the PLC is thought to contribute significantly to the stability of the spine, a pathophysiologic mechanism of PLC injury of the lumbar spine is not completely understood.

In most reports, traumatic bilateral facet dislocations have been reported at the lumbosacral junction, which is vulnerable due to its transition from lordosis to kyphosis.<sup>[5,10,11]</sup> Lordosis of the lumbar spine makes it difficult for the kyphosis and dislocation to occur following trauma, which may help explain the relative rarity of



**Figure 3.** Subsequent preoperative MR sagittal images showing a rupture of the intervertebral disc (A) and axial images showing PLC and extruded disc mildly compressing the left L5 nerve root (B). MR=magnetic resonance, PLC=posterior ligament complex.



**Figure 4.** Postoperative radiographs showing reduction of the facet dislocation and restored alignment of L4 and L5. (A) Lumbar AP view (B) Lumbar lateral view. (C) Whole spine AP view. (D) Whole spine lateral view.

dislocations at L4-5 compared to lumbosacral dislocations. Interestingly, in our case, the sacralization of L5 vertebra changed the inflection point of lordosis to kyphosis from the lumbosacral junction to L4-5, which may have accelerated the development of the dislocation.

An open reduction of the dislocation may be achieved by resecting L5 superior articular process.<sup>[1]</sup> Intra-operative neuro-monitoring is helpful to avoid iatrogenic nerve root injury during the reduction.<sup>[12]</sup> Posterolateral fusion and posterior pedicle screw fixation is the surgery of choice.<sup>[13]</sup> In our case, posterior lumbar interbody fusion was performed due to the spinal instability.

The disruption of the integrity of PLC combined with anatomic transition from lordosis to kyphosis in the lumbosacral region may have altered the biomechanics of the lower L spine, resulting in the delayed bilateral facet dislocation. Patients who have experience this type of trauma should be watched closely for the development of delayed dislocation. If such a delayed dislocation does occur, our experience demonstrates that satisfactory clinical outcomes may be achieved through surgical reduction and posterior interbody fusion of L4-5.

#### Author contributions

**Conceptualization:** Hyung-Youl Park.

**Funding acquisition:** Hyung-Youl Park.

**Investigation:** Hyung-Youl Park, Sang-Il Kim, Hyung-Ki Min, In-Soo Oh, Jun-Yeong Seo, Dong-Gune Chang, Mohammed Ali Alhazmi, Joon-Hyung Cho.

**Supervision:** Kee-Yong Ha, Young-Hoon Kim.

**Writing - original draft:** Hyung-Youl Park.

**Writing - review & editing:** Kee-Yong Ha, Young-Hoon Kim.

#### References

- [1] Mori K, Hukuda S, Katsuura A, et al. Traumatic bilateral locked facet at L4-5: report of a case associated with incorrect use of a three-point seatbelt. *Eur Spine J* 2002;11:602–5.
- [2] Song KJ, Lee KB. Bilateral facet dislocation on L4-L5 without neurologic deficit. *J Spinal Disord Tech* 2005;18:462–4.
- [3] Deniz FE, Zileli M, Çağlı S, et al. Traumatic L4-L5 spondylolisthesis: case report. *Eur Spine J* 2008;17(suppl 2):S232–5.
- [4] Zenonos GA, Agarwal N, Monaco EA3rd, et al. Traumatic L4-5 bilateral locked facet joints. *Eur Spine J* 2016;25(suppl 1):129–33.
- [5] Das De S, McCreath SW. Lumbosacral fracture-dislocations. A report of four cases. *J Bone Joint Surg Br* 1981;63-b:58–60.
- [6] Veras del Monte LM, Bago J. Traumatic lumbosacral dislocation. *Spine (Phila Pa 1976)* 2000;25:756–9.
- [7] Levine AM, Bosse M, Edwards CC. Bilateral facet dislocations in the thoracolumbar spine. *Spine (Phila Pa 1976)* 1988;13:630–40.
- [8] Vaccaro AR, Lee JY, Schweitzer KMJr, et al. Assessment of injury to the posterior ligamentous complex in thoracolumbar spine trauma. *Spine J* 2006;6:524–8.
- [9] Gillespie KA, Dickey JP. Biomechanical role of lumbar spine ligaments in flexion and extension: determination using a parallel linkage robot and a porcine model. *Spine (Phila Pa 1976)* 2004;29:1208–16.
- [10] Fabris D, Costantini S, Nena U, et al. Traumatic L5-S1 spondylolisthesis: report of three cases and a review of the literature. *Eur Spine J* 1999;8:290–5.
- [11] Herron LD, Williams RC. Fracture-dislocation of the lumbosacral spine. Report of a case and review of the literature. *Clin Orthop Relat Res* 1984;205–11.
- [12] Xu R, Solakoglu C, Kretzer RM, et al. Bilateral traumatic dislocation without fracture of the lumbosacral junction: case report and review of the literature. *Spine (Phila Pa 1976)* 2011;36:E662–8.
- [13] Reddy SJ, Al-Holou WN, Leveque JC, et al. Traumatic lateral spondylolisthesis of the lumbar spine with a unilateral locked facet: description of an unusual injury, probable mechanism, and management. *J Neurosurg Spine* 2008;9:576–80.