

AN EXPERIMENTAL STUDY OF THE RELATION OF THE OVARY TO FAT METABOLISM.

BY MONTROSE T. BURROWS, M.D., AND CHARLES G. JOHNSTON.

*(From the Research Laboratories of The Barnard Free Skin and Cancer Hospital, and
the Department of Surgery of Washington University School of
Medicine, St. Louis.)*

PLATES 4 TO 6.

(Received for publication, May 26, 1925.)

The controlling influence of the ovary on cyclic changes in the uterus and breasts has been fully appreciated for many years. Recently Allen and Doisy (1) have isolated from the follicular fluid of the ovaries of pigs an alcohol-, ether-, and acetone-soluble substance, which induces estrus when introduced subcutaneously into spayed rats.

It is also known that the ovary has to do with the metabolism of fat in the body. Women store fat after the removal of the ovaries, destruction of the ovaries from one of various causes, and after the menopause. Women suffering a premature loss of function of their ovaries also suffer various other metabolic changes and disturbances. In order to throw light on this latter property of the ovary it became of interest to study the action of the Allen-Doisy hormone in the digestion of fat in the tissues.¹

In a previous study (2) we have shown that Mazola, or corn oil, which had been sterilized by heat, is not absorbed when injected into the subcutaneous tissue of most rats. In only one case out of thirty-nine was there any evidence of its absorption even after periods as great as 7 to 9 months (Fig. 3). This oil in the great majority of these cases simply breaks up into numerous small and larger droplets. Each of these droplets then becomes encapsulated by cells.

In this previous study we also described the method of the encapsulation of the oil droplets. These capsules are formed chiefly by large spherical shaped cells, having a single poorly staining nucleus. These cells are closely packed together at the edge of the oil droplet, forming a capsule one to several cells in thickness. Among these large cells are a few lymphocytes and neutrophils, and eosinophils, and polymorphonuclear and mononuclear leucocytes. The number of these

¹Read before the Society of Experimental Pathology, Washington, D. C., December 29, 1924.

latter cells is never large and is the number that may be present at any time in blood vessels and tissue adjacent to the place where the oil was introduced.

This capsule is formed primarily of cells which migrate to the oil from the surrounding tissues. The large round cells are fibroblasts and endothelial cells, which have been drawn with the lymphocytes and leucocytes to the oil from the surrounding connective tissue and capillaries. None of the cells of the capsules have formed through proliferation. They have migrated to the edge of the droplets of oil from the tissue. During this migration the fixed tissue cells have not only rounded off to spherical shaped cells, but have suffered a loss in their ability to stain sharply.

This process of migration ceases after 48 hours. Subsequent to this time the fibroblasts and endothelial cells gradually regain their ability to stain sharply. They lay down intercellular fibrils, stretch out along the surface of these fibrils, and assume spindle shapes. In a few cases where large numbers of these cells had become crowded together at the edge of the droplets, the nuclei of the cells show an increase in chromatin. One division figure was seen in one specimen of this kind during this later recovery period. As a rule, however, the only evidence of growth is the formation of intercellular fibrils. Subsequently these cellular fibrous capsules then slowly regress to a hyaline scar (Fig. 3). The leucocytes and lymphocytes remain unchanged for a time in the capsule. Then they gradually disappear.

Corn oil does not stimulate a growth of cells. It acts to cause regressive rather than constructive changes in them. Evidences of growth about these oil droplets manifest themselves late, after the oil has ceased to attract the cells from the surrounding tissue and otherwise act upon them. This recuperation of the cells and growth are more and the amount of earlier degenerative changes in the cells is less about the smaller droplets than the larger ones.

Allen and Doisy had dissolved their hormone in corn oil in order to facilitate its introduction into the subcutaneous tissue. In each instance a tumor formed at the site of the injection. Since oil produces such tumors it had been thought that this reaction was due alone to the oil. In order to throw light on the mechanism of the absorption of the corn oil in one of our animals and not in the others, and in view of the relation of the ovary to fat metabolism in the organism, it became of interest to remove and study histologically a number of these tumors produced by the oil plus the ovarian hormone.

The animals used for these experiments were 60 rats, 2 guinea pigs, and a monkey. The hormone was prepared by first extracting the fresh follicular fluid

from the ovaries of pigs with alcohol, filtering, and evaporating the alcohol solution to dryness. The residue was then extracted with ether. After the ether solution was filtered it was evaporated and the residue extracted with the corn oil. This oil-hormone mixture was then introduced into the subcutaneous tissue of the animals.

The corn oil containing the hormone when introduced into the tissue breaks up into droplets the same as the pure corn oil. It excites likewise a rapid migration of cells to it from the surrounding tissues. A capsule forms which is identical with that seen about the pure oil except that the cells in migrating to the oil show very little evidence of degeneration, but rather an early active growth and division and an early and active laying down of intercellular fibrils. The cells also invade the oil, remove it, and proliferate most actively in the space occupied by it. Many of the smaller droplets of oil are completely removed by this process and the space originally occupied by them becomes a dense mass of proliferating fibroblasts. In the larger droplets this process ceases generally after a small amount of the oil is removed. After a given period of such proliferation this mass of new cells then slowly regresses and disappears in the form of a hyaline scar.

The details of this process are illustrated in the description of experiments below.

Experiment 1.—Two guinea pigs were injected with 1 cc. of corn oil containing the ovarian extract. The tumors were removed after 6 days. These tumors, like the tumors formed by injecting pure corn oil, are composed of numerous encapsulated droplets of the oil. Each of these droplets is surrounded by a layer of cuboidal cells. Outside this layer are layers of fibroblasts which at this stage have laid down a considerable amount of intercellular material and have stretched out to a spindle shape. Mitoses are numerous not only in the layer of cells about the oil droplets (Fig. 1), but also in the layer of cells deeper in the capsule. In many places these inner capsular cells are proliferating rapidly, the oil is disappearing, and the space occupied by it is gradually being replaced by these proliferating cells (Fig. 2).

As shown by the later experiments this proliferation into the smaller droplets continues until the oil is entirely removed and its site replaced by a dense mass of proliferating cells.

Experiment 2.—A rat was injected with 2 cc. of Mazola oil containing ovarian extract. The tumor was removed after 3 weeks. About all of the oil cysts the cells are seen proliferating actively. Many of the smaller drops of oil have been

entirely removed and replaced by these growing cells (Fig. 4, *A*). In other cases the cells are seen to be growing and slowly invading the oil from all sides (Fig. 4, *B*). The larger droplets of oil are still present (Fig. 4, *C*). Their former single layer of lining cells is seen now, however, as a layer many cells in thickness. About the edge of these larger oil droplets cell processes can also be seen projecting out into the oil as they are seen in Fig. 4, *B*.

Experiment 3.—59 rats were injected with 1 to 5 cc. of corn oil plus the ovarian extract. The tumors were removed from time to time, between 1 week and 7 months thereafter. The sections of tissue removed within 1 month show pictures similar to that seen in the guinea pigs and rat of Experiments 1 and 2. Subsequent to this time the proliferating tissue slowly regresses. In the great majority of the cases only the smaller oil droplets are found to have been removed by the cells. In other sections all of the oil has been removed. Only the original fat of the subcutaneous tissue remains. This active proliferation of cells continues, however, for only about 2 to 3 weeks, when it ceases and regression takes place. The denser masses of cells which fill many of the small oil cavities lose their nuclei. Their cytoplasm unites with that of neighboring cells. It becomes more granular and stains less sharply (Fig. 5). In the lower power picture of these areas after 6 weeks to several months one finds a few oil drops remaining and other open spaces which resemble the lacunæ left by cholesterol crystals (Fig. 6). Finally this mass of cells which filled the oil space shrinks to appear as a single large cell containing no nucleus or one or more poorly staining nuclei. The surrounding tissue undergoes slow regression to a hyaline scar containing a few small oil droplets. This process of regression takes place more quickly in some animals than in others.

Experiment 4.—One spayed monkey received 1 cc. of the corn oil plus ovarian extract. The tumor was removed after 3 months. The oil has been completely removed from this tumor. The tumor is composed of a cellular mass regressing to a hyaline scar (Fig. 7). The open spaces shown in this figure are for the most part the fat droplets of the original tissue or secondary fat deposits in the regressing scar.

DISCUSSION AND CONCLUSIONS.

From these observations there seemed to be little doubt that the follicular fluid of the ovary contains an active growth-stimulating substance and one capable of initiating an active digestion of a foreign fat, which might otherwise remain unabsorbed for an indefinite time in the tissues of these animals (2).

We have not attempted to ascertain whether this substance exciting growth and a digestion of the oil is the same or in any way related to the substance exciting estrus in these animals. That it may be a different substance from the estrus-exciting substance is suggested,

however, by the fact that a similar excitant of growth and fat digestion has recently been extracted by the same method from the corpus luteum of pigs. These extracts of corpora lutea have not excited estrus in spayed rats.

In the one rat in which the pure oil was absorbed, the cells did not invade the oil, but the capsule remained cellular and the oil gradually disappeared from the space. In these experiments in which the active substance was added to the oil the cells have always invaded the oil.

BIBLIOGRAPHY.

1. Allen, E., Francis, B. F., Robertson, L. L., Colgate, C. E., Johnston, C. G., Doisy, E. A., Kountz, W. B., and Gibson, H. V., *Am. J. Anat.*, 1924-25, xxxiv, 133. Doisy, E. A., Ralls, J. O., Allen, E., and Johnston, C. G., *J. Biol. Chem.*, 1924, lxi, 711.
2. Burrows, M. T., and Johnston, C. G., *Arch. Int. Med.*, 1925 (in press).

EXPLANATION OF PLATES.

PLATE 4.

FIG. 1. A moderately high power photomicrograph of a part of a section of a 6 day old tumor of a guinea pig formed by injecting corn oil plus ovarian hormone.

FIG. 2. A moderately high power photomicrograph of another part of the section shown in Fig. 1.

PLATE 5.

FIG. 3. A high power photomicrograph of a part of a section of an 8 months old tumor of a rat produced by the injection of 6 cc. of pure corn oil into the subcutaneous tissue. This picture is included to facilitate comparison between the action of pure oil and oil plus ovarian hormone.

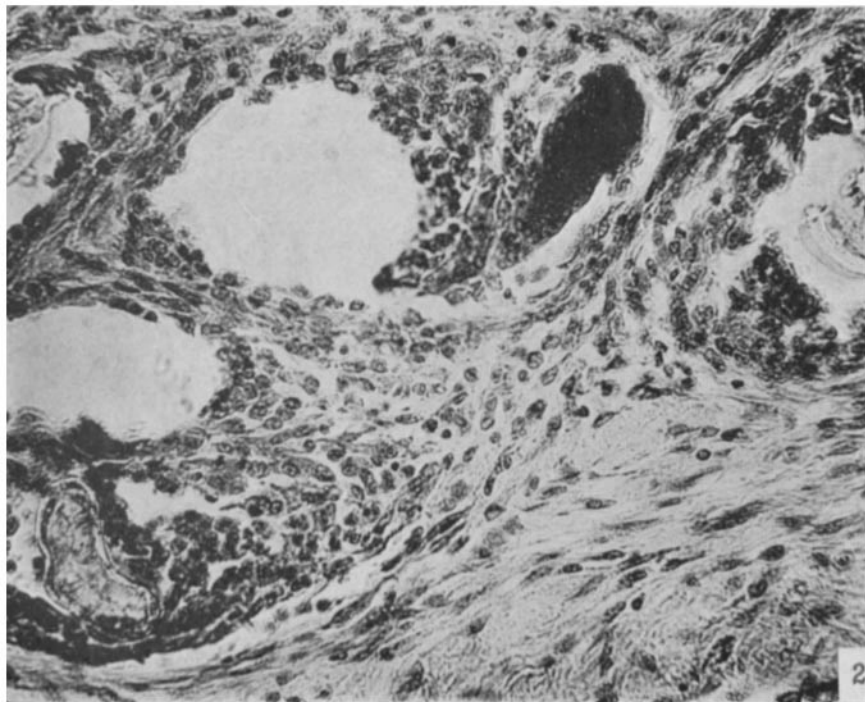
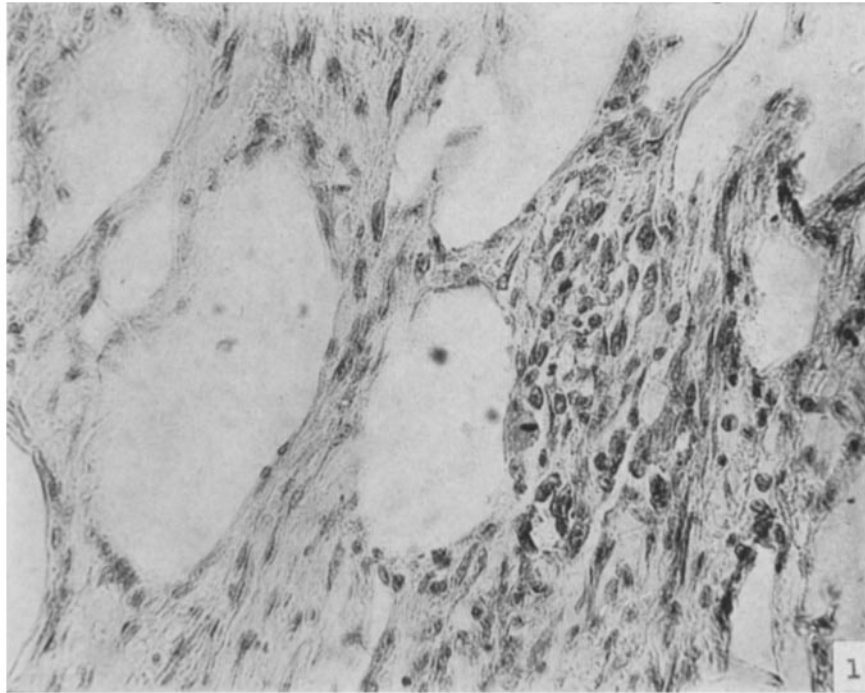
FIG. 4. A moderately high power photomicrograph of a part of a 3 weeks old tumor of a rat produced by injecting corn oil plus ovarian hormone.

PLATE 6.

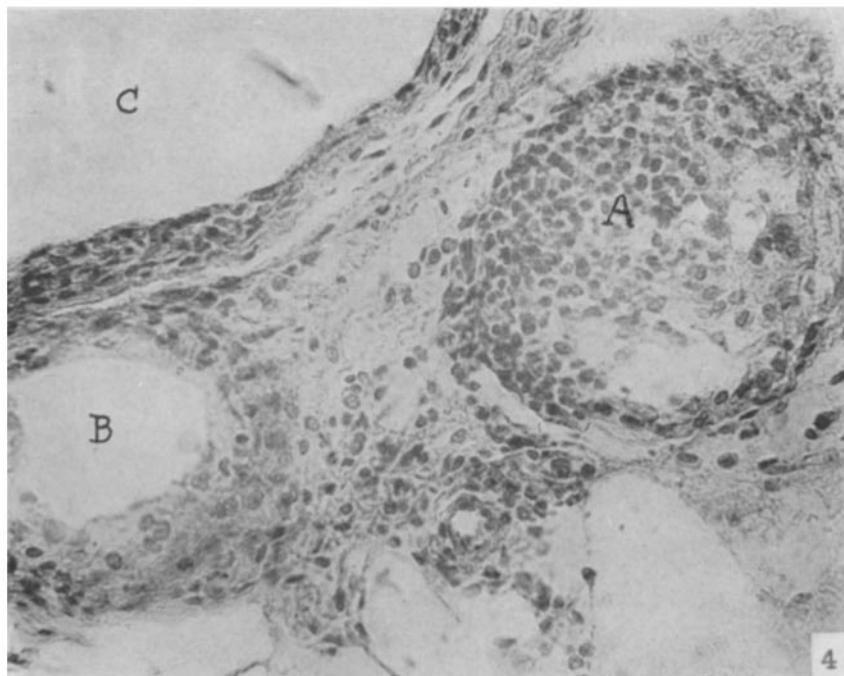
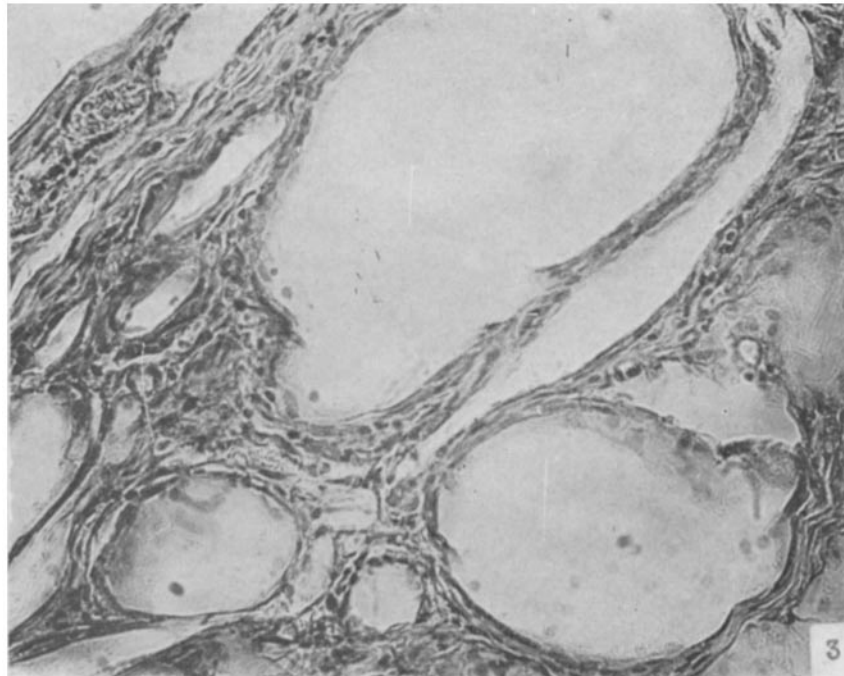
FIG. 5. A moderately high power photomicrograph of a section of a 7 months old tumor of a rat produced by injecting corn oil and ovarian hormone.

FIG. 6. A low power photomicrograph of the section shown in Fig. 5.

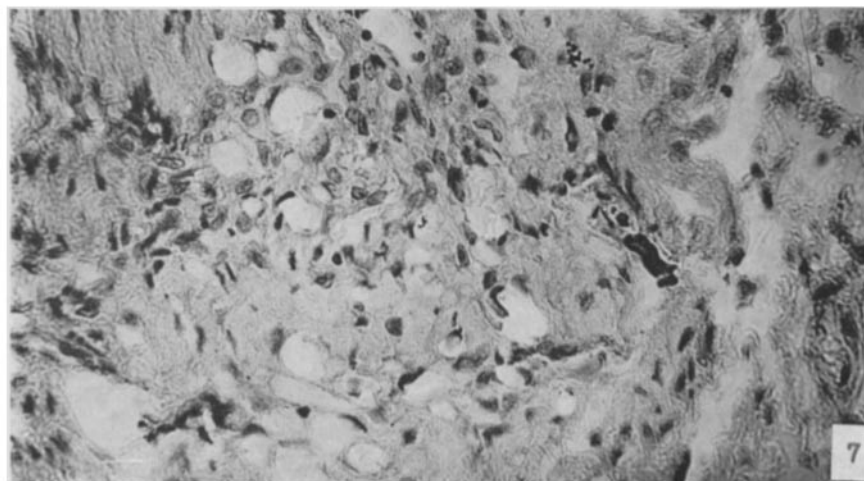
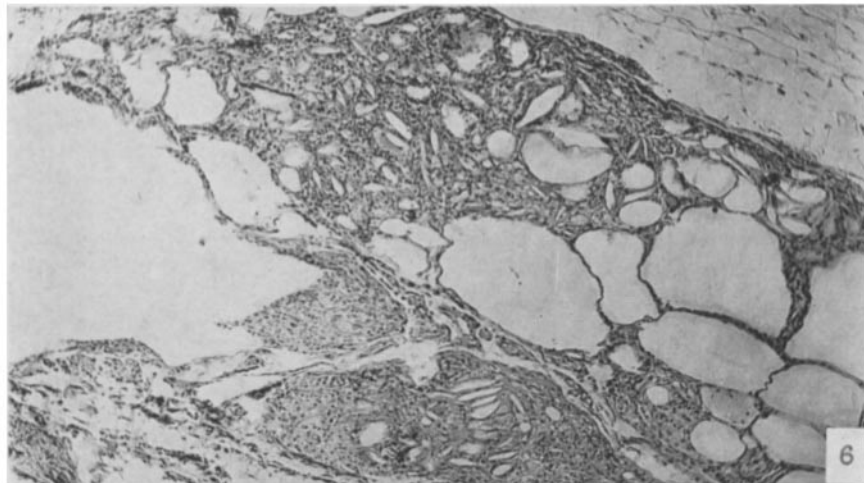
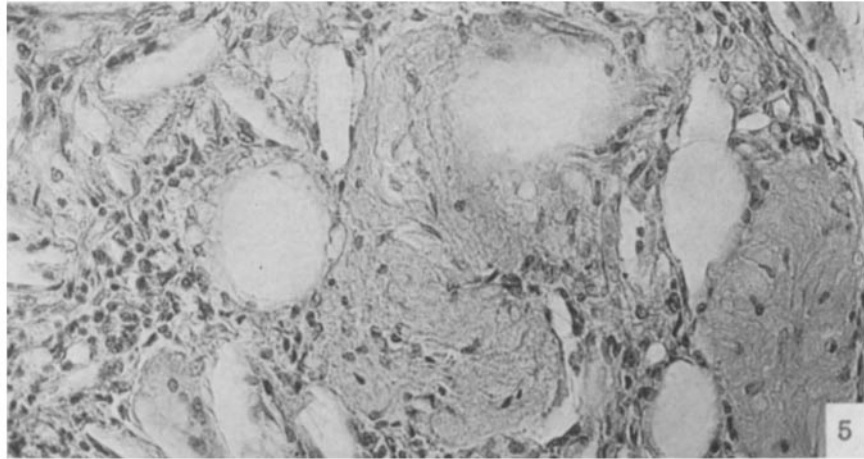
FIG. 7. A high power photomicrograph of a 3 months old tumor of a monkey produced by injecting 3 cc. of corn oil plus ovarian hormone.



(Burrows and Johnston: Relation of ovary to fat metabolism.)



(Burrows and Johnston: Relation of ovary to fat metabolism.)



(Burrows and Johnston: Relation of ovary to fat metabolism.)