

How the anal gland orifice could be found in anal abscess operations

Shahram Paydar¹, Ahmad Izadpanah¹, Leila Ghahramani¹, Seyed Vahid Hosseini¹, Alimohammad Bananzadeh¹, Salar Rahimikazerooni¹, Faranak Bahrami²

¹Colorectal Research Center, Shiraz University of Medical Sciences, Shiraz, Iran, ²Department of Surgery, Isfahan University of Medical Sciences, Isfahan, Iran

Background: On an average 30-50% of patients who undergo incision and drainage (I and D) of anal abscess will develop recurrence or fistula formation. It is claimed that finding the internal orifice of anal abscess to distract the corresponding anal gland duct; will decline the rate of future anal fistula. Surgeons supporting I and D alone claim that finding the internal opening is hazardous. This study is conducted to assess short-term results of optional method to manage patients with anal abscess and fitula-in-ano at the same time. **Materials and Methods:** In this cross-sectional descriptive study 49 from 77 patients with anal abscess whose internal orifice was not identified by pressing on the abscess, diluted hydrogen peroxide (2%) and methylene blue was injected into the abscess cavity and the anal canal was inspected to find out the internal opening. Once the opening was distinguished, an incision was given from the anal verge to the internal opening. **Results:** The internal orifice was identified in 44 out of 49 patients (90%) who underwent this new technique. Up to 18 months during follow-up, only 2.5% of patients with primary fistulotomy developed fistula on the site of a previous abscess. **Conclusion:** Conventional method to seek the internal orifice of anal abscesses is successful in about one-third of cases. By applying this new technique, surgeons would properly find the internal opening in >90% of patients. Needless to say, safe identification of the anal gland orifice in anal abscess disease best helps surgeons to do primary fistulotomy and in turn it would significantly decrease the rate of recurrence in anal abscess and fistula formation.

Key words: Abscess, anal fistula, anal gland, colorectal surgery, drainage

How to cite this article: Paydar S, Izadpanah A, Ghahramani L, Hosseini SV, Bananzadeh A, Rahimikazerooni S, Bahrami F. How the anal gland orifice could be found in anal abscess operations. *J Res Med Sci* 2015;20:22-5.

INTRODUCTION

Most anorectal abscesses are caused by cryptoglandular infection.^[1,2] Incision and drainage (I and D) alone, only drains the abscess and does not eliminate the primary cause. I and D alone has been advocated because this technique is simple, quick and associated with little morbidity. However, there is a 30% risk of recurrence of an abscess and a 40-50% risk of subsequent anal fistula with this technique.^[3,4] Many studies showed lower chance of abscess recurrence and fistula if surgeon could totally destroy the causative anal gland.^[5-7]

What remains controversial is whether this primary fistulotomy and elimination of the culprit anal gland could be performed at the time of initial abscess drainage or not? Opponents are reluctant to perform primary fistulotomy in the presence of acute inflammation, because searching for the internal orifice may lead to the creation of a false passage and deviation from the main source of infection.

Conventional method to seek the internal orifice is through direct visualization by insertion of an anal speculum and applying pressure on the abscess and/or insertion of a clamp into the abscess cavity from the incision on it. This could demonstrate the internal opening only in a small percentage of cases and increase the risk of false pathway formation and the following adverse outcomes.

Once the challenge of finding the internal orifice is solved, primary fistulotomy may become a more suitable way to treat anal abscesses in one stage by lowering the rate of abscess recurrence and fistula formation. Therefore, we offered a new method in finding the internal orifice of anal abscesses and conducted this study to assess the efficacy and results of this new technique.

MATERIALS AND METHODS

Participants

In this cross-sectional descriptive study, in Shiraz, Shahid Faghihi Hospital, from September 2008 to

Address for correspondence: Dr. Ahmad Izadpanah, Colorectal Research Center, Shiraz University of Medical Sciences, Shiraz, Iran.
E-mail: izadpana@sums.ac.ir

Received: 24-08-2013; **Revised:** 10-11-2013; **Accepted:** 29-10-2014

September 2010, 90 patients with solitary anal abscess that presented with painful swelling around anal verge were recruited after getting appropriate consents. Patients with Crohn's disease, immunocompromised status, age >70 and concurrent other anal problems such as gas or stool incontinence were omitted from the study.

Methods

All the remaining 77 patients, under general anesthesia and in a lithotomy or prone Jack-knife position, a speculum was inserted in the anal canal and the internal orifice was sought by direct visualization, whereas mild pressure was applied over the bulging to observe pus drainage from the internal opening. In 28 of patients, the internal opening was identified while in the other 49 ones it was not found. In these 49 cases abscess cavity was confirmed by aspirating its content and then 1-2 CC of a solution prepared with few drops of methylene blue in diluted hydrogen peroxide (2%) was injected into the abscess cavity and anal canal was being inspected through the speculum to find out the internal orifice [Figure 1]. Release of O₂ would increase intra-cavitary pressure, and

the anal gland orifice, which is the weakest point of the abscess wall may be revealed [Figures 2 and 3]. Once the internal orifice was found, an incision made on the nearest point to the anal verge by which the abscess cavity was evacuated [Figure 4]. Then, Lockhart-Mummery probe was inserted from the site of the incision and passed through the internal opening located in the dentate line. The bulk of tissue above the probe consisting of skin and superficial part of internal sphincter was transected by electrocautery (primary fistulotomy). Irrigation of the cavity was done with normal saline, and the wound was left open. In five cases of not finding the internal opening, traditional I and D alone was performed.

No packing was used. Antibiotics were administered in diabetic patients, those with history of chills/fever or cellulitis around the abscess cavity and patients having prosthetic valve.

Patients were followed weekly for 1-month, then once every 3 months for persistent fistula, recurrence of abscess and anal incontinence.

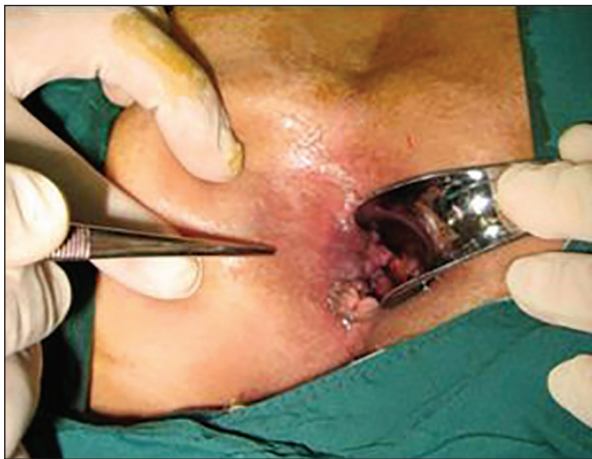

Figure 1: Superficial preanal abscess

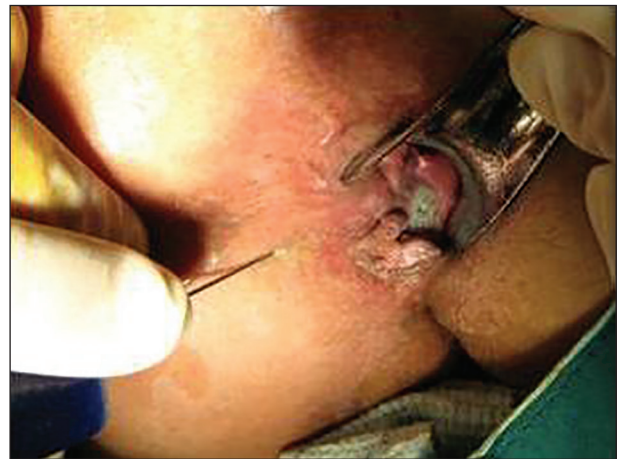

Figure 2: Finding of internal orifice

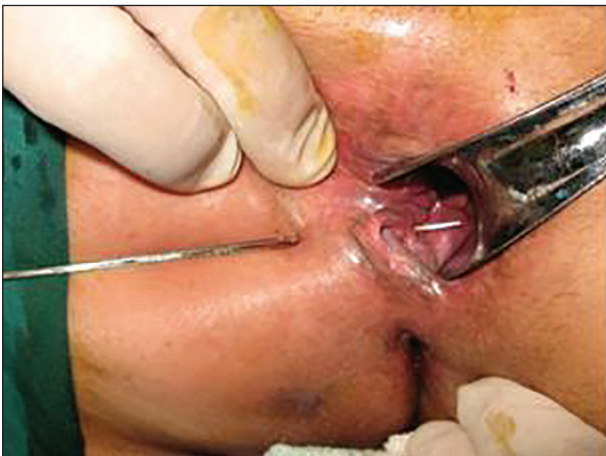

Figure 3: Probing throughout the orifice

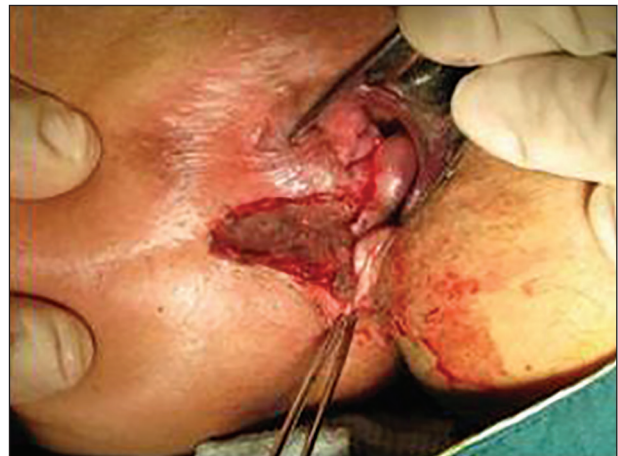

Figure 4: Laying open the abscess cavity

Statistics

Percentages are compared using Chi-square test and $P < 0.05$ is considered as significant.

RESULTS

Forty-seven patients (61%) were man and 30 women (39%), with the mean age of 42 years old (± 9). In 28 patients (36.3%) the conventional method of applying pressure on the bulging site resulted in direct visualization of the internal opening of the abscess. In the remaining 49 patients (65.7%), the internal opening was not found using this technique. The solution of diluted hydrogen peroxide 2% and methylene blue dye was injected into the abscess cavity, which resulted in the identification of the internal opening in 44 out of 49 (90%), patients [Figure 5]. The internal openings of those abscesses found by pressure over the bulging were also confirmed via injection of the above solution injection. All patients were admitted to the postoperative ward for 48-72 h, with the average of 52 h. In fact, these 72 patients are as though operated with primary fistulotomy.

On clinical follow-up, 4 patients from the first group (14.28%) and 9 (20.45%) cases from the second group complained from gas incontinence on the first visit. Fortunately, they were treated after the 3rd week following operation. No problem was noticed in the process of wound healing. On the 15-18th months of follow-up, with the mean of 16.5 months, 2 of the 72 (2.8%) patients who underwent primary fistulotomy, developed anal fistula. However, 2 of 5 patients (40%) for whom I and D alone was done, presented with a recurrence of anal abscess and fistula on the 3rd-7th months.

DISCUSSION

The safety and long-term effectiveness of primary fistulotomy in anal abscess have been established well in the past four decades. As early as 1969, McElwain *et al.*^[6] reported a clinical study of 500 patients who underwent primary fistulotomy for anorectal abscess. Since then, other large series have shown that primary fistulotomy not only is safe, but also significantly reduces the incidence of recurrence of an abscess and subsequent fistula formation.^[7-9]

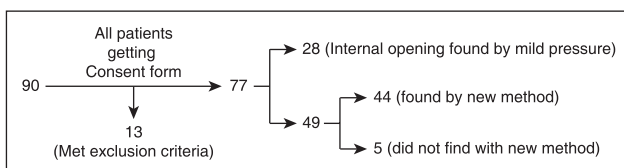


Figure 5: Number of patients in different groups of study

Opponents of the fistulotomy of anal abscess in the acute phase, criticize the procedure due to the high probability of erroneous passage of the probe in the fistula tract and creation of a false root. In Read's report (1979) the failure rate of finding the internal opening by traditional methods reaches 66%.^[8] Internal openings are demonstrated in only 10-34.7% of primary anorectal abscesses in most series^[3,9-14] This report is in concordance with our failure rate in finding internal orifice by the same method.

Using the solution of hydrogen peroxide (2%) solution and methylene blue, as a new method to detect internal opening of anal abscess, can probably solve the above-mentioned challenge. In our study, conventional method of applying pressure over the bulging abscess resulted in finding the internal opening in 28 patients (36.6%), at the same time 90% of the remaining cases were treated by the solution injection technique. We failed to find an opening by either of the methods in 5 patients, three of which reported a recent anal procedure, including closed hemorrhoidectomy and lateral internal sphincterotomy.

In terms of transient gas incontinence following fistulotomy, there was no significant difference between two groups, and all the patients recovered within 3-4 weeks. Our result is in concordance with many other studies. For example, Ho *et al.* reported no clinical or manometrical incontinence in his patients^[3] compared with Schouten and van Vroonhoven, who reported the rate of continence disturbances in a prospective, randomized trial.^[5]

In this study, the rate of recurrence of abscess was 40% in patients who underwent I and D alone, and 2.8% in all patients (one patient from the traditional group and one from the new method group). Our result is similar to many other studies such as those performed by Lunniss and Phillips,^[15] and Ho *et al.*^[3]

CONCLUSION

Our technique to find the internal opening of anal abscesses by injecting a solution of hydrogen peroxide (2%) and methylene blue to the abscess cavity is a safe and successful alternative to conventional external pressure method. After identification of the internal orifice, fistulotomy with the same procedure is recommended for these patients. However, studies with larger scales and with longer follow-up are demanded.

ACKNOWLEDGMENTS

This study has been accepted under code 3061. The authors would like to thank the research vice-chancellor of Shiraz University of Medical Sciences for financially supporting the study.

AUTHOR'S CONTRIBUTION

AI contributed in the conception of the work, conducting the study, revising the draft, approval of the final version of the manuscript, statistical Analysis and agreed for all aspects of the work. SVH contributed in the conception of the work, drafting and revising the draft, approval of the final version of the manuscript, and agreed for all aspects of the work. ShP contributed in the conception of the work, conducting the study, revising the draft, approval of the final version of the manuscript, and agreed for all aspects of the work. LG contributed in the conception of the work, revising the draft, approval of the final version of the manuscript, and agreed for all aspects of the work. AB contributed in the conception of the work, conducting the study, revising the draft, approval of the final version of the manuscript, statistical Analysis and agreed for all aspects of the work. SR contributed in the conception of the work, revising the draft, approval of the final version of the manuscript, statistical Analysis and agreed for all aspects of the work. FB contributed in the conception of the work, revising the draft, approval of the final version of the manuscript, statistical Analysis and agreed for all aspects of the work.

REFERENCES

- Eisenhammer S. The anorectal and anovulval fistulous abscess. *Surg Gynecol Obstet* 1961;113:519-20.
- Eisenhammer S. The internal anal sphincter and the anorectal abscess. *Surg Gynecol Obstet* 1956;103:501-6.
- Ho YH, Tan M, Chui CH, Leong A, Eu KW, Seow-Choen F. Randomized controlled trial of primary fistulotomy with drainage alone for perianal abscesses. *Dis Colon Rectum* 1997;40:1435-8.
- Whiteford MH, Kilkenny J 3rd, Hyman N, Buie WD, Cohen J, Orsay C, *et al.* Practice parameters for the treatment of perianal abscess and fistula-in-ano (revised). *Dis Colon Rectum* 2005;48:1337-42.
- Schouten WR, van Vroonhoven TJ. Treatment of anorectal abscess with or without primary fistulectomy. Results of a prospective randomized trial. *Dis Colon Rectum* 1991;34:60-3.
- McElwain JW, Alexander RM, MacLean MD. Primary fistulectomy for anorectal abscess: Clinical study of 500 cases. *Dis Colon Rectum* 1966;9:181-5.
- Quah HM, Tang CL, Eu KW, Chan SY, Samuel M. Meta-analysis of randomized clinical trials comparing drainage alone vs primary sphincter-cutting procedures for anorectal abscess-fistula. *Int J Colorectal Dis* 2006;21:602-9.
- Read DR, Abcarian H. A prospective survey of 474 patients with anorectal abscess. *Dis Colon Rectum* 1979;22:566-8.
- Ramanujam PS, Prasad ML, Abcarian H, Tan AB. Perianal abscesses and fistulas. A study of 1023 patients. *Dis Colon Rectum* 1984;27:593-7.
- Oliver I, Lacueva FJ, Pérez Vicente F, Arroyo A, Ferrer R, Cansado P, *et al.* Randomized clinical trial comparing simple drainage of anorectal abscess with and without fistula track treatment. *Int J Colorectal Dis* 2003;18:107-10.
- Hebjorn M, Olsen O, Haakansson T, Andersen B. A randomized trial of fistula in anal abscess. *Scand J Gastroenterol* 1987;22:174-7.
- Eisenhammer S. The final evaluation and classification of the surgical treatment of the primary anorectal cryptoglandular intermuscular (intersphincteric) fistulous abscess and fistula. *Dis Colon Rectum* 1978;21:237-54.
- Henrichsen S, Christiansen J. Incidence of fistula-in-ano complicating anorectal sepsis: A prospective study. *Br J Surg* 1986;73:371-2.
- Seow-Choen F, Leong AF, Goh HS. Results of a policy of selective immediate fistulotomy for primary anal abscess. *Aust N Z J Surg* 1993;63:485-9.
- Lunniss PJ, Phillips RK. Surgical assessment of acute anorectal sepsis is a better predictor of fistula than microbiological analysis. *Br J Surg* 1994;81:368-9.

Source of Support: Nil, **Conflict of Interest:** No conflict of interests.