

CASE SERIES

Hepatic transarterial chemoembolization and retroperitoneal lymph node radiofrequency ablation in the multidisciplinary approach of an overt metastatic leiomyosarcoma

Luiz Henrique de Lima Araujo^{a,b}, Hugo Rodrigues Gouveia^b, Emilson de Queiroz Freitas^b, Felipe Vilela Pedras^c, José Hugo Mendes Luz^b

^a*Clínicas Oncológicas Integradas (COI) and Instituto COI (ICOI), Rio de Janeiro, Brazil;* ^b*Instituto Nacional de Câncer (INCA), Rio de Janeiro, Brazil;* ^c*Clínica Radiológica Luis Felipe Mattoso, Rio de Janeiro, Brazil*

Corresponding address: Luiz Henrique de Lima Araujo, MD, MSc, Instituto COI de Educação e Pesquisa, Av. das Américas, 6.205, Loja E, Barra da Tijuca, Rio de Janeiro, CEP 22793-080, Brazil.

Email: luizaraujo@coinet.com.br

Date accepted for publication 4 February 2013

Abstract

Metastatic leiomyosarcoma has a dismal prognosis, and therapy mainly consists of palliative systemic chemotherapy. A selected subgroup of patients with limited metastatic disease may eventually derive benefit from more aggressive strategies, including resection of isolated metastasis. We report here the successful use of hepatic transarterial chemoembolization and retroperitoneal lymph node radiofrequency ablation in a patient with advanced leiomyosarcoma metastatic to the liver and retroperitoneum.

Keywords: *Chemoembolization; liver metastasis; ablation; sarcoma.*

Introduction

Metastatic leiomyosarcoma is associated with a dismal prognosis^[1]. Palliative systemic chemotherapy is the cornerstone, with response rates of 20–30% and median overall survival generally lower than 12 months^[2]. In this setting, a subgroup of patients with limited metastatic disease may derive benefit from more aggressive, multidisciplinary strategies^[2]. For instance, patients undergoing complete resection of pulmonary metastases may achieve a median survival of 19–33 months, which was significantly better than the results accomplished with systemic chemotherapy alone^[3–7]. However, selected patients with overt metastatic disease may also be treated with intensive approaches, as illustrated here.

Case report

A 47-year-old woman presented with a 1-month complaint of a painless mass in the neck. The patient was at performance status (PS) of 1, had no weight loss, and

her medical records included a previous hysterectomy due to uterine myomas, and prosthetic breast implants. At the physical examination, a complex of enlarged lymph nodes measuring 3.5 × 2.7 cm was noted in the right supraclavicular fossa. The cervical mass was totally resected in December 2011 and histopathologic examination confirmed the diagnosis of metastatic, well-differentiated leiomyosarcoma, with immunopositivity for vimentin, desmin, HHF-35, CD68, and immunonegativity for CD34 and S100. Positron emission tomography (PET)/computed tomography (CT) was performed for staging (Fig. 1), and multiple hypodense hepatic lesions were detected, the most avid located in segments VIII (maximum standardized uptake value SUV_{max} of 9.3), IV (SUV_{max} 5.4), and VI (SUV_{max} 7.1). A retroperitoneal mass measuring 5.1 × 4.7 cm, located near the inferior pole of the right kidney (SUV_{max} 8.6) was also noted, suggesting a conglomerate of metastatic lymph nodes (Fig. 2).

She was started on systemic chemotherapy with doxorubicin 20 mg/m² on days 1–3, and ifosfamide 1500 mg/

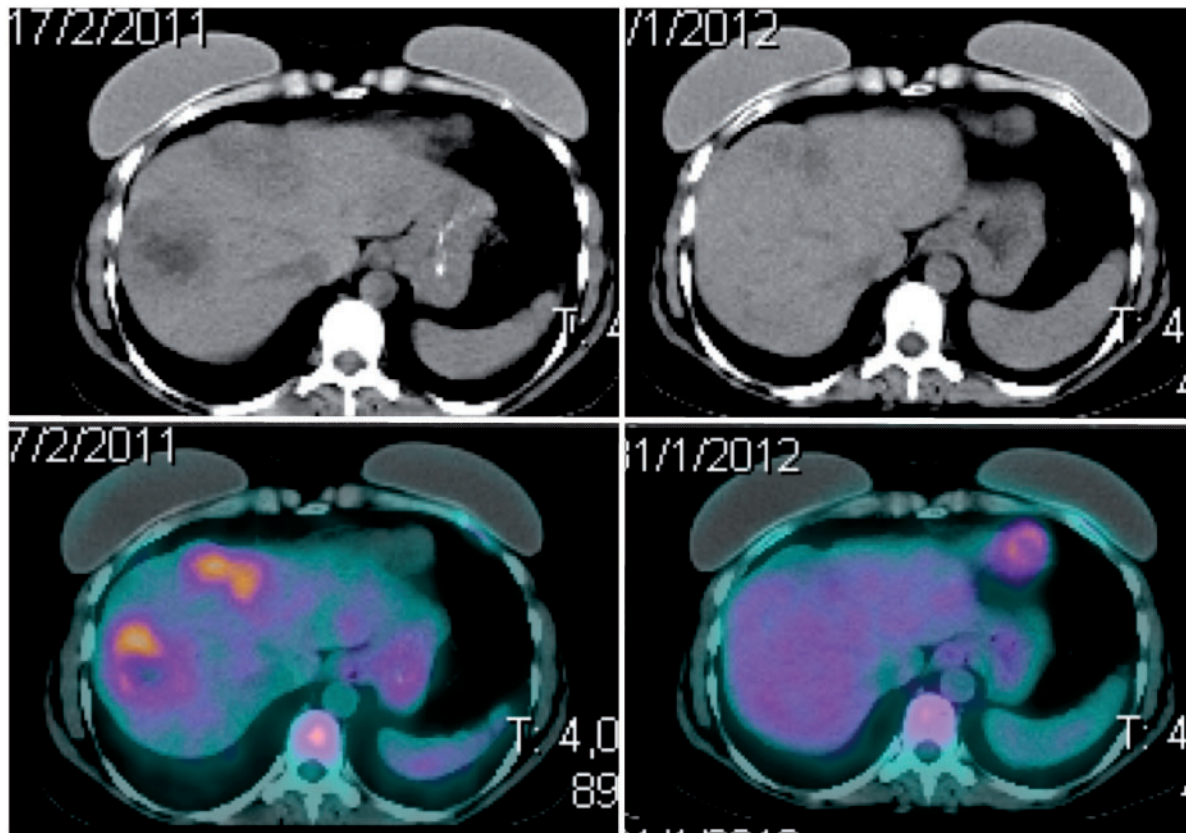


Figure 1 Morphologic (top) and metabolic (bottom) evolution of the liver metastasis before (left) and after (right) treatment, including chemotherapy and TACE.

m² on days 1–4, both intravenously, every 3 weeks. Primary prophylaxis was used for febrile neutropenia with 5 days of filgrastim, 300 µg/day as subcutaneous injection. After 5 cycles, an abdominopelvic CT scan revealed partial response in the liver and in the retroperitoneum, and further therapeutic options were discussed with the patient, and in a multidisciplinary setting. Given the severity of the metastatic disease to the liver, hepatic transarterial chemoembolization (TACE) was recommended to achieve better local control. The first TACE infusion was carried out in July 2011 using 150 mg of doxorubicin divided into 2 vials of drug-eluting beads (DC-Beads, Terumo). A superselective approach with coaxial microcatheters (Progreat, Terumo) was adopted to enable both hepatic lobes to be targeted during the same procedure. The patient had mild to moderate acute toxicities, including grade 2 nausea, vomiting, and fatigue. One month later, an abdominopelvic CT demonstrated a major response in all hepatic lesions (Fig. 3), and most of them became avascular after contrast enhancement, suggesting necrotic transformation.

At this time, the retroperitoneal mass was the only site of active disease, and a partial response was maintained, measuring 3.0 × 2.3 cm. Hence, CT-guided percutaneous radiofrequency ablation (RFA) was indicated in October 2011. During this procedure, under sedation, a cooled saline infusion catheter was placed in the right ureter

to avoid RFA damage, because of its proximity to the retroperitoneal lymph node mass. For the same reason, a prophylactic double J stent was inserted at the end of the procedure. For the RFA, the prone position was used, and the probe was placed under CT guidance. The procedure was performed using 15-cm Cool-Tip electrodes (Valleylab) with 3-cm active tips. Energy was delivered to reach tissue temperatures higher than 70°C for a nearly 10-min ablation cycle. Subsequently, the probe was repositioned and a second cycle was performed using the same protocol. Technical success was immediately confirmed with the demonstration of no tumor enhancement on a contrast CT scan. In the immediate post-operative period, an uncomplicated urinary infection was diagnosed, which was effectively treated with intravenous antibiotics (ciprofloxacin 400 mg every 12 h).

During surveillance, PET/CT was repeated in January 2012 (Figs. 1 and 2), and complete morphologic and metabolic responses were observed, both in the liver and in the retroperitoneum. Only a mild residual fluorodeoxyglucose uptake (SUV_{max} 2.1) was observed in the medial aspect of the retroperitoneal lymph node, which was not considered qualitatively significant. Even though PET was totally negative, 2 more TACE infusions were recommended because the abdominal CT scan still showed very slight enhancement in some hepatic lesions. The same protocol used in the first session was followed

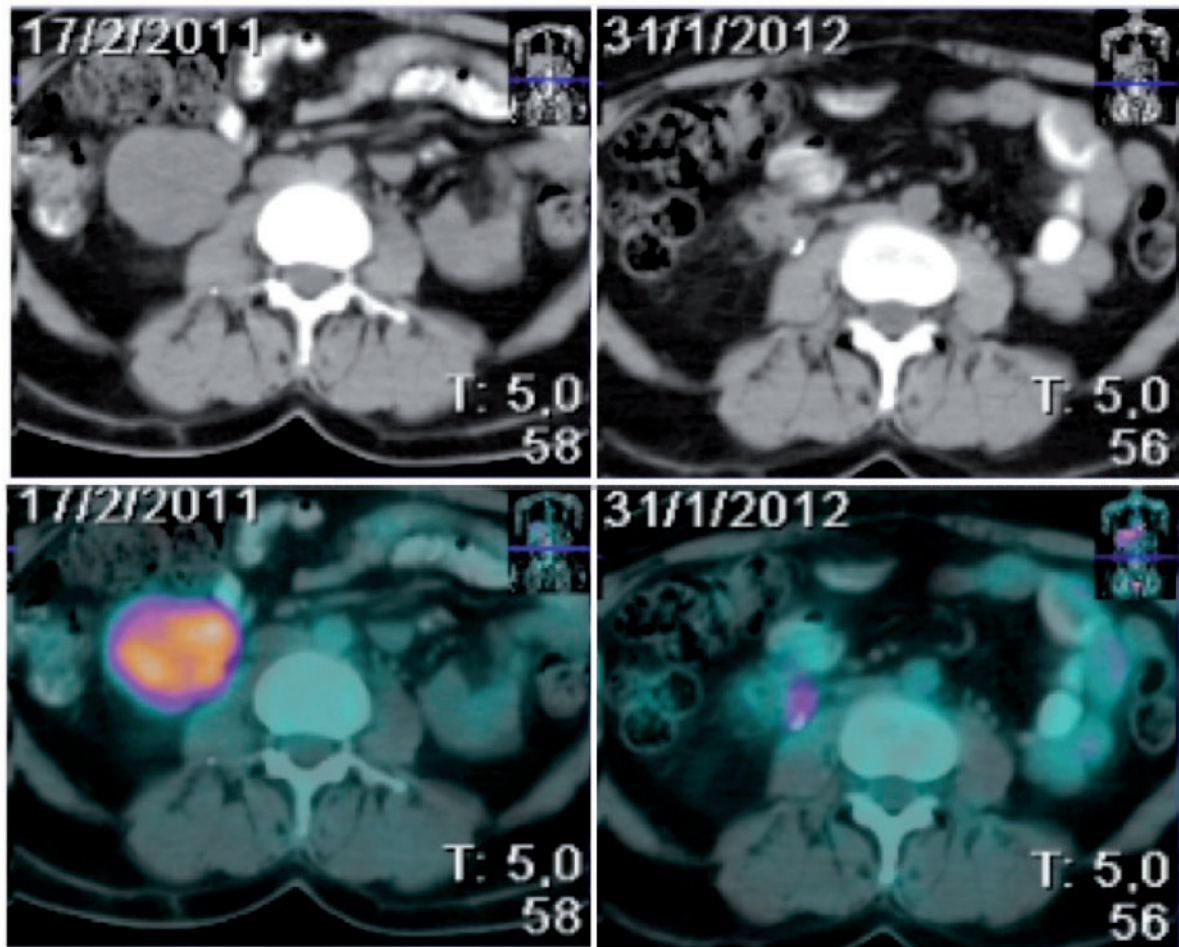


Figure 2 Morphologic (top) and metabolic (bottom) evolution of the retroperitoneal mass before (left) and after (right) treatment, including chemotherapy and tumor ablation. Although mild residual fluorodeoxyglucose uptake (SUV_{max} 2.1) was observed in the medial aspect of the node after treatment, this finding was not considered qualitatively significant.

in the subsequent infusions, with a 3-month interval between each. No further systemic chemotherapy was recommended. The patient currently remains at PS 0, with great quality of life, and without evidence of disease activity after 18 months from the diagnoses. The surveillance includes monthly visits and CT scans every 3 months.

Discussion

TACE is an established procedure for the treatment of patients with primary and metastatic liver tumors; it enables a high chemotherapy delivery despite a low systemic toxicity profile, achieving robust tumor control in selected cases.⁸ Therefore, diffuse or unresectable metastatic disease to the liver may still be effectively controlled^[8]. The use of TACE in metastatic sarcomas is only rarely mentioned in the literature, although favorable responses have been reported^[9,10]. In the present case, complete morphologic and metabolic responses

were obtained after a first TACE infusion, corroborating its effectiveness in this context. RFA is a method of thermal ablation mostly used for small tumors (ideally <3 cm), especially in the liver^[11]. In well-differentiated sarcomas, RFA has been used to treat pulmonary metastases in patients who are suboptimal surgical candidates. The outcomes with this strategy may approach those reported with pulmonary metastasectomy, especially when complete ablation is accomplished^[12,13]. However, a wider range of indications has been suggested, including ablation of retroperitoneal masses^[11]. In the reported case, a complete response was achieved in the retroperitoneal lymph node conglomerate, which was confirmed at a post-therapy PET/CT.

The outcomes achieved here illustrate the importance of a multidisciplinary approach in metastatic leiomyosarcomas. Moreover, aggressive therapies including TACE and RFA should be considered in fit patients, where tumor response to induction chemotherapy might be a reasonable selection factor.

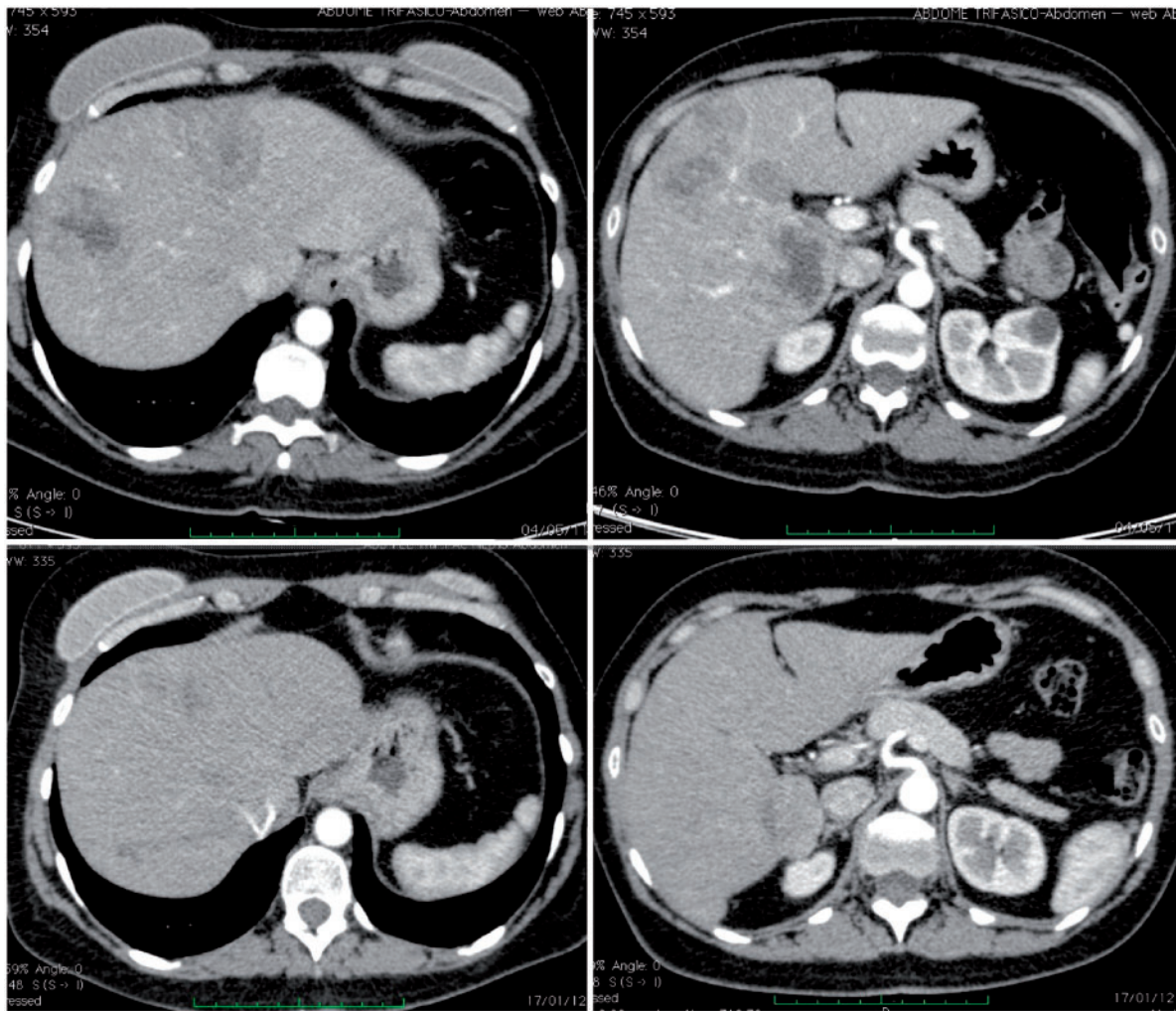


Figure 3 Abdominal contrast-enhanced CT before (top) and after (bottom) the first hepatic TACE procedure, showing a robust response in the metastatic hepatic lesions during the arterial phase.

Conflict of interest

The authors report no conflicts of interest.

References

- [1] Movva S, Verschraegen C. Systemic management strategies for metastatic soft tissue sarcoma. *Drugs* 2011; 71: 2115–2129. doi:10.2165/11594500-000000000-00000. PMID:22035513.
- [2] D'Adamo DR. Appraising the current role of chemotherapy for the treatment of sarcoma. *Semin Oncol* 2011; 38: S19–29.
- [3] Smith R, Pak Y, Kraybill W, et al. Factors associated with actual long-term survival following soft tissue sarcoma pulmonary metastasectomy. *Eur J Surg Oncol* 2009; 35: 356–361. doi:10.1016/j.ejso.2008.01.004. PMID:18294807.
- [4] The International Registry of Lung Metastases. Long-term results of lung metastasectomy: prognostic analyses based on 5206 cases. *J Thorac Cardiovasc Surg* 1997; 113: 37–49. doi:10.1016/S0022-5223(97)70397-0. PMID:9011700.
- [5] Blackmon SH, Shah N, Roth JA, et al. Resection of pulmonary and extrapulmonary sarcomatous metastases is associated with long-term survival. *Ann Thorac Surg* 2009; 88: 877–884; discussion: 884–885. doi:10.1016/j.athoracsur.2009.04.144. PMID:19699915.
- [6] Garcia Franco CE, Algarra SM, Ezcurra AT, et al. Long-term results after resection for soft tissue sarcoma pulmonary metastases. *Interact Cardiovasc Thorac Surg* 2009; 9: 223–226. doi:10.1510/icvts.2009.204818. PMID:19454417.
- [7] Weiser MR, Downey RJ, Leung DH, et al. Repeat resection of pulmonary metastases in patients with soft-tissue sarcoma. *J Am Coll Surg* 2000; 191: 184–190; discussion: 190–191. doi:10.1016/S1072-7515(00)00306-9. PMID:10945362.
- [8] Lewandowski RJ, Geschwind JF, Liapi E, Salem R. Transcatheter intraarterial therapies: rationale and overview. *Radiology* 2011; 259: 641–657. doi:10.1148/radiol.11081489. PMID:21602502.
- [9] Rajan DK, Sulen MC, Clark TW, et al. Sarcomas metastatic to the liver: response and survival after cisplatin, doxorubicin, mitomycin-C, ethiodol, and polyvinyl alcohol chemoembolization. *J Vasc Interv Radiol* 2001; 12: 187–193. doi:10.1016/S1051-0443(07)61824-7. PMID:11265882.
- [10] Mavligit GM, Zukiwski AA, Salem PA, Lamki L, Wallace S. Regression of hepatic metastases from gastrointestinal leiomyosarcoma after hepatic arterial chemoembolization. *Cancer* 1991; 68: 321–323. doi:10.1002/1097-0142(19910715)68:2<321::AID-CNCR2820680219>3.0.CO;2-B. PMID:2070331.

- [11] Prunoiu V, Cirimei C, Marincas M, Cirimbei S, Bratucu E. Extending indication for radiofrequency ablation (RFA) in cancer surgery. *Chirurgia (Bucur)* 2011; 106: 585–589.
- [12] Nakamura T, Matsumine A, Yamakado K, et al. Lung radiofrequency ablation in patients with pulmonary metastases from musculoskeletal sarcomas. *Cancer* 2009; 115: 3774–3781. doi:10.1002/cncr.24420. PMID:19514086.
- [13] Ketchedian A, Daly B, Luketich J, et al. Minimally invasive techniques for managing pulmonary metastases: video-assisted thoracic surgery and radiofrequency ablation. *Thorac Surg Clin* 2006; 16: 157–165. doi:10.1016/j.thorsurg.2005.11.002. PMID:16805205.