

Two Ocular Infections during Conventional Chemotherapy in a Patient with Acute Lymphoblastic Leukemia: A Case Report

Ruba Taha^a Ibrahim Al Hijji^a Halima El Omri^a
Fareed Al-Laftah^b Riham Negm^a Mohammed Yassin^a
Hanadi El Ayoubi^a

^aDepartment of Hematology and Medical Oncology, Al Amal Hospital, Hamad Medical Corporation, and ^bDepartment of Ophthalmology, Hamad Medical Corporation, Doha, Qatar

Key Words

Cytomegalovirus retinitis · Acute lymphoblastic leukemia · Chemotherapy · Hyper-CVAD · Candida

Abstract

Viral retinitis due to cytomegalovirus (CMV) infection is rare in patients with acute leukemia who did not receive hematopoietic stem cell transplantation. We report a case of CMV retinitis that developed in a 49-year-old patient with acute lymphoblastic leukemia. The patient was treated with salvage chemotherapy using a hyper-CVAD regimen and did not receive hematopoietic stem cell transplantation. The incidence of CMV retinitis in this subgroup of patients is not described in literature. He had a very complicated course during chemotherapy but was successfully treated, with preservation of visual acuity, and to date he is in complete remission. Interestingly, prior to CMV retinitis, the patient had been diagnosed with and treated for candida retinitis. This case shows the importance of eye examination and care in patients diagnosed with hematological malignancies.

Introduction

Cytomegalovirus (CMV) or human herpesvirus 5 is a well-known cause of opportunistic infection in immunocompromised patients; the infection is especially

Dr. Ruba Taha

Department of Hematology and Bone Marrow Transplant
Al Amal Hospital, Hamad Medical Corporation HMC
PO Box 3050
Doha (Qatar)
Tel. +974 439 7895, Fax +974 4397857, E-Mail rubataha@yahoo.com, rtaha@hmc.org.qa

known in patients with acquired immunodeficiency syndrome (AIDS), organ transplantations and hematological malignancies. It is particularly serious after solid organ transplantation or allogenic hematopoietic stem cell transplantation (HSCT). Without prophylaxis, 8–39% of solid organ transplantation and 20–35% of allogenic HSCT recipients develop CMV infection [1]. In the eye, CMV presents as a necrotizing retinitis with a characteristic ophthalmoscopic appearance; it is usually unilateral, but if left untreated, it may progress to the contralateral eye and result in complete visual loss. CMV retinitis usually occurs as a result of hematogenous spread of the virus to the retina after systemic reactivation of a latent infection and usually in patients with severe deficiency of cell-mediated immunity. CMV retinitis has rarely been described in medical literature in settings of acute leukemia without autologous or allogenic HSCT. Here we present a case report of a patient with acute lymphoblastic leukemia who developed 2 different ocular infections during treatment: fungal retinitis in the right eye during induction chemotherapy and CMV retinitis during consolidation chemotherapy.

Case Report

A 49-year-old gentleman from Iraq, a known carrier of the β -thalassemia trait, presented on March 2007 with fever and symptomatic anemia. Complete blood count (CBC) showed pancytopenia, white blood cell (WBC) count was $3.2 \times 10^3/\mu\text{l}$, hemoglobin (Hb) 5.8 g/dl, mean corpuscular volume (MCV) 60.7 fl, platelets (PLT) $46 \times 10^3/\mu\text{l}$, neutrophils $1.0 \times 10^3/\mu\text{l}$ and lymphocyte count $2.1 \times 10^3/\mu\text{l}$. Peripheral smear was unremarkable apart from microcytic hypochromic anemia and absolute neutropenia. Bone marrow aspiration and biopsy showed hypercellular marrow with 95% of nucleated cells being blasts of lymphoid features. Immunophenotyping confirmed the diagnosis of B-cell common acute lymphoblastic leukemia (ALL). Karyotype was normal. Molecular studies were not available. Cerebrospinal fluid was not involved. Coagulation, kidney and liver functions were normal. Autoimmune screen was negative. Serologies for hepatitis B, C and human immunodeficiency virus (HIV) were negative. Viral serology was positive for CMV IgG 2,000 IU/ml and toxoplasma IgG 7.5 IU/ml. Chest X-ray and abdominal ultrasound were normal. Echocardiography was normal and the ejection fraction was 55% (55–70). We started induction chemotherapy using the German ALL protocol (prednisolone, cyclophosphamide, vincristine, doxorubicin, L-asparaginase) through a Hickman line. During induction, the patient developed severe mucositis grade IV and prolonged neutropenia less than $0.2 \times 10^3/\mu\text{l}$ for which he was receiving multiple blood and PLT transfusions. He also had febrile neutropenia which was treated empirically with intravenous meropenem and vancomycin. His blood culture grew *Candida albicans*; therefore, caspofungin was added and the central line was removed. After 2 weeks on these antimicrobials, the patient still had a fever. A workup to exclude secondary candida foci was done, included echocardiography, which showed no vegetations, and imaging of the chest and abdomen which was normal. A retinal examination was performed by the ophthalmologist and showed left-sided focal retinitis superotemporal to the macula sparing visual acuity, most likely secondary to candida infection. There were no satellite lesions and no vitritis (fig. 1). Caspofungin was replaced with intravenous amphotericin B for a better ocular penetration and 2 weeks later the retinitis healed leaving a scar (fig. 2). The patient achieved hematological remission; however, he developed severe hepatic impairment and progressed to fulminant hepatic failure. Liver biopsy suggested a drug-induced etiology and confirmed absence of fungal deposits. He received maximum supportive care till complete normalization of the liver function. L-asparaginase was presumed the most likely agent to have caused the hepatic toxicity; therefore, we shifted the patient to a hyper-CVAD regimen (course A: dexamethasone, vincristine, doxorubicin alternating with course B: high-dose methotrexate and high-dose cytarabine). After the 4th course of hyper-CVAD the patient reported a decrease in vision in the opposite eye (left side) with floaters. His visual acuity reduced from normal to 6/24 in the left eye (best corrected) and remained normal in the right eye. There was no afferent pupillary defect. Fundus showed active hemorrhagic retinitis suggestive of CMV infection more in the left eye (fig. 3). The plasma CMV polymerase chain reaction (PCR) was 15 copies and continued to rise till 138 copies. The patient was started on intravenous ganciclovir 5 mg/kg b.i.d. for 3 weeks followed by maintenance with oral valganciclovir 900 mg b.i.d. for 2 months. His visual acuity improved to 6/9 in the left eye and retinitis resolved (fig. 4). During the 5th course of hyper-CVAD (October 2007), the patient had a sudden headache and progressed rapidly to coma. Computer tomography of the brain showed a large subdural hemorrhage with midline shift. Urgent surgical evacuation was done. This resulted in the patient

regaining full consciousness. However, he sustained residual right-sided spastic hemiparesis and started an intensive rehabilitation program including speech therapy, physiotherapy and occupational therapy.

Maintenance chemotherapy was started on February 2008 with 6-mercaptopurine 60 mg/m² daily and methotrexate 20 mg/m² weekly. At the 24-month follow-up (February 2010), CBC was normal with WBC $6.6 \times 10^3/\mu\text{l}$, absolute neutrophil count (ANC) $4.3 \times 10^3/\mu\text{l}$, Hb 11.9 g/dl and PLT $315 \times 10^3/\mu\text{l}$. The patient was in complete remission with fair neurological recovery and stable visual acuity.

Discussion

The retinal involvement in acute leukemia may be of different causes like direct leukemic infiltrates, or secondary to vitreous and retinal hemorrhage caused by anemia, thrombocytopenia or hyperviscosity [2, 3]. Patients with acute leukemia are also susceptible to opportunistic – particularly viral, protozoal and fungal – infections that may involve the retina, especially during the periods of neutropenia, [3]. *Candida* infection is among the common infections in this subset of patients; when it involves the retina, it typically appears as focal, deep white lesions that can be singular or multiple. It may extend into the vitreous and cause vitritis and endophthalmitis. The rate of developing chorioretinitis in patients with candidemia has reduced markedly since the 1990's due to the early identification of candidemia in blood cultures coupled with a trend of early empiric antifungal therapy. The risk of ocular involvement is increased with *Candida albicans* compared with other candida species, as well as in multiple positive blood cultures or in the immunosuppressed states [4]. Cytomegalovirus infection is also among the common viral infections in the immunocompromised hosts. However, the prevalence of CMV antigenemia and disease in patients with hematological malignancies who are not transplant recipients or HIV infected is largely unknown and is thought to be low [5–8]. One retrospective cohort by Han [9] looked into the incidence of CMV antigenemia in more than 2,000 patients with hematological malignancies who did not undergo autologous or allogenic stem cell transplantation. They were tested during the antineoplastic treatment. The antigenemia rate was 13.6% in lymphoid malignancies and 3.9% in myeloid malignancies. This suggests that CMV reactivation occurs primarily in situations of severe lymphoid disease. Another retrospective case series by Ng et al. [10] looked into the rate of CMV reactivation according to the type of therapy prior to CMV antigenemia in patients with hematological malignancies without HSCT. The series showed that the highest event rate was for alemtuzumab therapy 50%, 9.7% for the hyper-CVAD regimen, 4.6% for fludarabine-based regimens, 4.2% for autologous stem cell transplantation, and less than 1% for other conventional chemotherapy regimens. The lung and gastrointestinal tract were the main organs affected with CMV disease in this series.

The diagnosis of CMV end organ disease is most definitively made by the detection of CMV DNA or RNA in tissues by in situ hybridization. However, in cases of retinitis, retinal biopsy is not often recommended because of the high risk of retinal detachment. Accordingly, examining the intraocular fluid by PCR technique is the most specific mode for diagnosis [11]. The value of virus detection using blood culture or blood PCR may, on the other hand, have a strong correlation to the development of CMV retinitis as suggested by many studies in patients with AIDS [12, 13]. In our case, CMV retinitis was suggested by the typical ophthalmoscopic appearance of CMV hemorrhagic retinitis along with the concomitant rising of plasma CMV DNA by PCR and the remarkable improvement of retinal examination after resolution of the leucopenia and starting ganciclovir. Intraocular fluid sampling was not done because the patient was severely thrombocytopenic and had high a bleeding tendency in spite of PLT transfusions.

Possible factors that predisposed our patient for developing CMV retinitis are: the immunosuppression secondary to the disease itself and to the myeloablative chemotherapy of ALL that caused prolonged leukopenia. In addition, the high dose of steroids in the hyper-CVAD regimen aggravated the myelosuppression even more. The CMV infection in our patient may have developed due to the reactivation of the virus since the patient was seropositive for CMV before starting chemotherapy, or it may have been a new transmission from blood transfusions. The patient was HIV negative, so CD4 count was not done initially or during the chemotherapy, but it was definitely very low during the treatment since total WBC count was $0.1\text{--}0.4 \times 10^3/\mu\text{l}$. CD4 count was done after bone marrow recovery and was normal.

Conclusion

CMV retinitis is rare in patients with acute leukemia receiving conventional chemotherapy without HSCT, yet it can occur, particularly when the treatment includes a large dose of steroids like in the hyper-CVAD protocol. Moreover, ocular infections in this subgroup of patients can be asymptomatic. Therefore, an eye examination by an ophthalmologist, even in the absence of ocular symptoms, is of importance during the treatment of these patients.

Fig. 1. Color photograph of the right fundus showing focal hemorrhagic retinitis superotemporal to macula (candida retinitis).

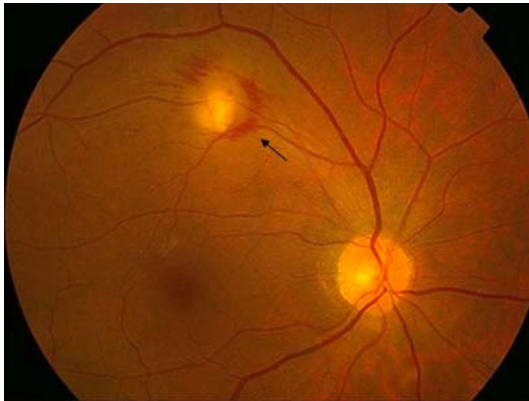

Fig. 2. Color photograph of the right fundus 2 weeks after starting intravenous amphotericin B: focal retinitis healed leaving a scar.

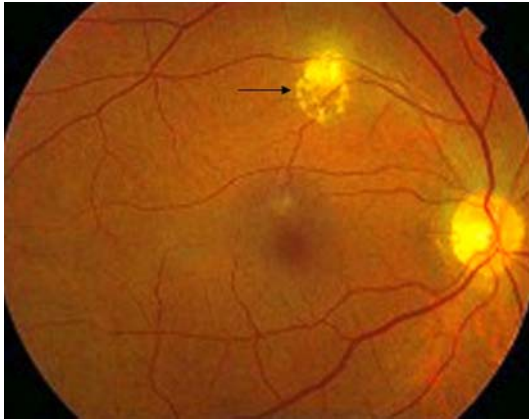


Fig. 3. Color photo of the left fundus showing white fluffy lesions in the temporal macula surrounding retinal vessels associated with hemorrhage (CMV retinitis).

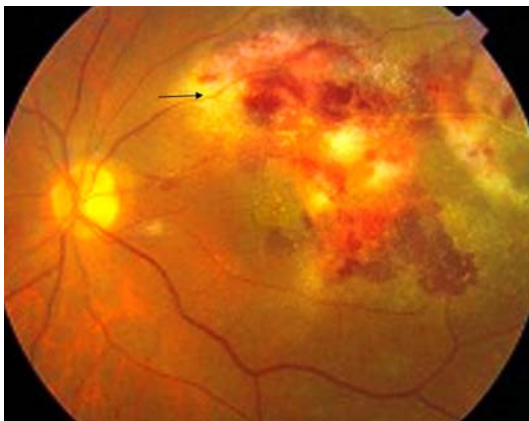
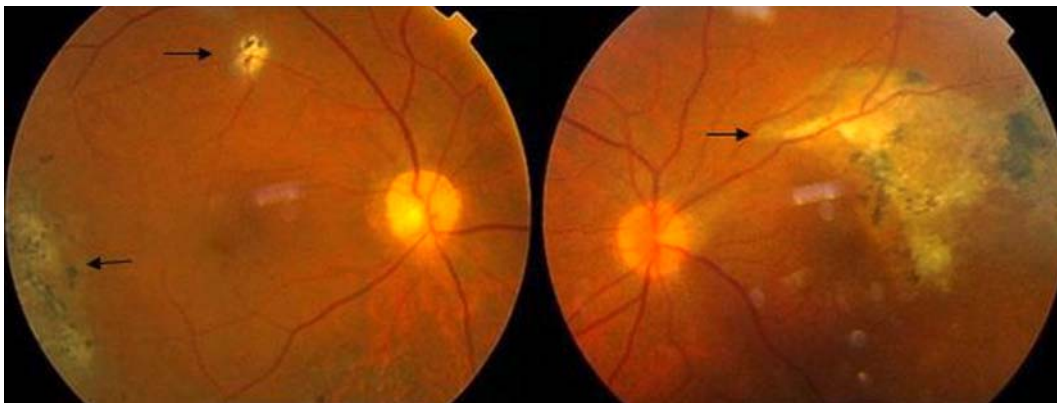


Fig. 4. Right and left fundi show healed retinal scars corresponding to the site of the previous retinitis (right fungal retinitis and bilateral CMV retinitis).



References

- 1 Nichols WG, Boeckh MJ: Recent advances in the therapy and prevention of CMV Infections. *J Clin Virol* 2000;16:25–40.
- 2 Reddy SC, Jackson N, Menon BS: Ocular involvement in leukemia – a study of 288 cases. *Ophthalmologica* 2003;217:441–445.
- 3 Sharma T, Grewal J, Gupta S, Murray PI: Ophthalmic manifestations of acute leukaemias: the ophthalmologist's role. *Eye* 2004;18:663–672.
- 4 Shah CP, McKey J, Spirn MJ, Maguire J: Ocular candidiasis: a review. *Br J Ophthalmol.* 2008;92:466–468.
- 5 Nguyen Q, Estey E, Raad I, Rolston K, Kantarjian H, Jacobson K, Konoplev S, Ghosh S, Luna M, Tarrand J, Whimbey E: Cytomegalovirus pneumonia in adults with leukemia: an emerging problem. *Clin Infect Dis* 2001;32:539–545.
- 6 Offidani M, Corvatta L, Olivieri A, Rupoli S, Frayfer J, Mele A, Manso E, Montanari M, Centurioni R, Leoni P: Infectious complications after autologous peripheral blood progenitor cell transplantation followed by G-CSF. *Bone Marrow Transplant* 1999;24:1079–1087.
- 7 Eddleston M, Peacock S, Juniper M, Warrell DA: Severe cytomegalovirus infection in immunocompetent patients. *Clin Infect Dis* 1997;24:52–56.
- 8 Kanno M, Chandrasekar PH, Bentley G, Vander Heide RS, Alangaden GJ: Disseminated cytomegalovirus disease in hosts without acquired immunodeficiency syndrome and without an organ transplant. *Clin Infect Dis* 2001;32:313–316.
- 9 Han XY: Epidemiologic analysis of reactivated cytomegalovirus antigenemia in patients with cancer. *J Clin Microbiol* 2007;45:1126–1132.
- 10 Ng AP, Worth L, Chen L, Seymour JF, Prince HM, Slavin M, Thursky K: Cytomegalovirus DNAemia and disease: incidence, natural history and management in settings other than allogeneic stem cell transplantation. *Haematologica* 2005;90:1672–1679.
- 11 Derzko-Dzulynsky LA, Berger AR, Berinstein NL: Cytomegalovirus retinitis and low-grade non-Hodgkin's lymphoma: case report and review of the literature. *Am J Hematol* 1998;57:228–232.
- 12 Hansen KK, Ricksten A, Hofmann B: Detection of cytomegalovirus DNA in serum correlates with clinical cytomegalovirus retinitis in AIDS. *J Infect Dis* 1994;170:1271–1274.
- 13 Rasmussen L, Morris S, Zipeto D: Quantitation of human cytomegalovirus DNA from peripheral blood cells of human immunodeficiency virus-infected patients could predict cytomegalovirus retinitis. *J Infect Dis* 1995;171:177–182.