

# The Magnitude of Hypotony and Time Course of Intraocular Pressure Recovery Following Anterior Chamber Cannulation in Nonhuman Primates

Jessica V. Jasien,<sup>1</sup> Carrie Huisingsh,<sup>2</sup> Christopher A. Girkin,<sup>2</sup> and J. Crawford Downs<sup>2</sup>

<sup>1</sup>Vision Science Graduate Program, School of Optometry, University of Alabama at Birmingham, Birmingham, Alabama, United States

<sup>2</sup>Department of Ophthalmology, School of Medicine, University of Alabama at Birmingham, Birmingham, Alabama, United States

Correspondence: J. Crawford Downs, Ocular Biomechanics and Mechanobiology Program, Department of Ophthalmology, UAB, The University of Alabama at Birmingham School of Medicine, VH 390B, 1670 University Boulevard, Birmingham, AL 35294, USA; cdowns@uab.edu.

Submitted: March 9, 2017

Accepted: May 25, 2017

Citation: Jasien JV, Huisingsh C, Girkin CA, Downs JC. The magnitude of hypotony and time course of intraocular pressure recovery following anterior chamber cannulation in nonhuman primates. *Invest Ophthalmol Vis Sci.* 2017;58:3225-3230. DOI: 10.1167/iovs.17-21833

**PURPOSE.** To determine the magnitude of ocular hypotony and the length of recovery time to 6 and 10 mm Hg IOP following anterior chamber (AC) cannulation.

**METHODS.** Bilateral IOP was recorded 500 times per second via telemetry immediately before, during, and immediately after AC cannulation with a 27-G needle in 10 different sessions at least 2 weeks apart in four male rhesus macaques (nonhuman primates; NHPs) aged 3- to 6-years old. Bilateral IOP was recorded continuously using a proven telemetry system while the NHPs were under general anesthesia during IOP transducer calibration experiments involving manometric control of IOP via AC cannulation, then continuously after the AC needles were removed until IOP recovered to precannulation levels. The change in IOP from baseline to AC cannulation was tested using the signed-rank test. The times necessary for IOP to recover to 6 and 10 mm Hg, respectively, were calculated.

**RESULTS.** Average precannulation IOP was 11.5 mm Hg and significantly decreased to an average of 2.3 mm Hg immediately following AC needle removal ( $P = 0.0156$ ). On average, IOP recovered from 2.3 to 6 and 10 mm Hg in 32.4 and 63.7 minutes, respectively. Recovery times of IOP were not affected by repeated AC cannulations every 2 weeks.

**CONCLUSIONS.** Generally, IOP recovers relatively quickly after repeated AC cannulation, and did not result in extended duration hypotony. It is important to consider hypotony in animal experiments and clinical procedures involving AC cannulation and paracentesis when consideration of IOP or its effects is important.

**Keywords:** hypotony, anterior chamber cannulation, nonhuman primates, intraocular pressure

Anterior chamber (AC) cannulation is a common procedure in both research studies and clinical care. In research studies using animal models of ocular disease, AC cannulation is used for acute IOP control<sup>1-5</sup> during imaging and other procedures, and paracentesis is used to collect aqueous humor samples.<sup>6</sup> Anterior chamber paracentesis is a common clinical treatment to lower IOP acutely in acute angle closure and in central retinal arterial occlusion (CRAO).<sup>7-13</sup>

Frequent episodes of persistent hypotony following AC cannulations or paracentesis procedures could represent a confounding variable in animal studies investigating diseases such as glaucoma wherein IOP is a major risk factor. Hence, we investigated the magnitude of hypotony and time course of recovery to normal IOP levels following AC cannulation in nonhuman primates (NHP) with a continuous telemetry system and assessed changes in IOP recovery time after repeated cannulation.

In human subjects, ocular hypotony has been defined as IOP at or below 5 mm Hg,<sup>14,15</sup> below 6.5 mm Hg,<sup>16</sup> and even less than or equal to 8 mm Hg in previous studies.<sup>17</sup> We defined hypotony for this study as a persistent IOP less than 6 mm Hg, as 6 mm Hg is within range of hypotony threshold used in previous studies, and it is lower than the IOP we typically measure in normal NHPs with telemetry. Most commonly, the causes of ocular hypotony are wound leak, retinal detachment, and insufficient aqueous humor production or an increase in

aqueous outflow facility following glaucoma filtering surgery.<sup>14,16,18</sup> The potential long-term side effects of hypotony include visual impairment, choroidal detachment, and macular and/or optic disc edema.<sup>14,16,19</sup>

Several studies have investigated short-term hypotony following AC cannulation or paracentesis without the ability to measure IOP immediately after needle removal.<sup>20-24</sup> Lu et al.<sup>6</sup> performed AC paracentesis with a 27-G needle as treatment for elevated IOP in angle closure glaucoma patients; they reported IOP measurements obtained with Goldmann Applanation Tonometry (GAT) prior to AC paracentesis, then 15 minutes and 24 hours after AC needle removal. Intraocular pressure was approximately 30 mm Hg lower than baseline measurement at both 15 minutes and 24 hours after AC needle removal, but no hypotony was reported during the study, as the average baseline IOP was 58 mm Hg, and hence post-paracentesis IOP was approximately 28 mm Hg.<sup>6</sup> Several other studies report similar results, also showing the safety and efficacy of AC paracentesis for the treatment of elevated IOP associated with acute angle closure.<sup>7-9</sup> These results don't represent normal ocular behavior or hypotony recovery times however, as the study patients had closed iridocorneal angles that limited aqueous outflow facility.

Gerometta et al.<sup>23</sup> performed AC cannulation and paracentesis with a 28-G needle and recorded recovery times

following varying aqueous humor volume withdrawals from the AC. Intraocular pressure was measured with a Perkins tonometer in sheep and Tono-Pen in rabbits. In sheep, 60, 120, and 300  $\mu\text{L}$  of aqueous humor was withdrawn in different animals, and they reported recovery times to baseline IOP of 49, 56, and 50 minutes, respectively. Whereas in rabbits, a 13-minute recovery time to baseline IOP levels was reported after 50 and 100  $\mu\text{L}$  of aqueous humor was withdrawn. All these studies were hampered by the lack of a reliable IOP measurement technique at low IOPs,<sup>25-31</sup> as well as intermittent snapshot IOP measurements that fail to capture the time course of recovery from hypotony. Studies of AC paracentesis to acutely lower IOP in CRAO report visual acuity as the outcome variable, but do not address hypotony or IOP.<sup>10-13</sup> Hence, there are no accurate data on either the true magnitude or duration of hypotony following AC cannulation. Furthermore, there are no studies characterizing the ability of the eye to recover from cannulation-induced hypotony after repeated AC cannulations.

Previous studies have reported intermittent IOP measurements recorded with tonometers that have 1 to 3 mm Hg inherent measurement error, to characterize IOP no sooner than 15 minutes post cannulation. We have collected true baseline IOP, and continuous IOP measurements immediately following 27-G needle AC cannulation using a telemetry system with an accuracy of  $\pm 0.2$  mm Hg. This approach allows characterization of the true level of post cannulation hypotony and the precise recovery times to IOPs of 6 and 10 mm Hg in four NHPs across 10 sessions per animal. We also assessed recovery times from hypotony over time, between sessions that is important in studies that use repeated AC cannulation over long study periods.

## METHODS

### Animals

All animals were treated in accordance with the ARVO Statement for the Use of Animals in Ophthalmic and Vision Research under a protocol approved and monitored by the Institutional Animal Care and Use Committee of the University of Alabama at Birmingham. Seven eyes from four male rhesus macaques, aged 3- to 6-years old, with no ocular abnormalities were used for data collection for this study, which was conducted as standard procedure within a larger National Institutes of Health (NIH)-funded study aimed at determining the contribution of IOP fluctuations to glaucoma onset and progression. All animals were kept on a 6 AM to 6 PM light-dark cycle and fed at approximately 6 AM and 2 PM daily. All animals received water through a continuous feed that was available at all times. Food and water intake was not measured for this study. Ketamine (3 mg/kg) with dexmedetomidine (50 mcg/kg) was used as the induction anesthetic for all experiments, followed by isoflurane inhalant anesthesia (1%-3%) for maintenance during AC cannulation. All NHPs were kept warm with a warming blanket and systemically monitored for heart rate, SpO<sub>2</sub>, end tidal CO<sub>2</sub> volume, electrocardiogram (EKG), and temperature with documentation every 15 minutes during all procedures. All eyes were prepped with 5% betadine solution applied to the eye and lids, followed by a double rinse with sterile balanced salt solution prior to AC cannulation. Three drops of 2% proparacaine topical anesthetic were then instilled to minimize discomfort. Polymixin B antibiotic ointment was applied to all eyes following needle removal. There were no signs of either discomfort (observation of NHP behavior) or persistent ocular inflammation (follow-up slit-

TABLE. Mean IOP and Recovery Times to 6 and 10 mm Hg in Seven Eyes of Four NHPs, Across 10 Sessions Each ( $n = 70$ )

Parameter	Mean	SD	Minimum	Maximum
IOP at baseline, mm Hg	11.5	1.3	9.7	13.2
IOP after AC needle removal, mm Hg	2.3	0.4	1.7	3
Magnitude of IOP change, mm Hg	-9.1	1.5	-10.7	-6.7
Time to 6 mm Hg, min	32.4	4	27.2	39.8
Time to 10 mm Hg, min	63.7	15.2	43.7	92.1

lamp exam) following bilateral AC cannulation needle removal, even after 10 sessions.

### Bilateral IOP Telemetry System

We have developed and validated an implantable telemetry system that wirelessly records 500 measurements of IOP per second for up to 2.5 years.<sup>32</sup> The study protocol mandates a minimum 4-week recovery time following surgery. Using an enhanced version of this system, continuous bilateral IOP, bilateral electro-oculogram (EOG), and aortic blood pressure were recorded both before and after AC cannulation with a 27-G needle at the corneolimbus junction in 10 different sessions, 2 weeks apart in each eye of the NHPs. The IOP transducers were calibrated via AC manometry,<sup>32</sup> and all data corrected for signal drift. Bilateral IOP was recorded continuously while the NHPs were awake and behaving preprocedure and data collection, under general anesthesia during IOP transducer calibration experiments, then continuously after AC needles were removed until IOP recovered to baseline levels. The animals were given an anesthesia reversal agent (antisedan) soon after AC needle removal, and hence were not kept anesthetized for the recovery of IOP to 6 and 10 mm Hg. Thus, the impact of anesthesia on IOP recovery was minimized.

Precannulation baseline IOP was calculated by averaging 60 seconds of continuous telemetric IOP data for each eye following anesthetic induction. Postcannulation IOP after removal of needle from the AC was calculated by averaging 30 seconds of continuous telemetric IOP data for each eye. The mean IOP for each time point was used for analysis. The times necessary for IOP to recover from post-cannulation levels to 6 and 10 mm Hg, respectively, were calculated. The data were collected every 2 weeks over a 5-month period for a total of 10 sessions per eye in each NHP.

### Statistical Analysis

Separate linear regression models were used to assess the linear correlation between magnitude of hypotony, and in recovery times to 6 and 10 mm Hg over the 10 sessions. Statistically significant differences were not observed, so data from each eye over 10 sessions were averaged and summarized as means and SD. A Wilcoxon signed-rank test was used to determine if the change in IOP from baseline to post-AC cannulation was significantly different from zero to test the hypothesis that significant hypotony is present after AC cannulation needle removal, with statistical significance defined as  $P$  less than 0.05.

## RESULTS

The Table shows the baseline IOP, IOP immediately following AC needle removal, the magnitude of IOP change from baseline to AC needle removal, and the time for IOP to recover to 6 and

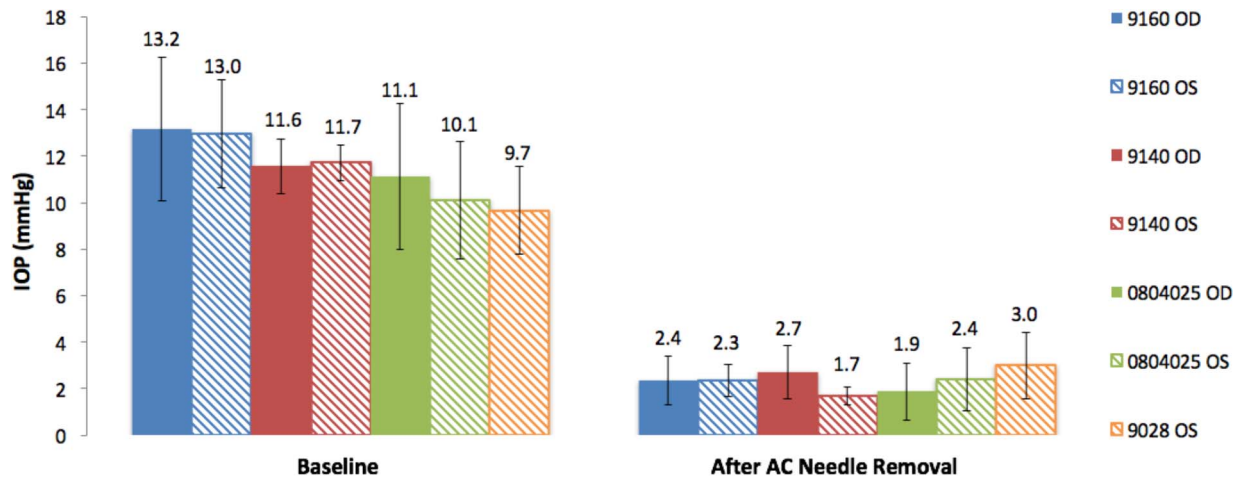


FIGURE 1. Mean IOP (mm Hg) and SD by eye and NHP at baseline and immediately following AC needle removal. OD, right eye; OS, left eye.

10 mm Hg after AC needle removal in seven eyes of four NHPs. The magnitude of IOP change significantly decreased from baseline to immediately following AC needle removal ( $P = 0.0156$ ). Figure 1 shows the mean IOP at baseline and immediately after AC needle removal in each eye. As shown, the IOP at baseline and after AC needle removal was similar for all eyes, ranging from 9.7 to 13.2 mm Hg at baseline, and 1.7 to 3 mm Hg after AC needle removal. There was no significant change in IOP between sessions within eyes ( $P = 0.58$ ). Figure 2 shows the mean recovery time by NHP to 6 and 10 mm Hg. The mean recovery time to 6 mm Hg was 32.4 minutes (SD 4.0), ranging from 27 to 40 minutes. The mean recovery time to 10 mm Hg was 63.7 minutes (SD 15.2), ranging from 44 to 92 minutes.

Over the course of 10 AC cannulations carried out every 2 weeks for 5 months in all eyes, the magnitude of hypotony ( $P = 0.58$ ), the time course of recovery to 6 mm Hg ( $P = 0.15$ ), and the time course of recovery to 10 mm Hg ( $P = 0.68$ ) were not significantly different with each session (Figs. 3A-C). Figure 3A shows the IOP immediately following AC needle removal by eye in each NHP by session.

and 10-mm Hg bilaterally in each NHP after AC cannulation, except for one NHP due to unilateral telemetry. Results show that there is significant hypotony immediately following AC cannulation with a 27-G needle, but IOP recovers to physiologic levels (above 6 mm Hg) within approximately 30 minutes after needle removal.

Previous animal studies did not record postoperative or post-procedure IOP measurements until at least 15 minutes after AC needle removal, which was not quick enough to record the hypotonous period measured in our study. In studies of AC cannulation and paracentesis in sheep and rabbits, IOP recovery was not assessed using accurate continuous measurement; although IOP recovered within an hour.<sup>25</sup> These recovery times are somewhat similar in duration to our measurements.

Carnahan et al.<sup>7</sup> performed AC paracentesis in series in five cases of acute elevation of IOP reporting the safety of repeated AC paracentesis with low risk to the patients. Our study demonstrates that IOP recovers quickly to physiologic levels after AC cannulation. In addition, IOP recovery time following AC cannulation every 2 weeks remained consistent over a 5-month period. Hence, repeated AC cannulations do not result in persistent corneal wound leaks or persistent hypotony over long study periods. These data also inform clinical care, as previous studies showed no hypotony 1 day after procedures using a 27-G needle. Given the similarities between human and

## DISCUSSION

We used continuous IOP telemetry to measure both the level of hypotony and the precise time needed for IOP to recover to 6-

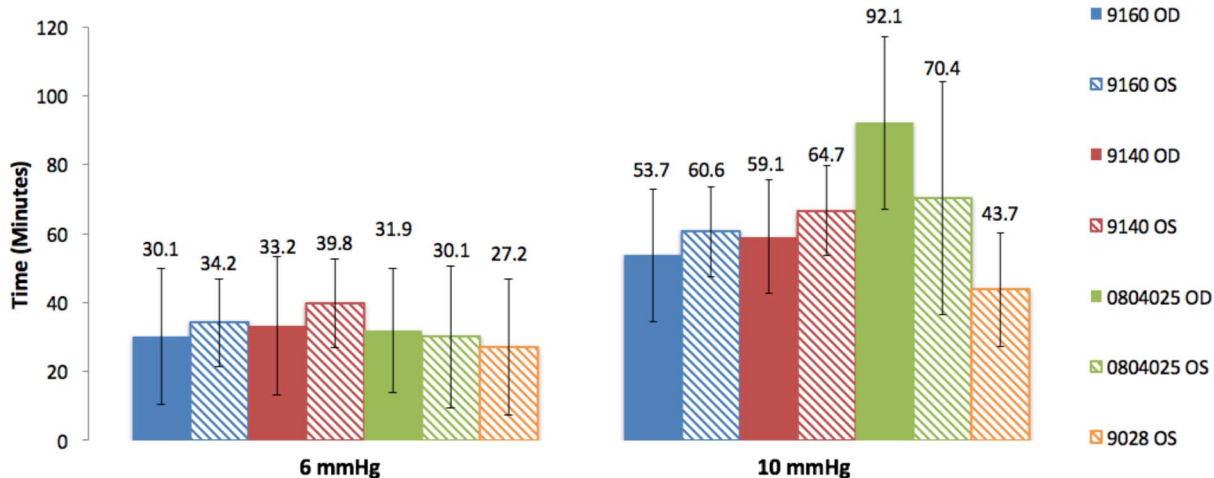


FIGURE 2. Mean recovery time and SD (minutes) to 6 and 10 mm Hg IOP after AC needle removal by eye and NHP. OD, right eye; OS, left eye.

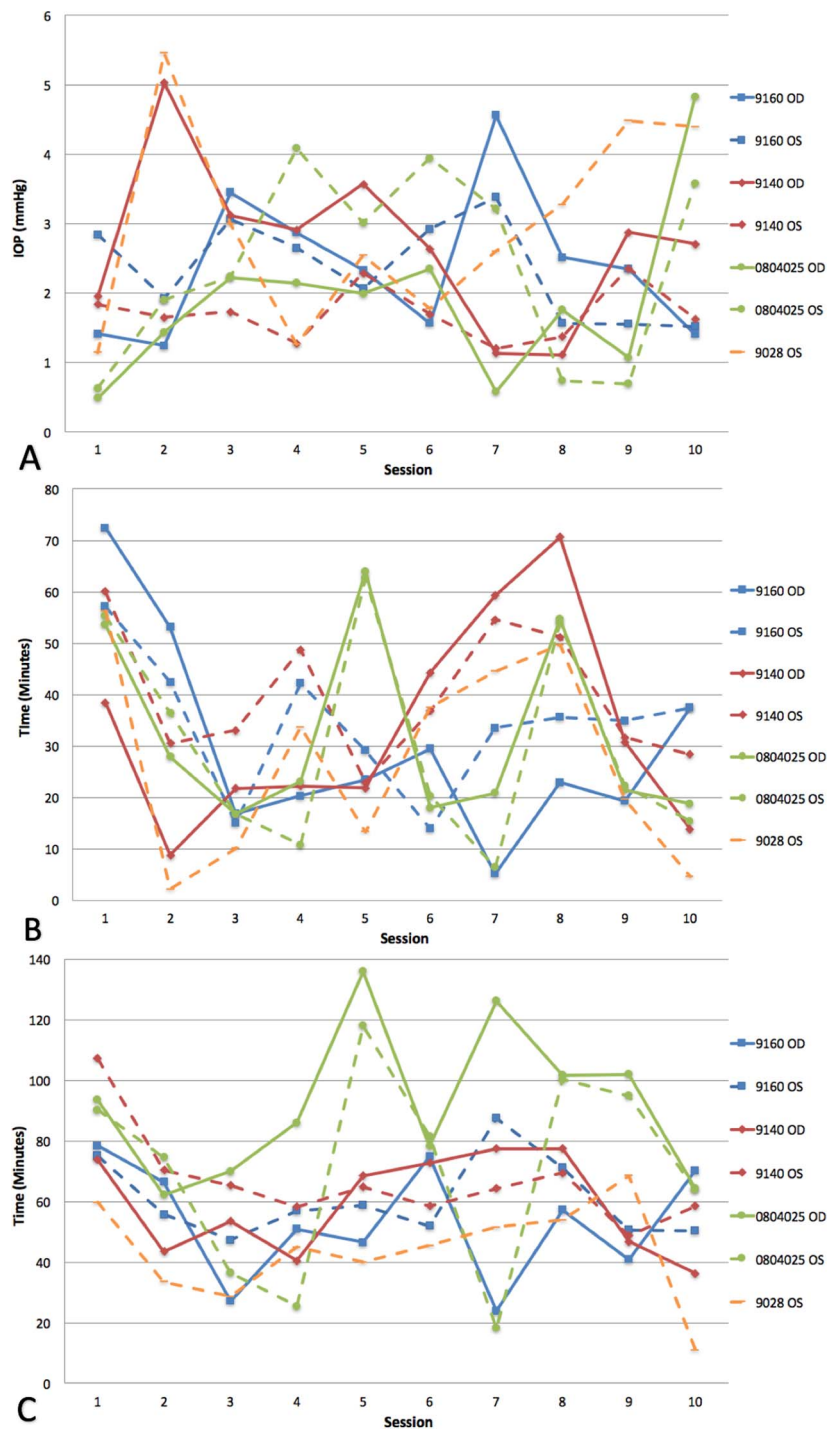


FIGURE 3. (A) Intraocular pressure immediately following AC needle removal by eye in each NHP by session. (B) Recovery time to 6 mm Hg after AC needle removal by eye in each NHP by session; (C) recovery time to 10 mm Hg after AC needle removal by eye in each NHP by session. OD, right eye; OS, left eye.

NHP eyes, postoperative hypotony is likely to occur in these patients, but is likely of short duration.

The present study limited by the following considerations. While the telemetric IOP measurements reported herein are accurate to within  $\pm 0.2$  mm Hg<sup>32</sup> and allow for continuous IOP monitoring over long periods, the NHPs were anesthetized during both the AC cannulation procedure and the follow-up period in which we assessed IOP recovery. Anesthesia could affect aqueous production and/or outflow rates, which may

affect the rate of ocular volume recovery, and hence the magnitude and duration of hypotony. There are some differences in aqueous humor dynamics in humans and NHPs, so this result may not be directly translatable to clinical applications.<sup>33-36</sup> Also, IOP fluctuates significantly with blinks and saccades,<sup>33,37</sup> and it is possible that these IOP transients could prolong AC cannulation wound leakage, and therefore prolong the period of hypotony associated with these procedures in awake behaving NHPs. For the purposes of this

study, the results and conclusions remain valid for NHPs, and may translate to humans.

Anterior chamber cannulation is common in animal studies and human patient procedures, but its lasting effects on IOP are unknown. Results show that the IOP falls to very low levels after AC needle removal; the eye is only hypotonous for approximately 30 minutes after needle removal, and recovers to near baseline levels within approximately 65 minutes. Most importantly, repeated AC cannulations have no effect on either the magnitude of hypotony or the recovery time to either 6 or 10 mm Hg, which is very important for studies involving repeat AC cannulations. This should be taken into account in research or clinical settings when consideration of IOP or its effects is important, but results show that IOP recovers quickly in NHPs even after repeated AC cannulation procedures in the same eye.

### Acknowledgments

The authors thank Lisa Hethcox, LVT, for her invaluable help in the both the care of the NHPs and data acquisition, and Chester Calvert for his invaluable assistance in data procurement and processing.

Supported by National Institutes of Health Grants R01 EY024732 and P30 EY003039 (Bethesda, MD, USA); EyeSight Foundation of Alabama (Birmingham, AL, USA); and Research to Prevent Blindness (New York, NY, USA).

Disclosure: **J.V. Jasien**, None; **C. Huisin**, None; **C.A. Girkin**, None; **J.C. Downs**, None

### References

- Burgoyne CF. The non-human primate experimental glaucoma model. *Exp Eye Res.* 2015;141:57-73.
- Gabelt BT, Gottanka J, Lütjen-Drecoll E, Kaufman PL. Aqueous humor dynamics and trabecular meshwork and anterior ciliary muscle morphologic changes with age in rhesus monkeys. *Invest Ophthalmol Vis Sci.* 2003;44:2118-2125.
- Quigley HA, Addicks EM. Chronic experimental glaucoma in primates. *Methods.* 1980:126-136.
- Rasmussen CA, Kaufman PL. Primate glaucoma models. *J Glaucoma.* 2005;14:311-314.
- Harwerth RS, Smith EL III, DeSantis L. Experimental glaucoma: perimetric field defects and intraocular pressure. *J Glaucoma.* 1997;6:390-401.
- Lu D-W, Tai M-C, Chang YH, et al. Anterior chamber paracentesis and pH values in patients with acute primary angle closure. *Graefes Arch Clin Exp Ophthalmol.* 2013;251:1229-1234.
- Carnahan MC, Platt LW. Serial paracenteses in the management of acute elevations of intraocular pressure. *Ophthalmology.* 2002;109:1604-1606.
- Arnavielle S, Creuzot-Garcher C, Bron AM. Anterior chamber paracentesis in patients with acute elevation of intraocular pressure. *Graefes Arch Clin Exp Ophthalmol.* 2007;245:345-350.
- Lam DSC, Chua JKH, Tham CCY, Lai JSM. Efficacy and safety of immediate anterior chamber paracentesis in the treatment of acute primary angle-closure glaucoma: a pilot study. *Ophthalmology.* 2002;109:64-70.
- Cugati S, Varma DD, Chen CS, Lee AW. Treatment options for central retinal artery occlusion. *Curr Treat Options Neurol.* 2013;15:63-77.
- Atebara NH, Brown GC, Cater J. Efficacy of anterior chamber paracentesis and Carbogen in treating acute nonarteritic central retinal artery occlusion. *Ophthalmology.* 1995;102:2025-2029.
- Fiess A, Cal O, Kehrein S, Halstenberg S, Frisch I, Steinhilber UH. Anterior chamber paracentesis after central retinal artery occlusion: a tenable therapy? *BMC Ophthalmol.* 2014;14:28.
- Flytche TJ. A rationalization of treatment of central retinal artery occlusion. *Trans Ophthalmol Soc U K.* 1974;94:468-479.
- Johnstone MA. Hypotony: what is it? How should we manage it? *J Glaucoma.* 2000;9:131-133.
- Fine HF, Biscette O, Chang S, Schiff WM. Ocular hypotony: a review. *Compr Ophthalmol Update.* 2007;8:29-37.
- Pederson JE. Ocular hypotony. In: Ritch R, Shields B, Krupin T, eds. *The Glaucomas, Volume 1.* 2nd ed. Mosby; 1996:385-395.
- Migdal C, Hitchings R. Morbidity following prolonged postoperative hypotony after trabeculectomy. *Ophthalmic Surg.* 1988;19:865-867.
- Pederson JE. Ocular hypotony. *Trans Ophthalmol Soc U K.* 1986;105(pt 2):220-226.
- Dellaporta A. Fundus changes in postoperative hypotony. *Am J Ophthalmol.* 1955;40:781-785.
- Tian B, Gabelt AT, Crosson CE, Kaufman PL. Effects of adenosine agonists on intraocular pressure and aqueous humor dynamics in cynomolgus monkeys. *Exp Eye Res.* 1997;64:979-989.
- Gabelt BT, Okka M, Dean TR, Kaufman PL. Aqueous humor dynamics in monkeys after topical R-DOI. *Invest Ophthalmol Vis Sci.* 2005;46:4691-4696.
- Charng J, Nguyen CTO, Vingrys AJ, Jobling AI, Bui BV. Increased susceptibility to injury in older eyes. *Optom Vis Sci.* 2013;90:275-281.
- Gerometta R, Alvarez IJ, Candia OA. Sildenafil accelerates anterior chamber refilling after paracentesis in sheep and rabbits. *Invest Ophthalmol Vis Sci.* 2012;53:565-575.
- Avila MY, Múnera A, Guzmán A, et al. Noninvasive intraocular pressure measurements in mice by pneumotonometer. *Invest Ophthalmol Vis Sci.* 2005;46:3274-3280.
- Peterson JA, Kiland JA, Croft MA, Kaufman PL. Intraocular pressure measurement in cynomolgus monkeys. Tono-Pen versus manometry. *Invest Ophthalmol Vis Sci.* 1996;37:1197-1199.
- Ehlers N, Bramsen T, Sperling S. Applanation tonometry and central corneal thickness. *Acta Ophthalmol.* 1975;53:34-43.
- Johnson M, Kass MA, Moses RA, Grodzki WJ. Increased corneal thickness simulating elevated intraocular pressure. *Arch Ophthalmol.* 1978;96:664-665.
- Kao SF, Lichter PR, Bergstrom TJ, Rowe S, Musch DC. Clinical comparison of the Oculab Tono-Pen to the Goldmann applanation tonometer. *Ophthalmology.* 1987;94:1541-1544.
- Farrar SM, Miller KN, Shields MB, Stoup CM. An evaluation of the Tono-Pen for the measurement of diurnal intraocular pressure. *Am J Ophthalmol.* 1989;107:411-416.
- Mendelsohn AD, Forster RK, Mendelsohn SL, et al. Comparative tonometric measurements of eye bank eyes. *Cornea.* 1987;6:219-225.
- Whitacre MM, Stein R. Sources of error with use of Goldmann-type tonometers. *Surv Ophthalmol.* 1993;38:1-30.
- Downs JC, Burgoyne CF, Seigfried WP, Reynaud JF, Strouthidis NG, Sallee V. 24-hour IOP telemetry in the nonhuman primate: implant system performance and initial characterization of IOP at multiple timescales. *Invest Ophthalmol Vis Sci.* 2011;52:7365-7375.
- Gaasterland D, Kupfer C. Experimental glaucoma in the rhesus monkey. *Invest Ophthalmol.* 1974;13:455-457.

34. Gaasterland D, Kupfer C, Milton R, Ross K, McCain L, MacLellan H. Studies of aqueous humour dynamics in man. VI. Effect of age upon parameters of intraocular pressure in normal human eyes. *Exp Eye Res.* 1978;26:651-656.
35. Toris CB, Zhan GL, Wang YL, et al. Aqueous humor dynamics in monkeys with laser-induced glaucoma. *J Ocul Pharmacol Ther.* 2000;16:19-27.
36. Toris CB, Yablonski ME, Wang YL, Camras CB. Aqueous humor dynamics in the aging human eye. *Am J Ophthalmol.* 1999;127:407-412.
37. Coleman DJ, Trokel S. Direct-recorded intraocular pressure variations in a human subject. *Arch Ophthalmol.* 1969;82:637-640.